



How to Approach Lines and Tubes on CXR

Pauline Germaine

Cooper University Hospital

Nina Terry

University of Alabama Birmingham

MD Anderson  Cooper
~~Cancer Center~~

Making Cancer History®

UAB MEDICINE

Knowledge that will change your world



How to Approach Lines and Tubes on CXR

Pauline Germaine

Cooper University Hospital

Nina Terry

University of Alabama Birmingham

MD Anderson  Cooper
~~Cancer Center~~

Making Cancer History®

UAB MEDICINE

Knowledge that will change your world

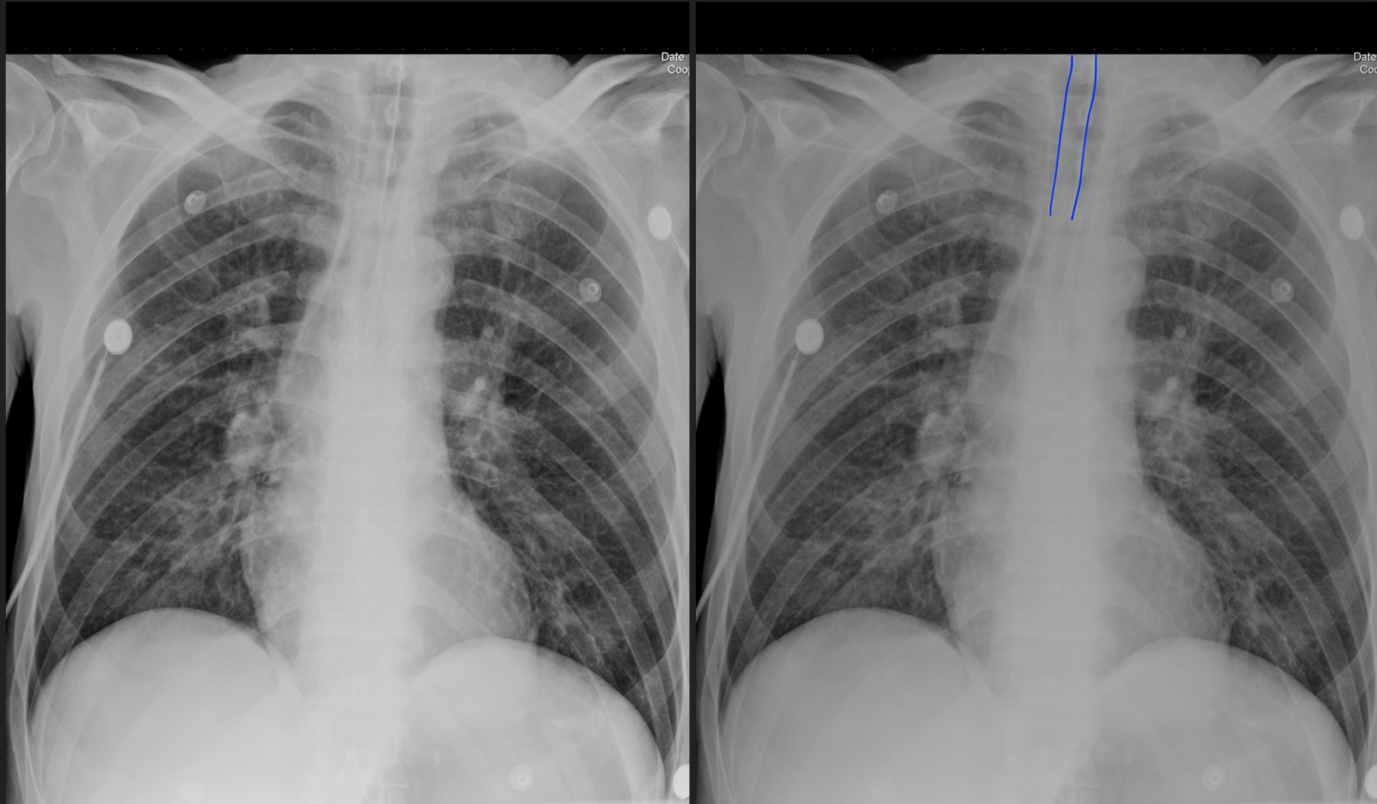
Approach

- Evaluate Lines and Tubes first.
- Identify and assess placement of each line/tube individually.
- Look for expected complications.
- Report all complications present.
- Report absence of common complications. (Ex: Right subclavian line is in appropriate position. No pneumothorax.)
- Report lines/tubes as being in correct or appropriate position,
- NOT as stable.

Endotracheal Tube

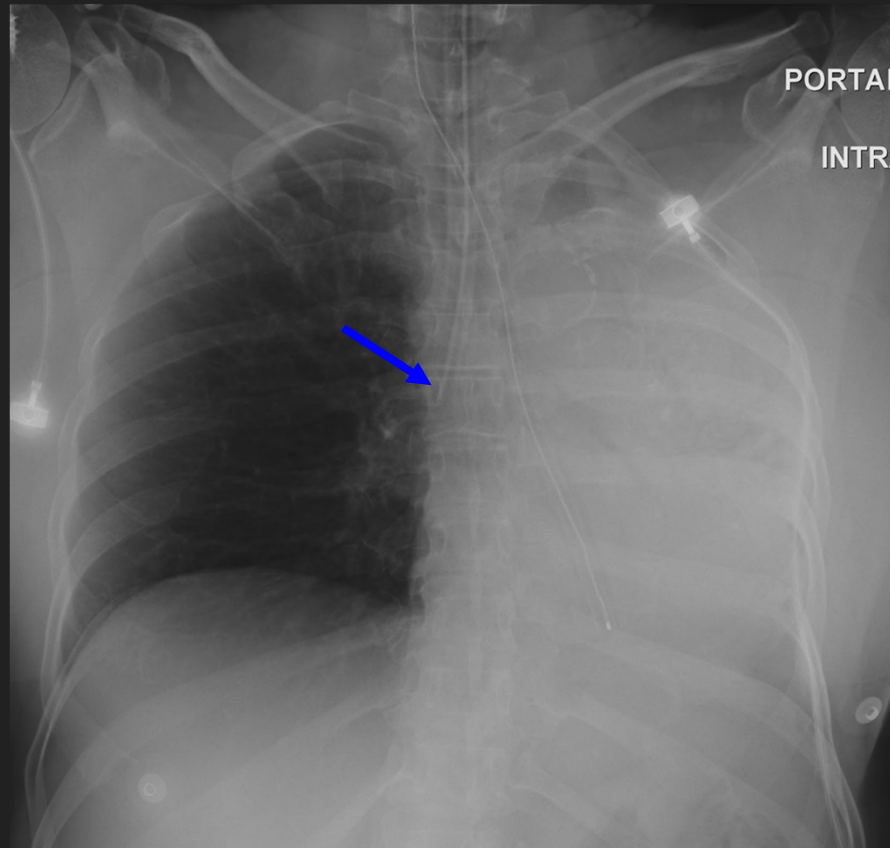
- Purpose:
 - Airway control during assisted ventilation
 - Access for airway suctioning
 - Potential route for medication administration
- Proper placement:
 - Should terminate 2-5cm above the carina, or ½ way between carina and clavicles
 - Balloon of the tube should not be hyperinflated
- Complications:
 - Misplacement in the pharynx or right/left mainstem bronchi
 - Atelectasis
 - Aspiration
 - Pneumothorax
 - Vocal cord injury
 - Tracheal wall injury
 - Esophageal dilatation

Endotracheal Tube: Proper Placement



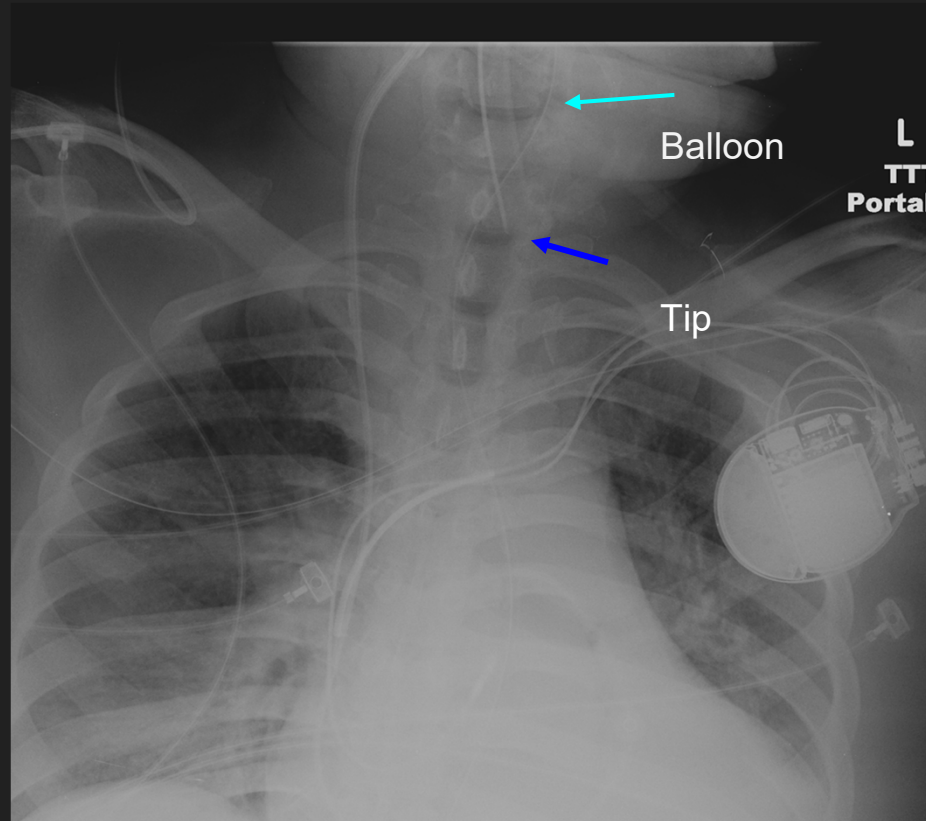
Endotracheal Tube: Misplaced

ET tip in the Right
Mainstem
Bronchus with
complete Left lung
atelectasis



Endotracheal Tube: Misplaced

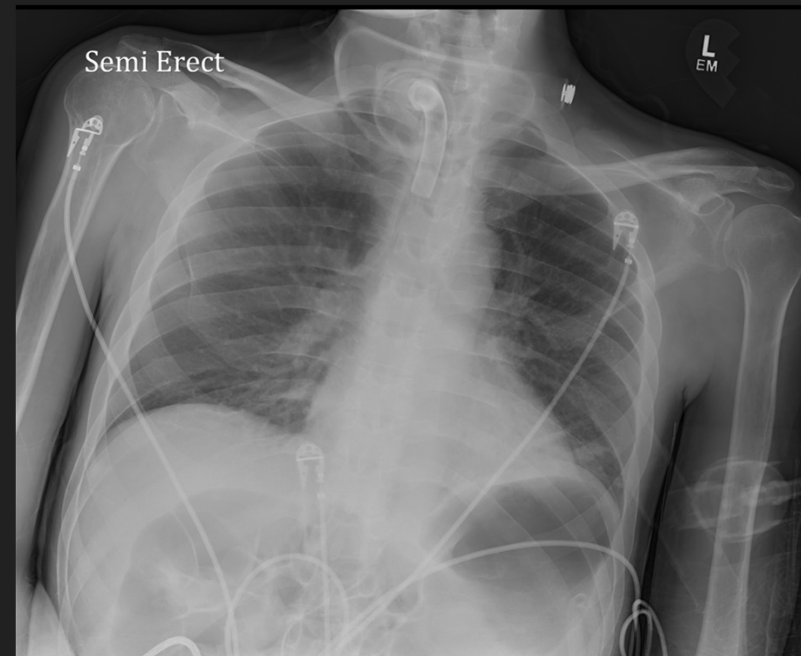
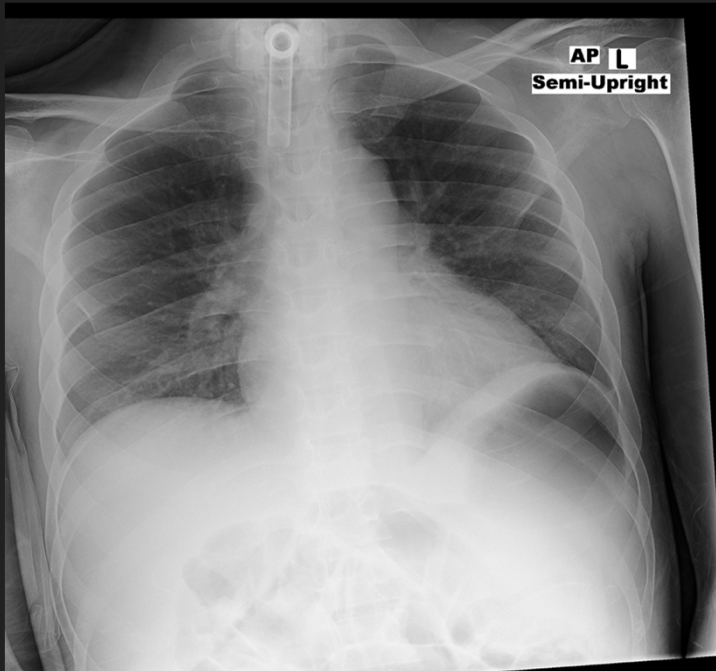
ET Tip and
balloon in
the neck



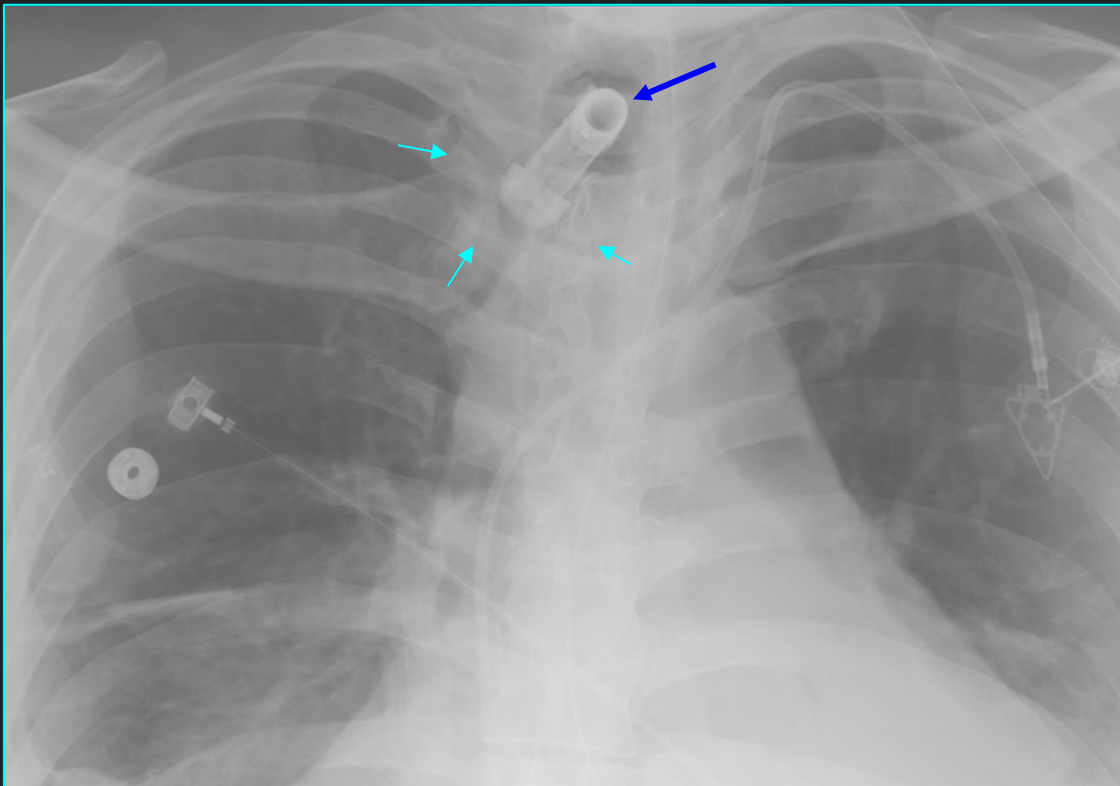
Tracheostomy Tube

- Purpose:
 - Long term airway access in patients with obstruction at or above larynx
- Proper placement:
 - Should terminate $\frac{1}{2}$ way between the stoma and carina (~T3 level)
- Complications:
 - Misplacement in lungs, mediastinum or subcutaneous tissues
 - Perforation of trachea
 - Aspiration
 - Pneumomediastinum or pneumothorax
 - Tracheal wall injury/stenosis

Tracheostomy Tube: Proper Placement



Tracheostomy Tube: Misplaced

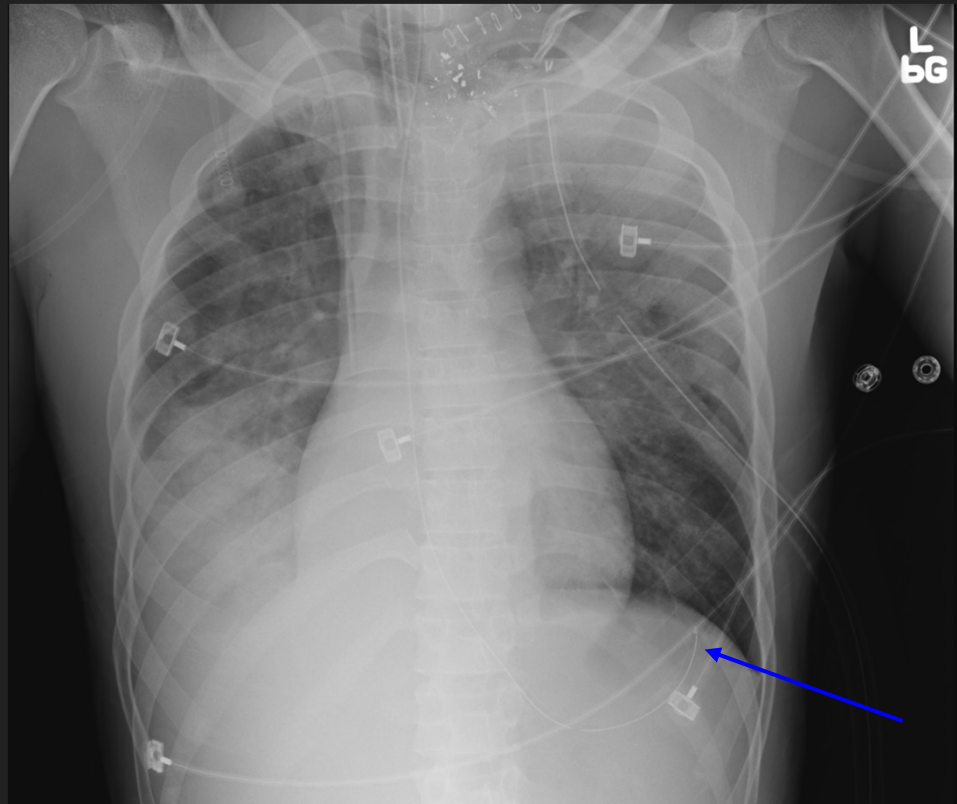


The flange (light blue arrows) marks the outside tip and the blue arrow points to the internal tip which is not curving into the trachea. The tracheostomy tube is almost out.

Nasogastric tube

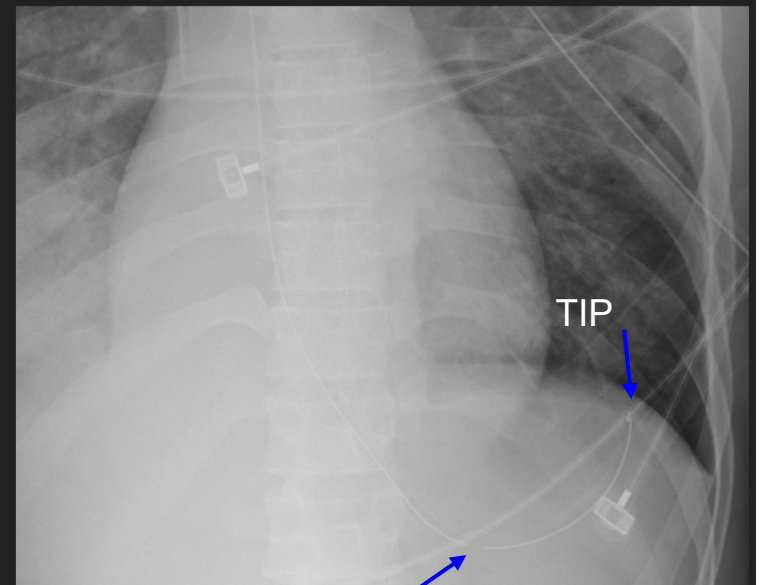
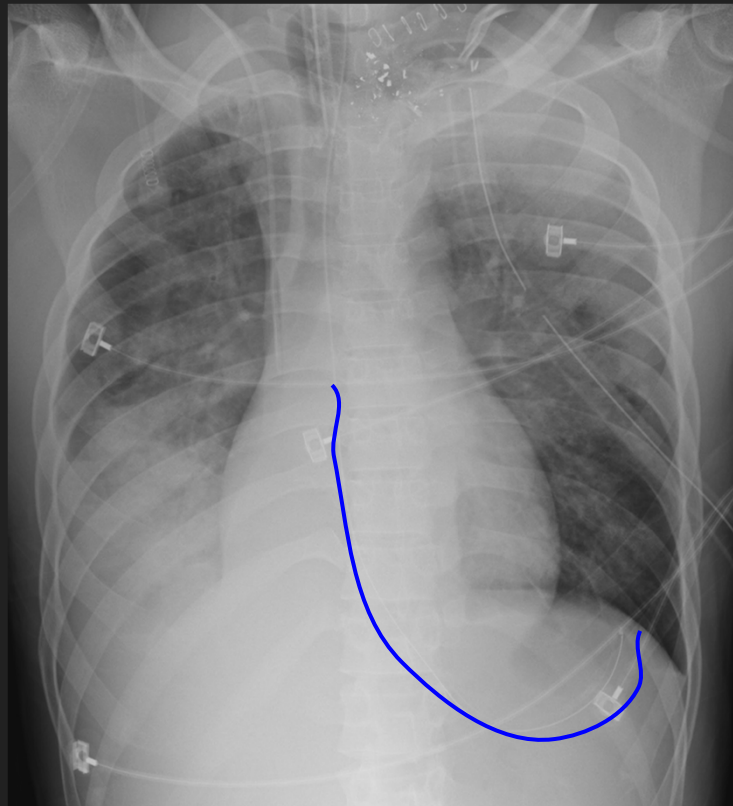
- Purpose
 - Short term feeding
 - Gastric suction & decompression
 - Medication administration
- Proper placement
 - Inserted via the nose, through esophagus into the stomach
 - Tip and side hole should extend into the stomach
- Complications
 - Misplacement in the oropharynx, esophagus or airway
 - Esophagitis, reflux, stricture, esophageal perforation
 - Aspiration
 - Lung injury, pneumothorax or hydropneumothorax

Nasogastric Tube: Proper Placement



Nasogastric Tube: Proper Placement

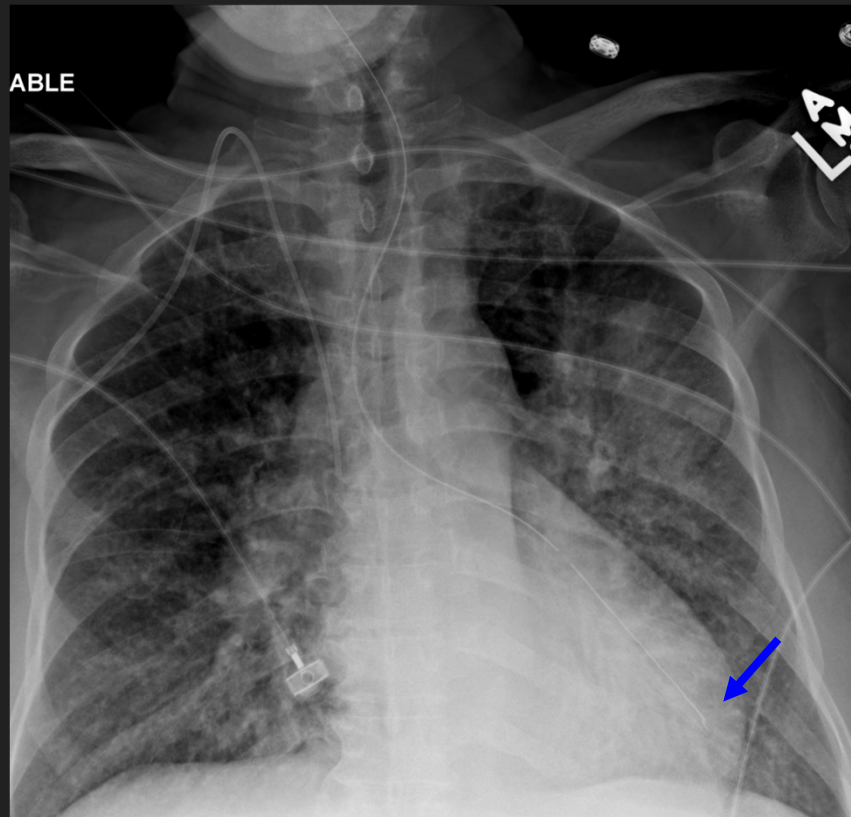
Both the tip and the sidehole are below the left diaphragm.



Sidehole

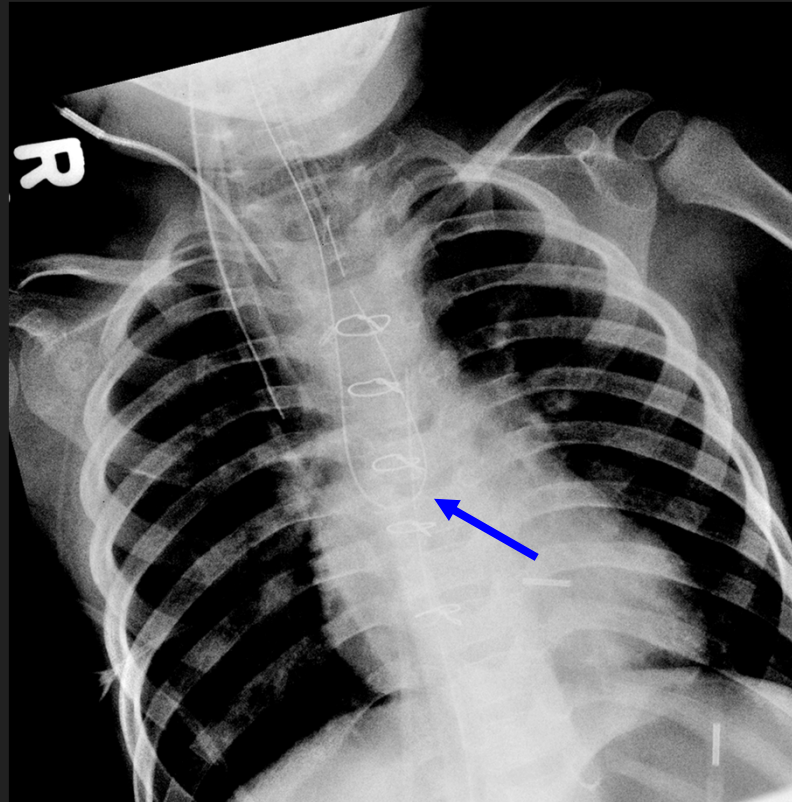
Nasogastric Tube: Misplaced

NG tube
terminates in
the Left Lower
Lobe bronchus



Nasogastric Tube: Misplaced

NG tube is
coiled in
Esophagus
with tip in
throat

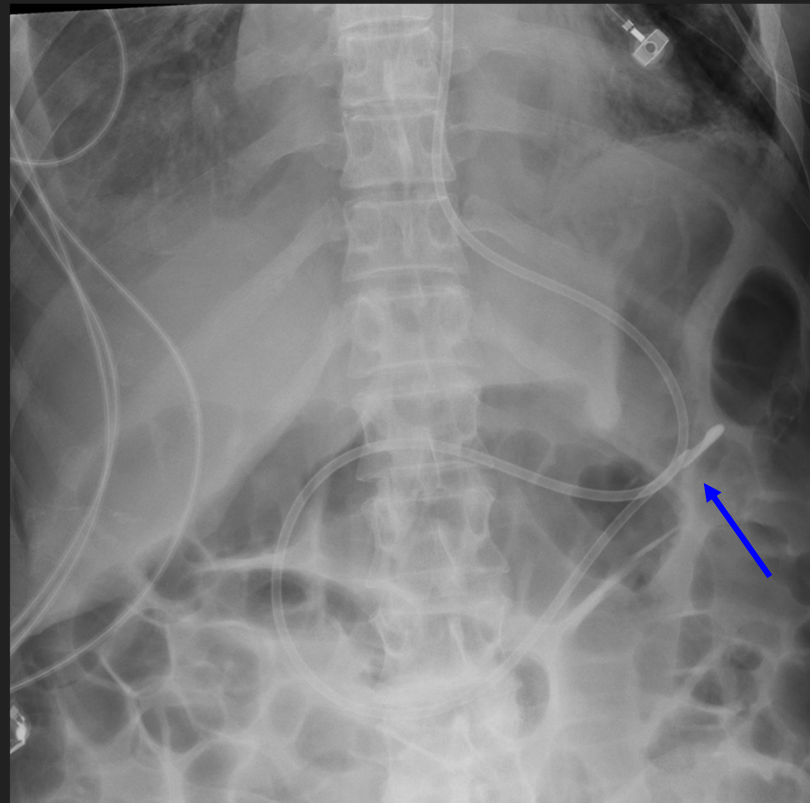
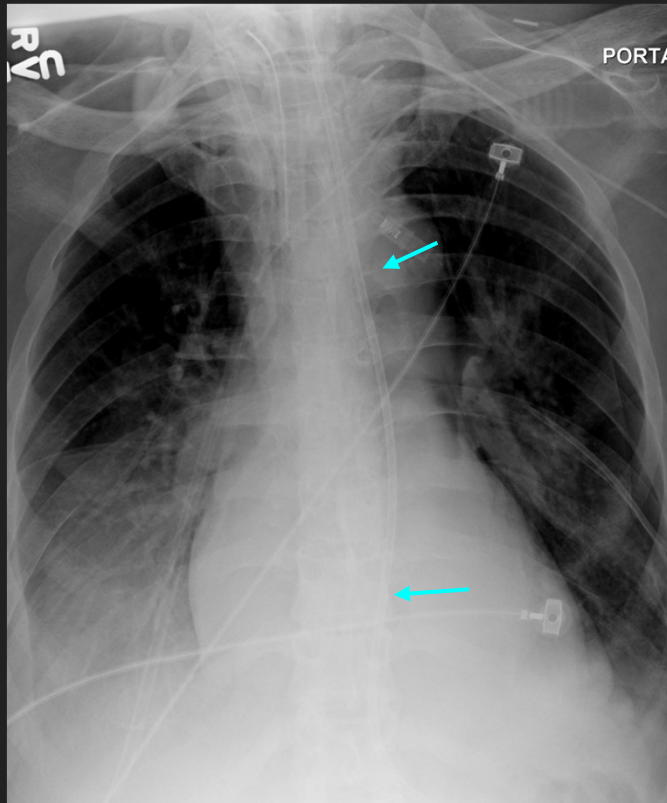


Dobbhoff Tube

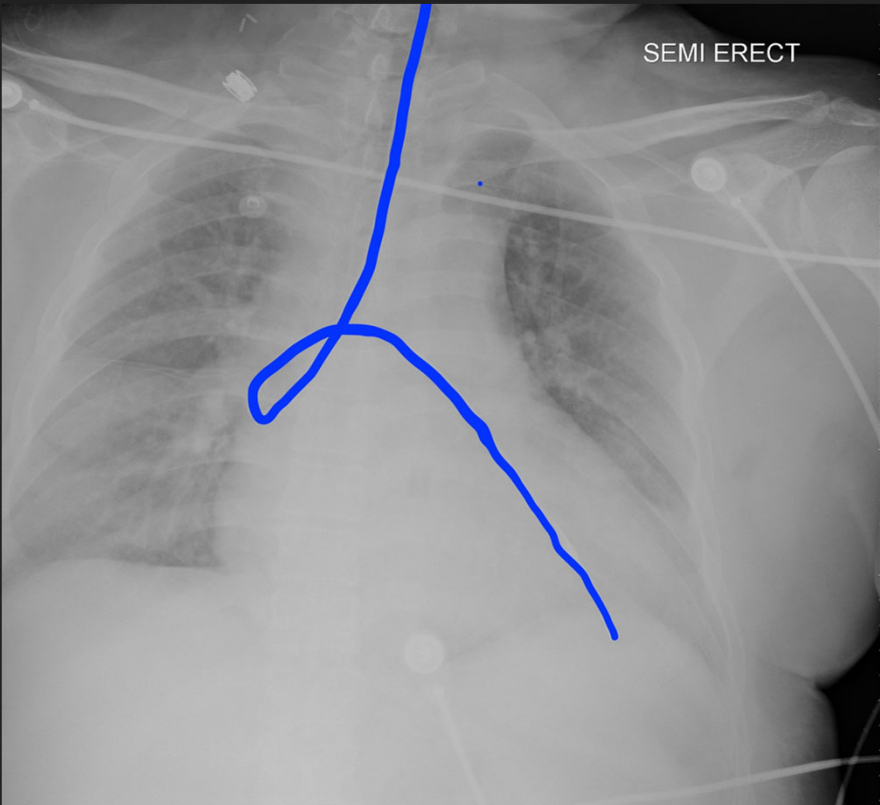
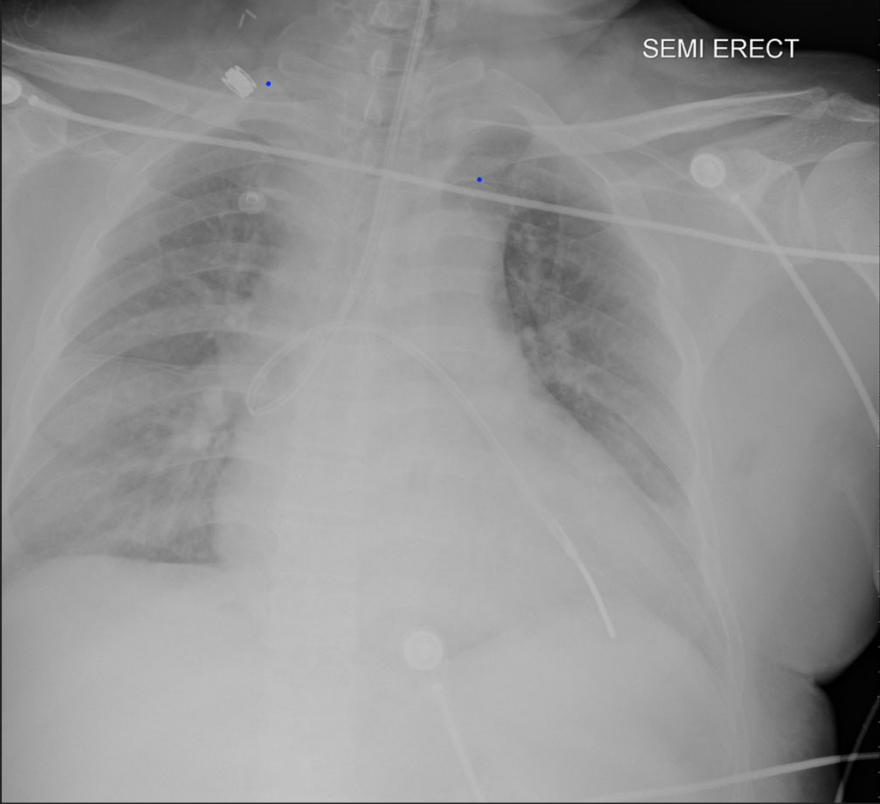
- Purpose
 - Short term feeding
 - Prevent aspiration
- Proper Placement
 - Inserted via the pharynx, through esophagus and stomach into the duodenum
 - Weighted tip should terminate in the proximal duodenum, past the level of the duodenal bulb [Ideally tip should be at the Ligament of Treitz.]
- Complications
 - Misplacement in the oropharynx, esophagus, stomach or airway
 - Esophagitis, reflux, stricture, esophageal perforation

Dobbhoff Tube: Proper Placement

Chest and abdomen exam show DT following the course of esophagus and stomach to the Ligament of Treitz



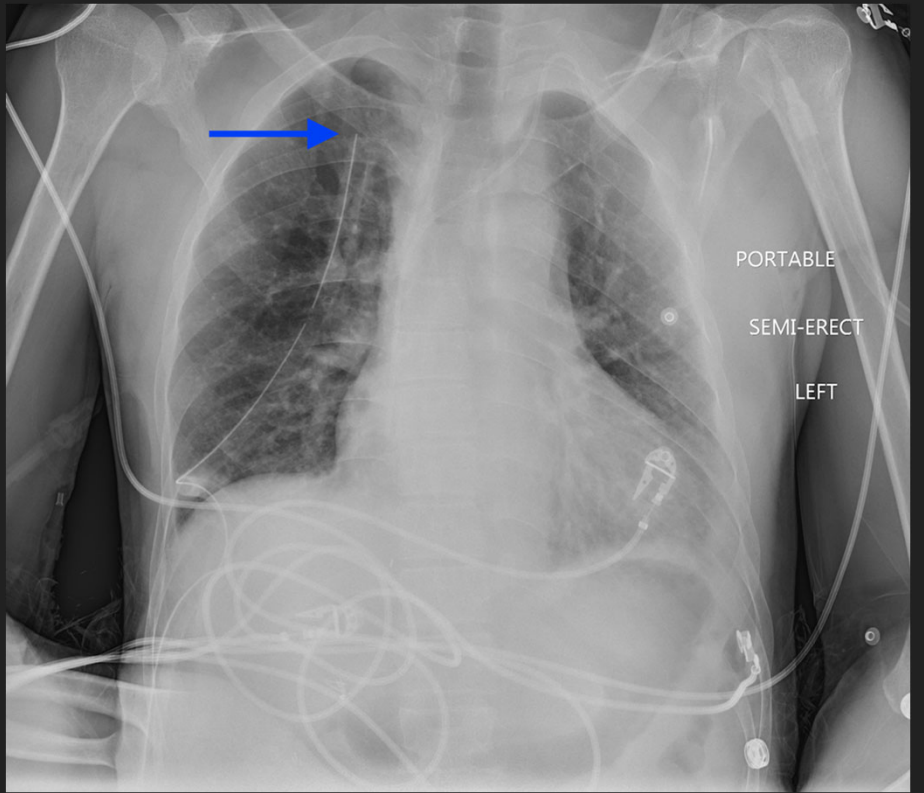
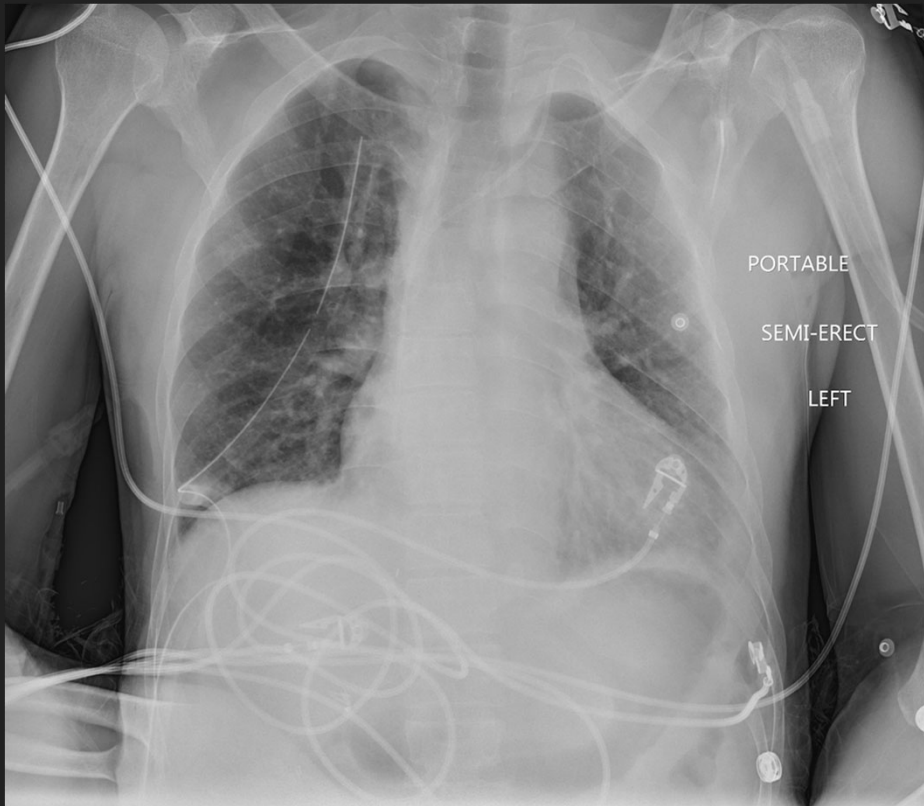Dobbhoff Tube: Misplaced



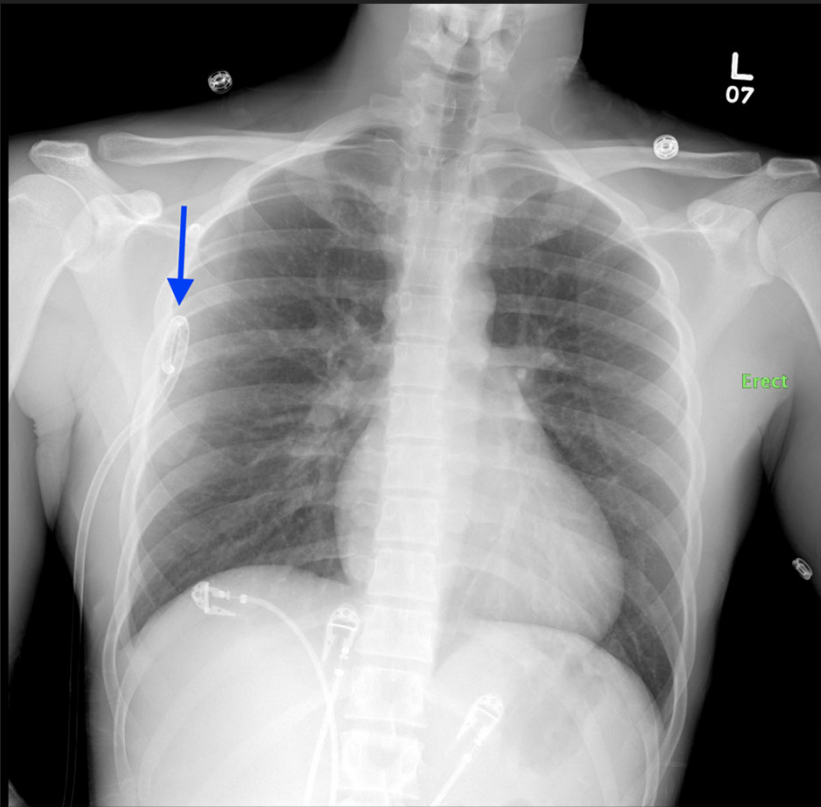
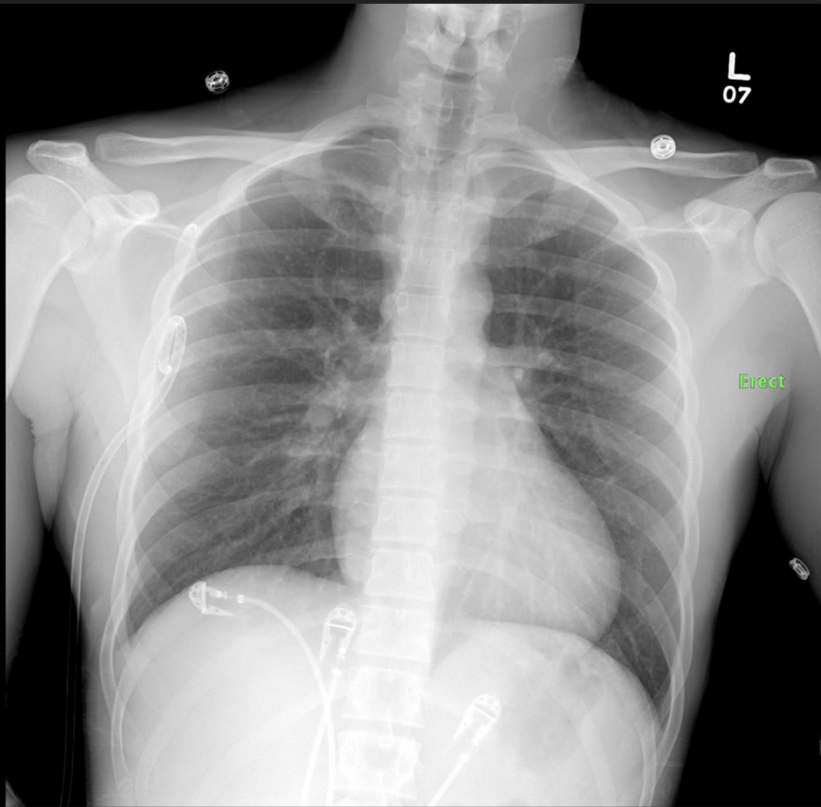
Chest Tube

- Purpose
 - Remove air or fluid from the pleural space
- Proper Placement
 - For air evacuation, tip should point anterosuperior
 - For fluid evacuation, tip should point posteroinferior
 - Side holes should be inside the thorax
- Complications
 - Misplacement in the fissures, parenchyma, mediastinum, or diaphragm
 - Pneumothorax
 - Inadequate drainage
 - Air leak
 - Infection
 - Bleeding from intercostal arteries
 - Injury to diaphragm or upper abdominal organs

Chest Tube: Proper Placement

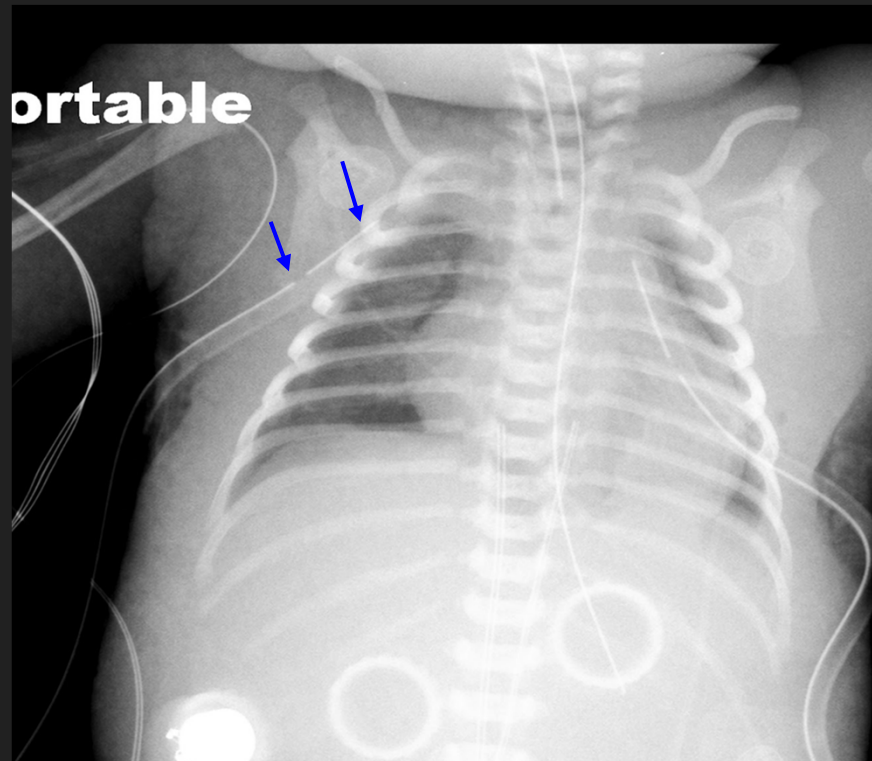


Chest Tube: Proper Placement



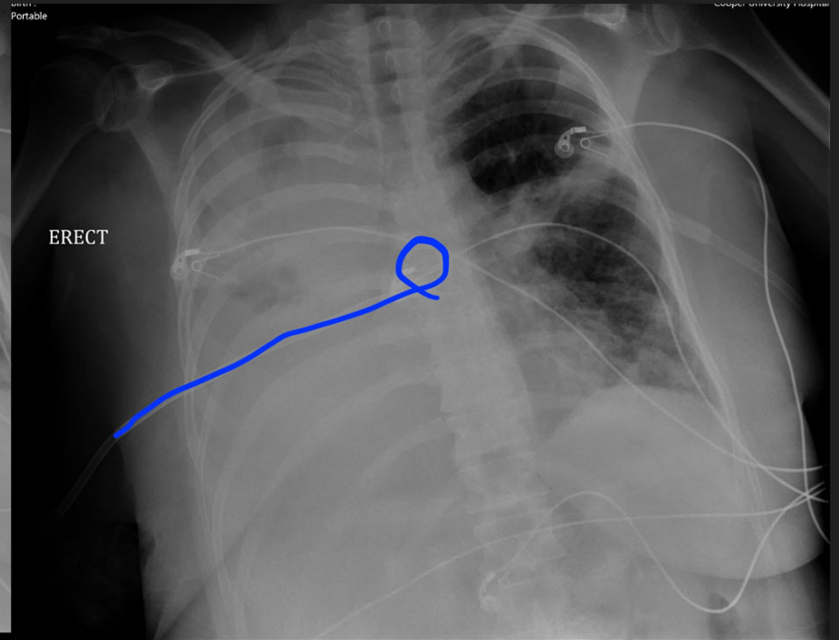
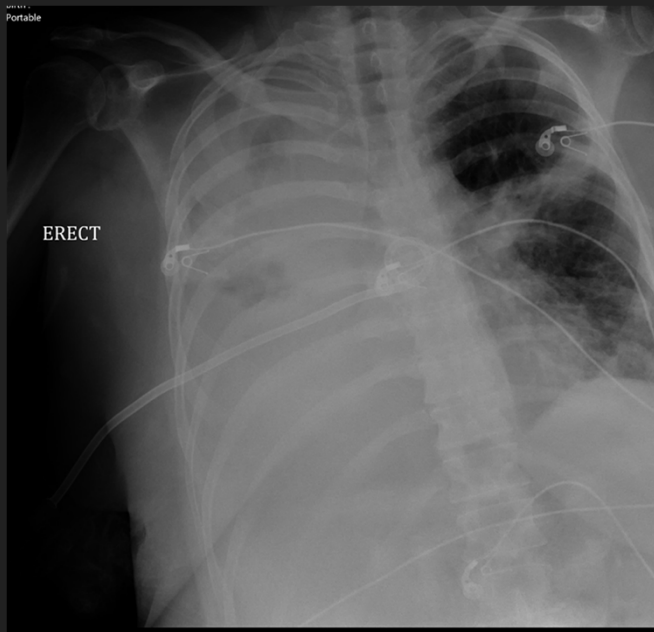
Chest Tube: Misplaced

Right chest
tube in chest
wall



Chest Tube: Misplaced

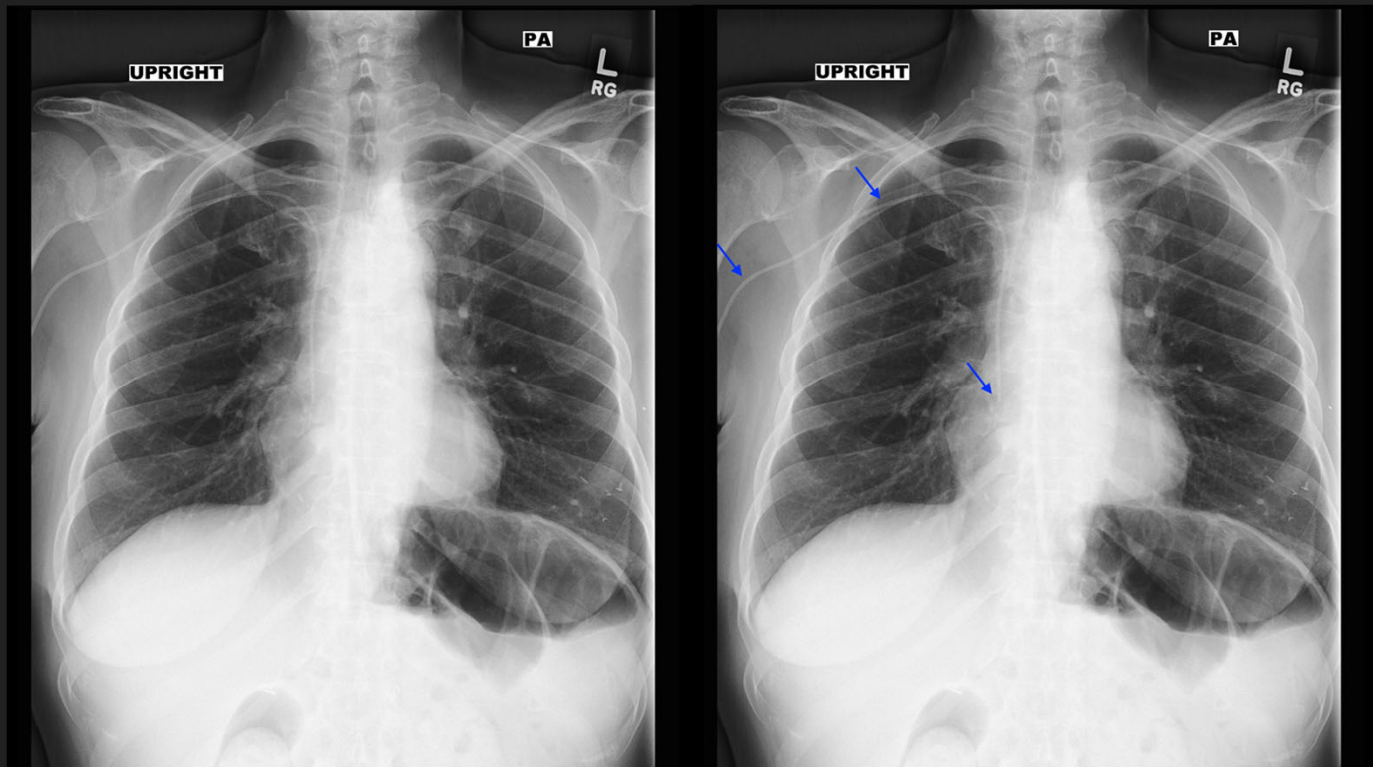
Right chest tube projects over the mediastinum and was coiled in right main pulmonary artery on subsequent CT



Peripherally Inserted Central Catheter

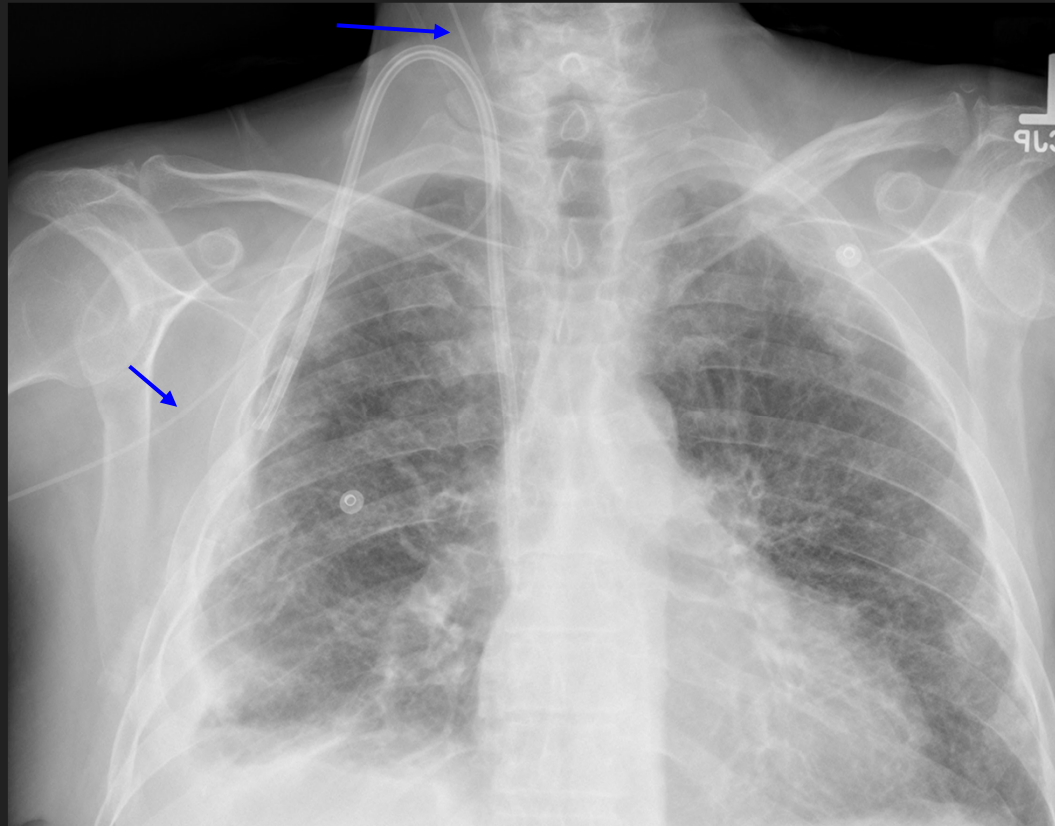
- Purpose
 - Establish long-term venous access
- Proper Placement
 - Inserted via peripheral veins (i.e. basilic vein, brachial vein, cephalic vein or axillary vein) to terminate in the superior vena cava
- Complications
 - Misplacement in right heart chambers
 - Phlebitis, bleeding, thrombosis
 - Venous perforation
 - Pain
 - Sepsis

Peripherally Inserted Central Catheter: Proper Placement



Peripherally Inserted Central Catheter: Misplaced

Right PICC
line going up
the right
jugular vein

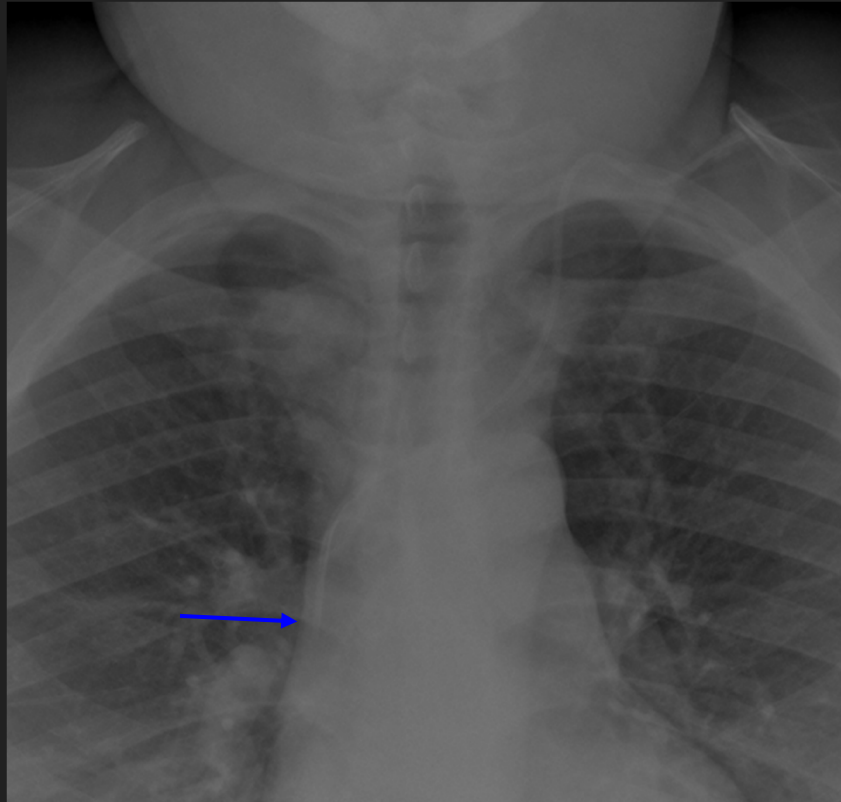


Central Venous Lines (CVL)

- Purpose
 - Central venous access for fluids, medications, IV contrast
- Proper Placement
 - Tip in the SVC-distal to subclavian/jugular junction and proximal to the right atrium
 - Small sleeve of SVC extends into right atrium
- Complications
 - Malposition
 - Pneumothorax
 - Hemothorax
 - Mediastinal hematoma
 - Fracture of the line

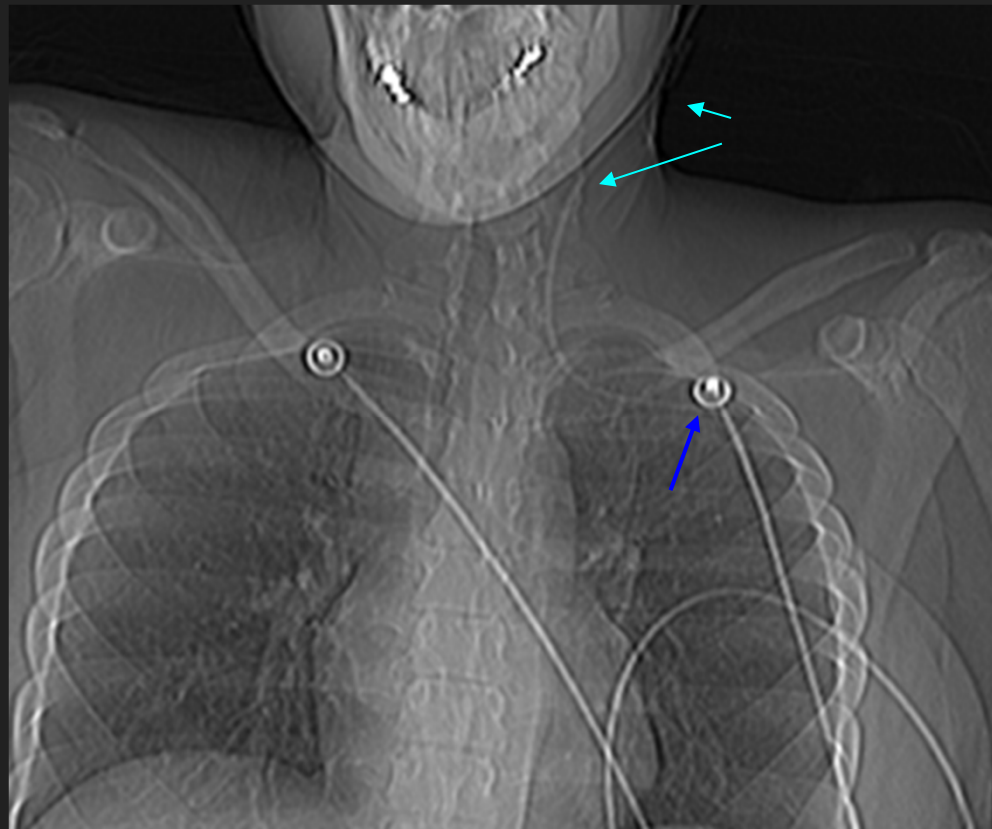
Central Venous Line: Proper Placement

Left Internal
Jugular (IJ)
line with tip in
mid-SVC



Central Venous Line: Misplaced

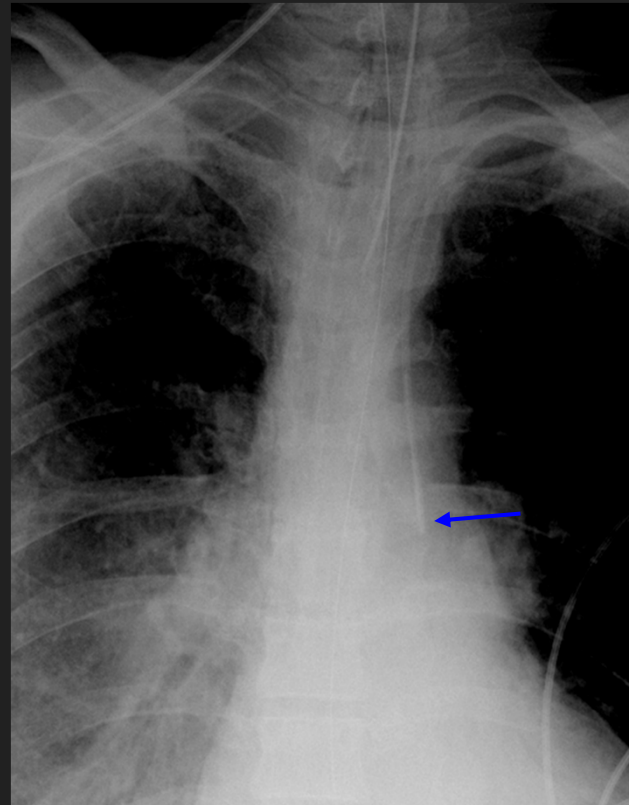
Left IJ (light blue arrow) with tip in Left Subclavian vein (Blue arrow)



Central Venous Line: Misplaced

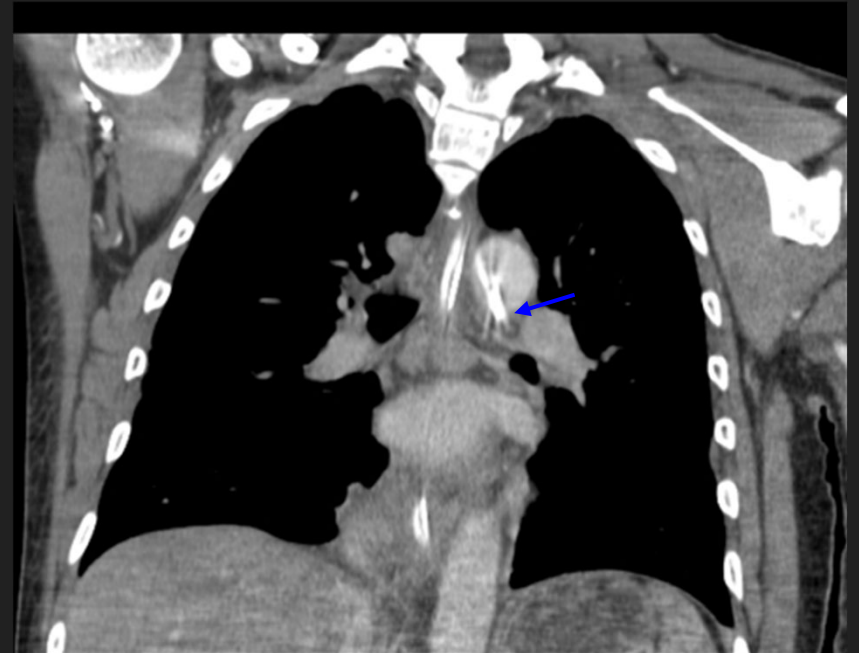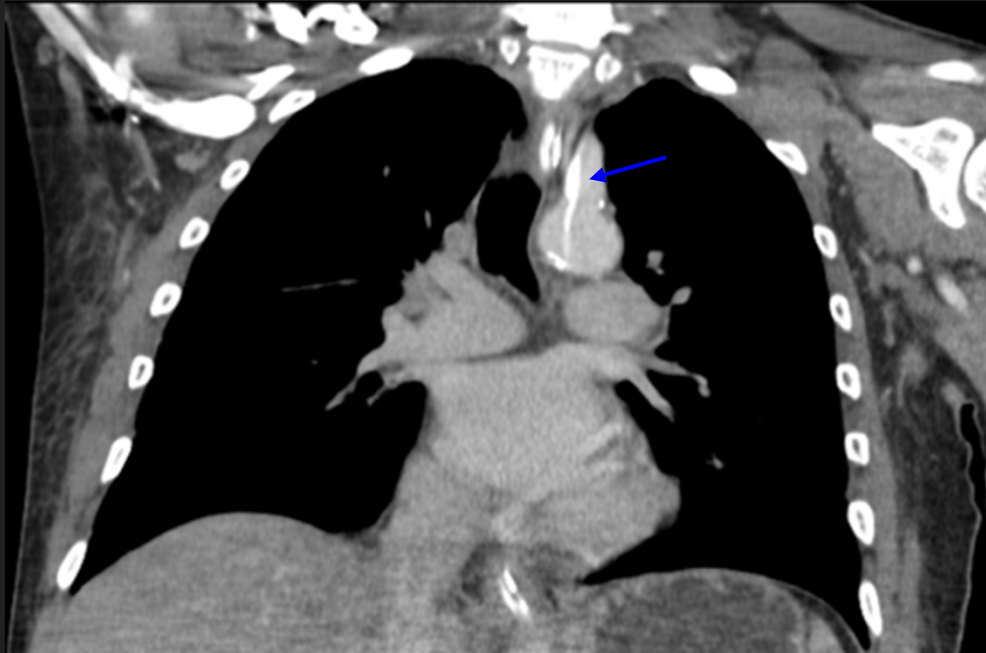
Left Subclavian line never crosses spine/midline. Tip projects over left mediastinum and aorta.

(Possible intra arterial placement)



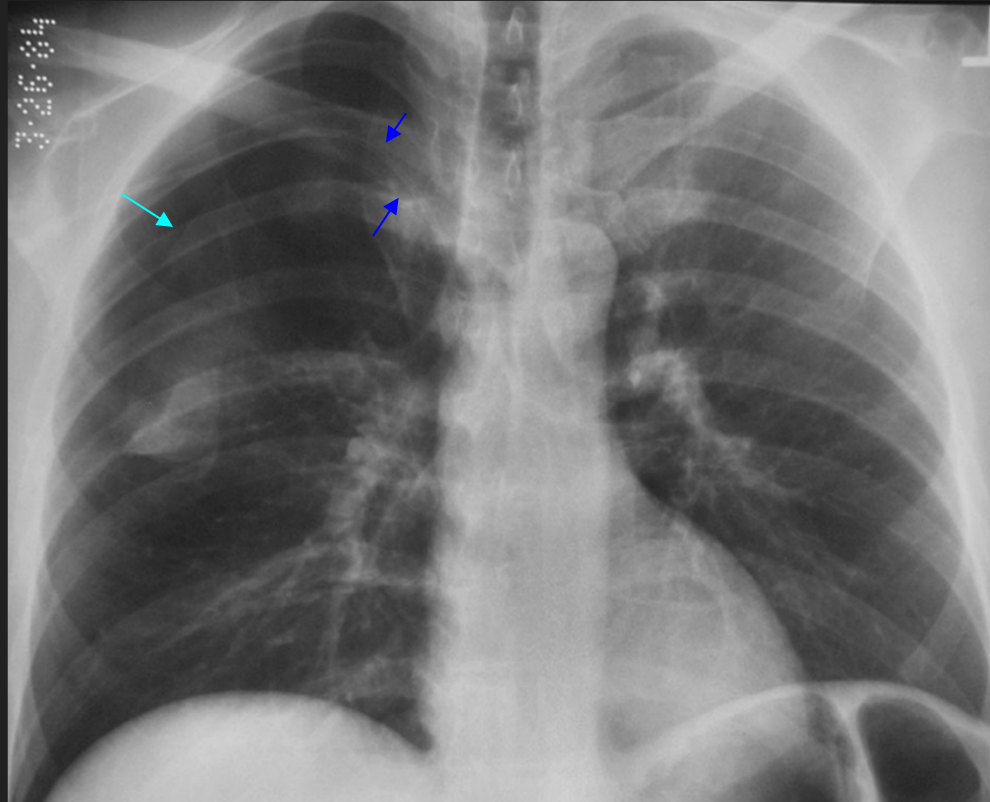
Central Venous Line: Misplaced

Intra arterial placement with line tip (Blue Arrow) in descending aorta.



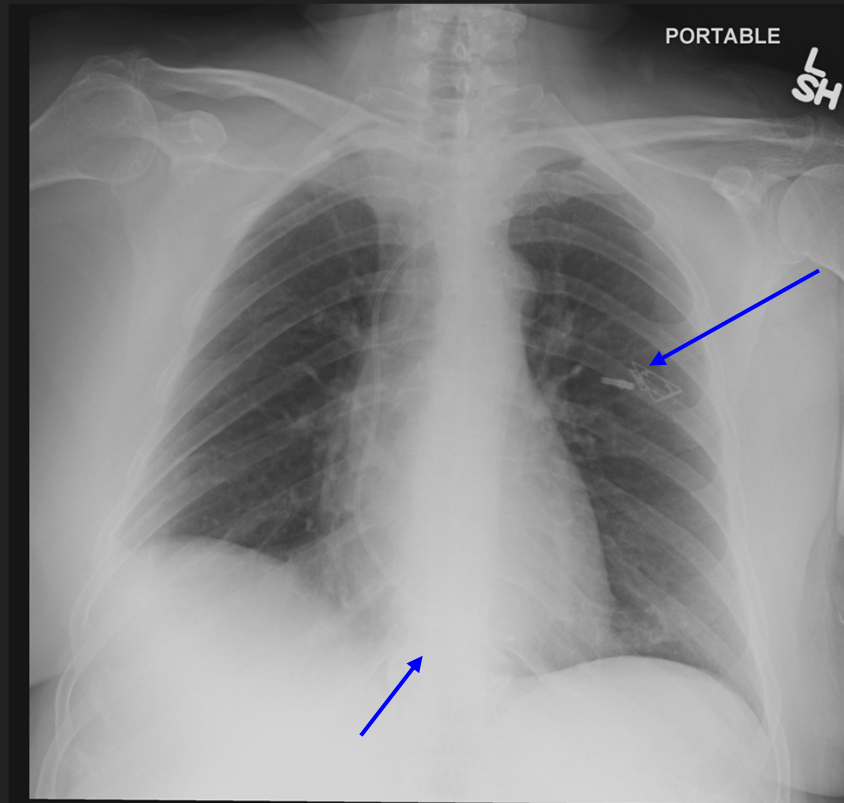
Central Venous Line, Complication: Pneumothorax

Right Subclavian
line (Blue arrow)
with
pneumothorax
(Light blue arrow).



Central Venous Line, Complication: Fracture

Port catheter that has fractured and migrated into heart



Swan Ganz Catheter

- Purpose

- Observe hemodynamic status of patient
- Distinguish cardiac from noncardiac pulmonary edema

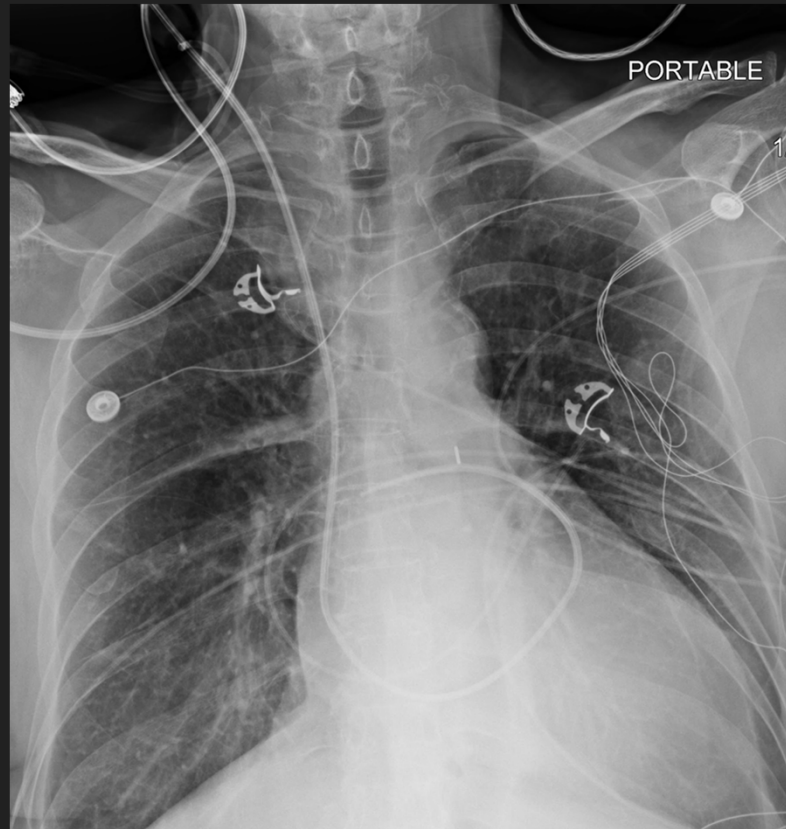- Proper Placement

- Inserted via a large vein (i.e. internal jugular or subclavian vein or common femoral vein) to terminate in proximal right or left pulmonary artery ~ 2cm from the hilum

- Complications

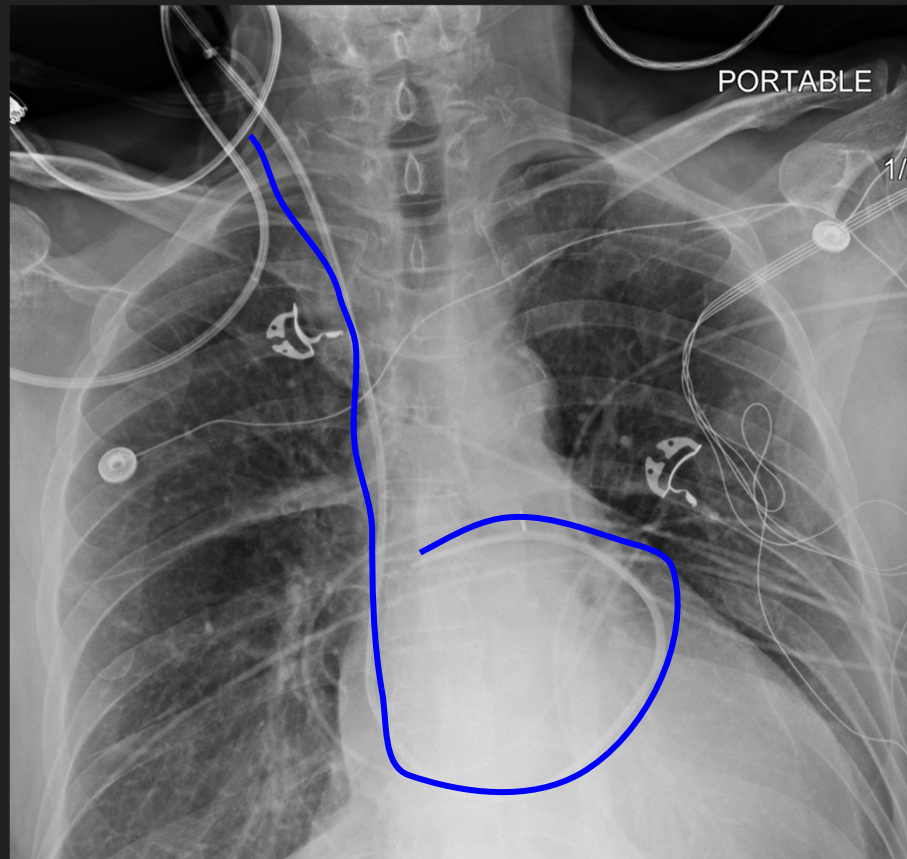
- Misplacement in large veins, right heart chambers, pulmonary trunk or peripheral pulmonary arteries
- Venous perforation
- Phlebitis, bleeding, thrombosis
- Right atrial or ventricular wall perforation
- Pulmonary infarction
- Pneumothorax

Swan Ganz Catheter: Proper Placement



Swan Ganz Catheter: Proper Placement

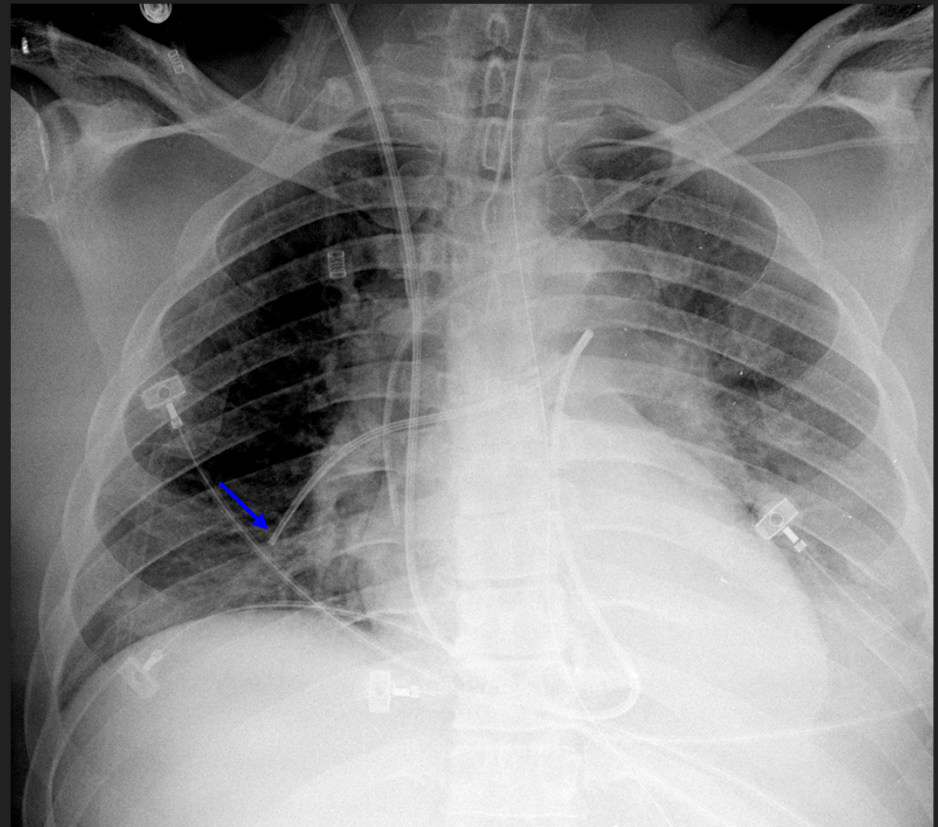
Right IJ
approach
with tip
projecting in
the mid right
pulmonary
artery



Swan Ganz Catheter: Misplaced

SG tip in distal right lower lobe artery.

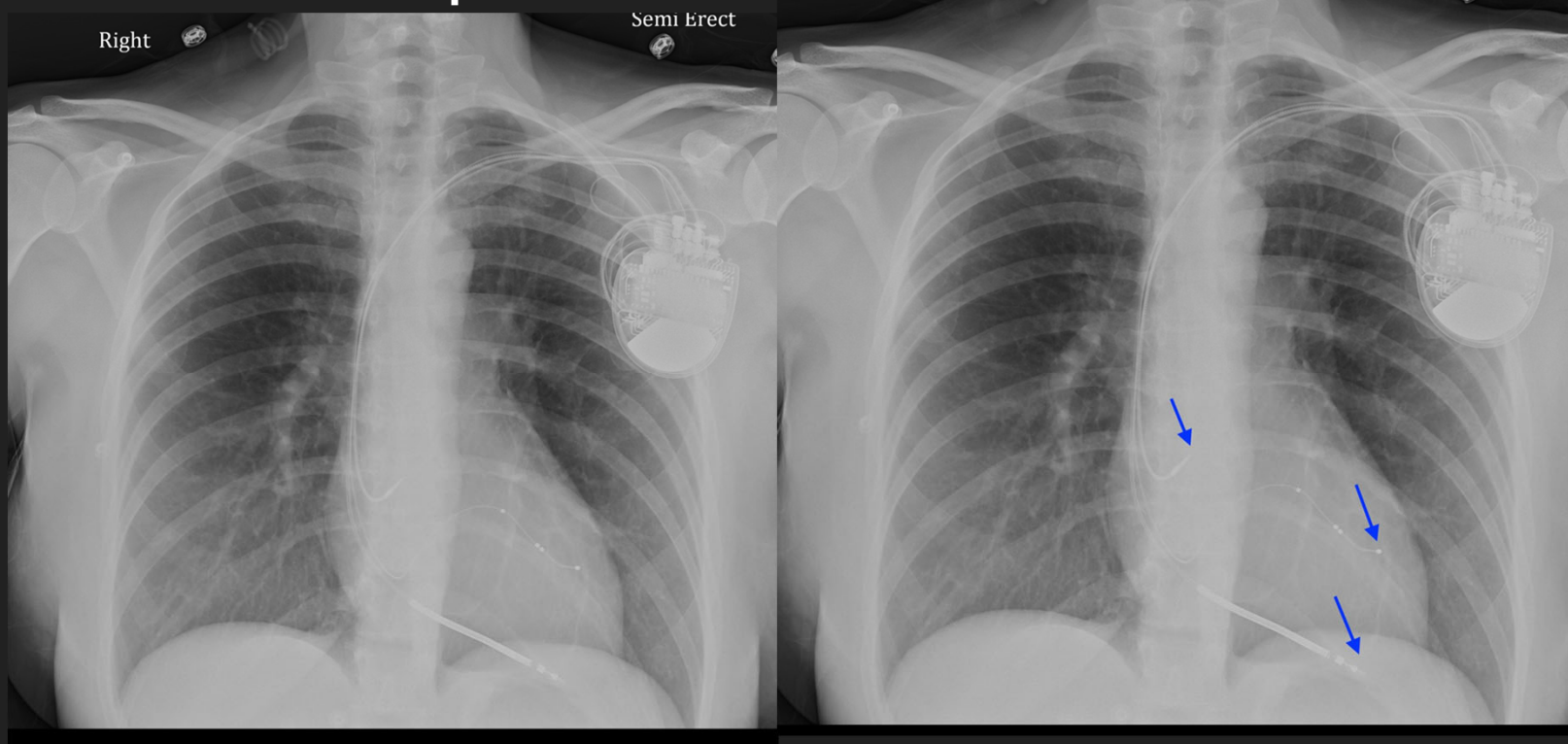
At risk of arterial rupture if the balloon is expanded and at risk of pulmonary infarction if tip enters smaller side branch.



Cardiac Pacemaker/Implantable Cardiac Defibrillator

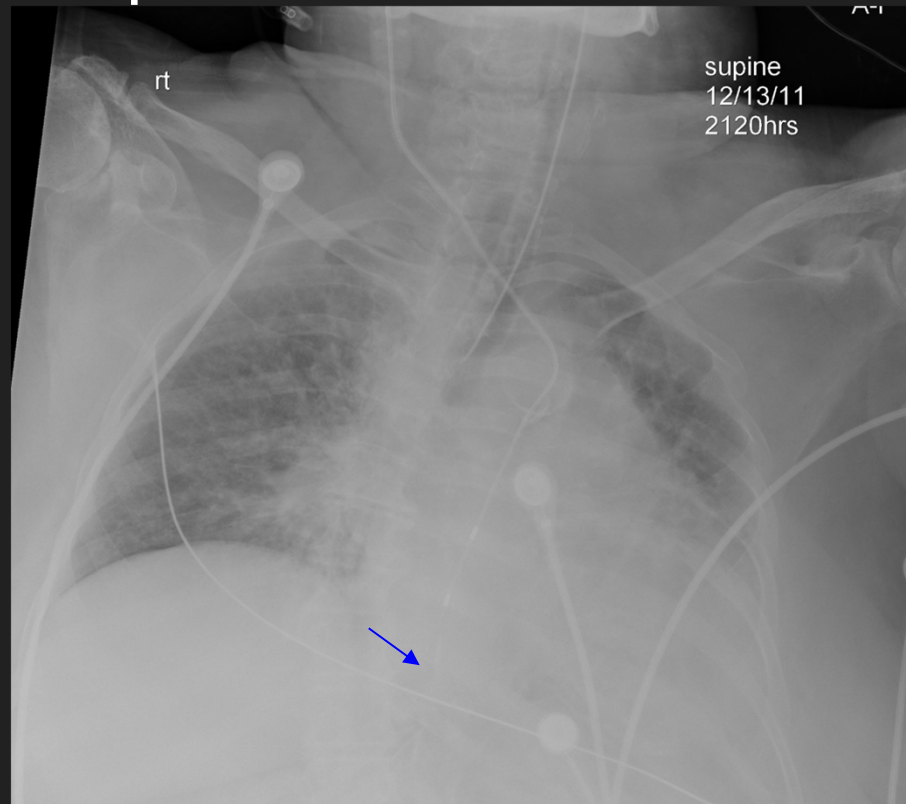
- Purpose
 - Assist in normal electrical conduction of the heart
 - Break ventricular fibrillation
- Proper Placement
 - Pulse generator/defibrillator is positioned in subcutaneous tissues of the anterior chest wall
 - Electrodes are guided via subclavian vein and SVC into right atrial appendage, right ventricle and coronary sinus
- Complications
 - Misplacement in the proximal veins or cardiac chambers
 - Perforation of the heart
 - Lead discontinuity
 - Pneumothorax
 - Pacemaker-mediated tachycardia
 - Infection

Cardiac Pacemaker/Implantable Cardiac Defibrillator: Proper Placement

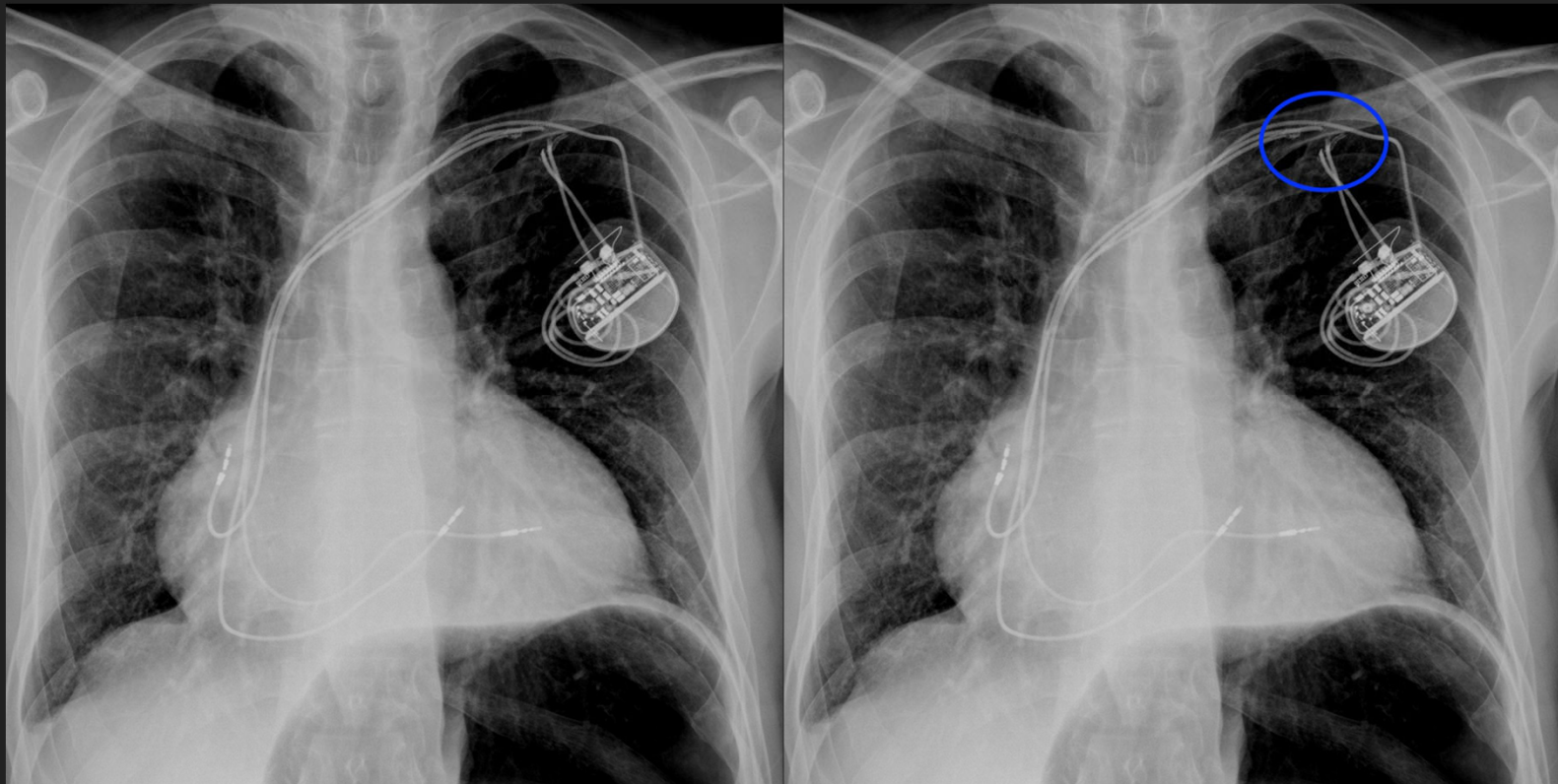


Cardiac Pacemaker/Implantable Cardiac Defibrillator: Misplaced

Right IJ cardiac lead extends into the aorta, terminating in the distal descending thoracic aorta

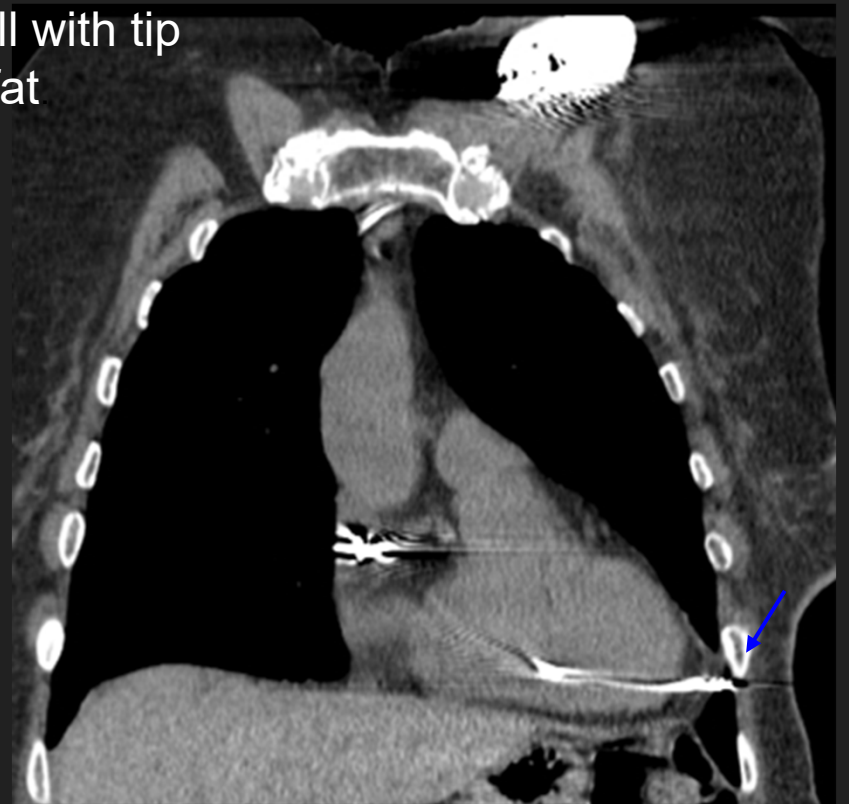
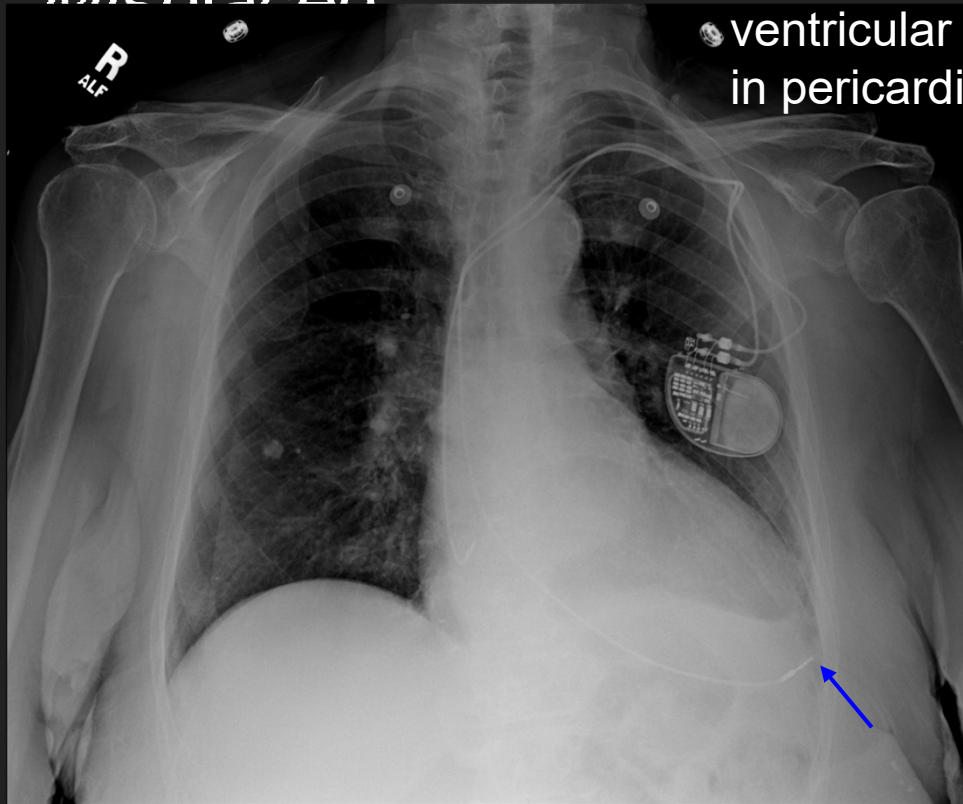


Cardiac Pacemaker/Implantable Cardiac Defibrillator: Fractured Leads



Cardiac Pacemaker/Implantable Cardiac Defibrillator: Misplaced

RV lead though right
ventricular wall with tip
in pericardial fat



The End

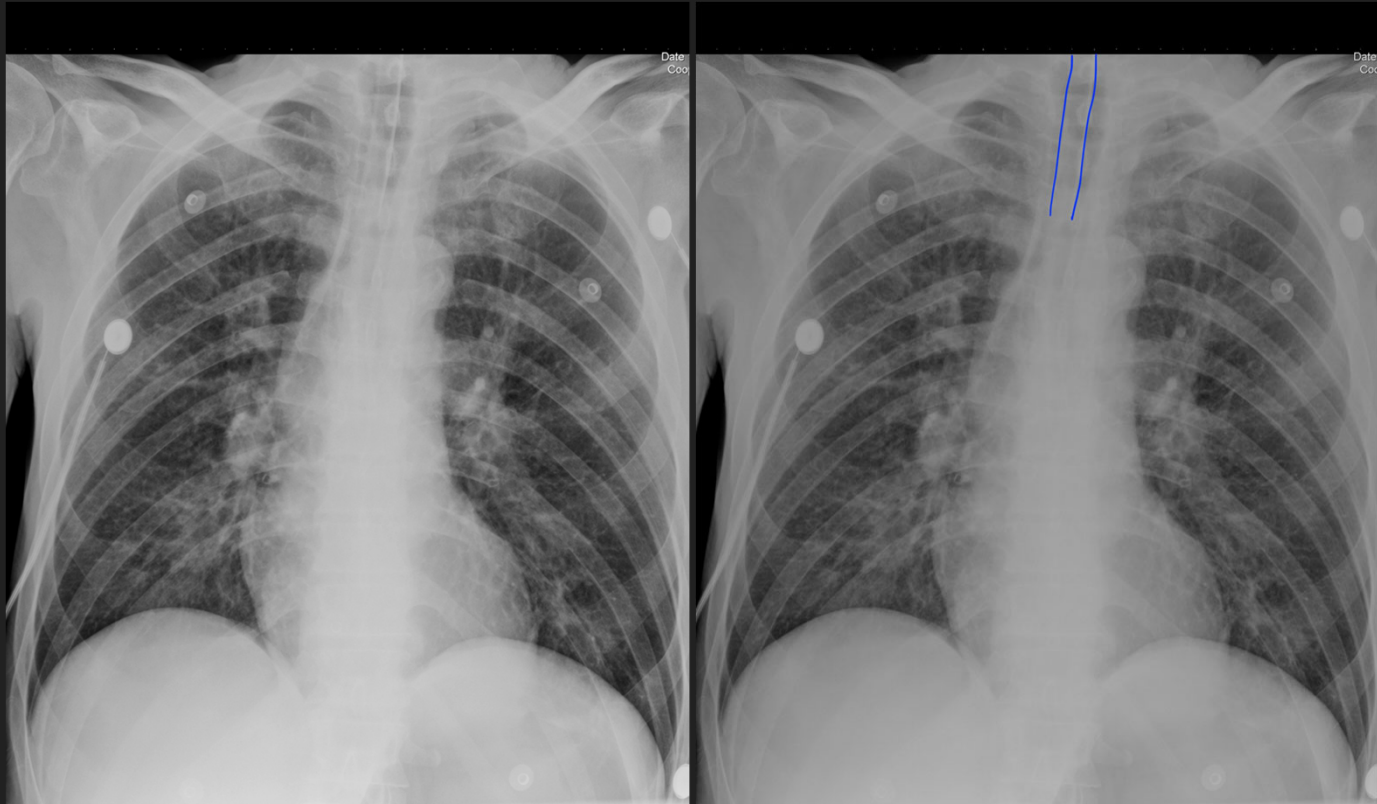
Approach

- Evaluate Lines and Tubes first.
- Identify and assess placement of each line/tube individually.
- Look for expected complications.
- Report all complications present.
- Report absence of common complications. (Ex: Right subclavian line is in appropriate position. No pneumothorax.)
- Report lines/tubes as being in correct or appropriate position,
- NOT as stable.

Endotracheal Tube

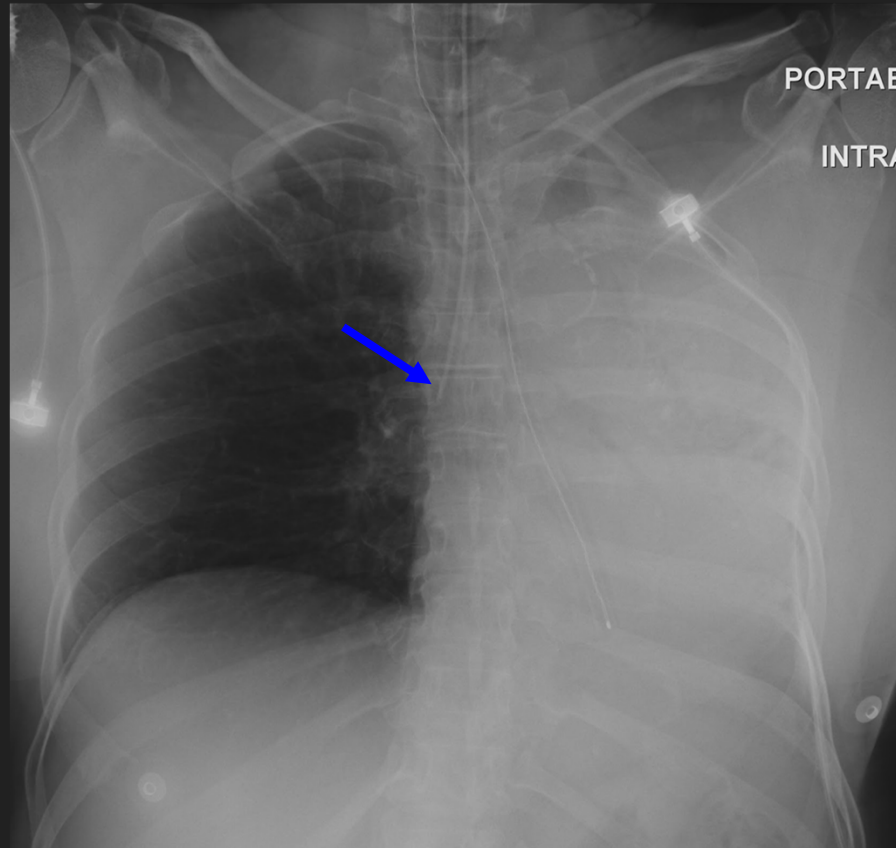
- Purpose:
 - Airway control during assisted ventilation
 - Access for airway suctioning
 - Potential route for medication administration
- Proper placement:
 - Should terminate 2-5cm above the carina, or ½ way between carina and clavicles
 - Balloon of the tube should not be hyperinflated
- Complications:
 - Misplacement in the pharynx or right/left mainstem bronchi
 - Atelectasis
 - Aspiration
 - Pneumothorax
 - Vocal cord injury
 - Tracheal wall injury
 - Esophageal dilatation

Endotracheal Tube: Proper Placement



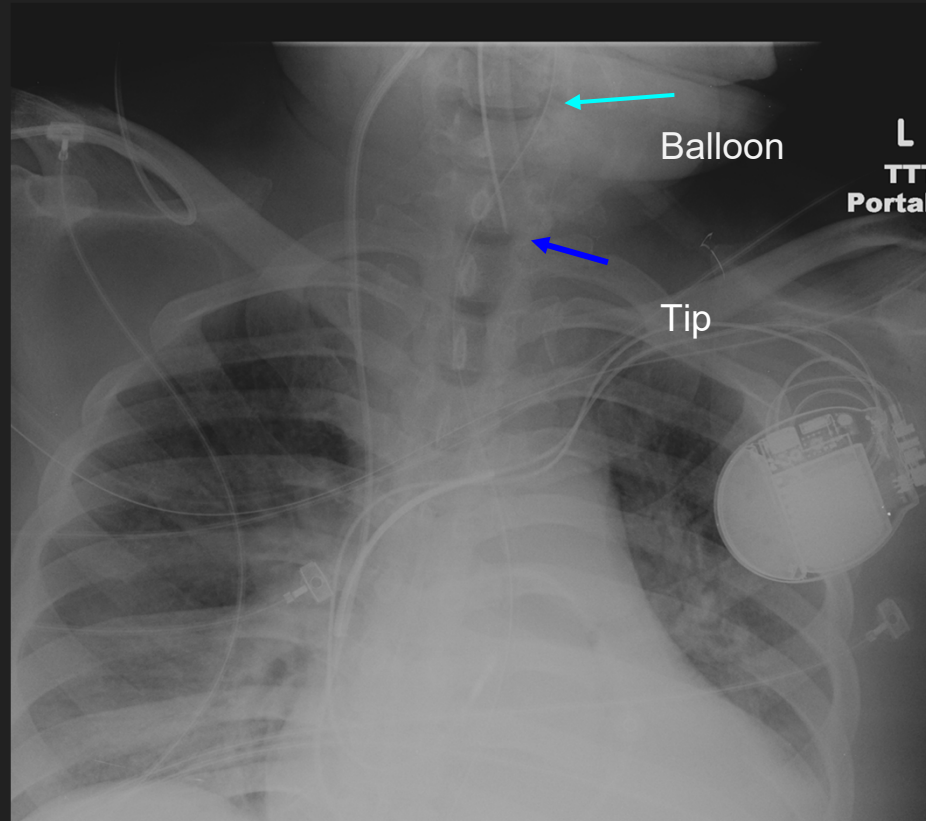
Endotracheal Tube: Misplaced

ET tip in the Right
Mainstem
Bronchus with
complete Left lung
atelectasis



Endotracheal Tube: Misplaced

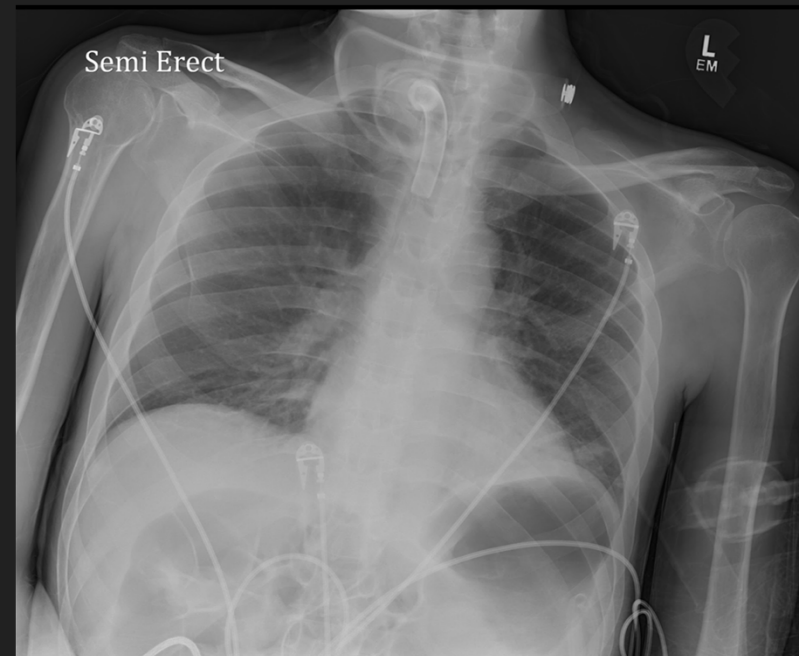
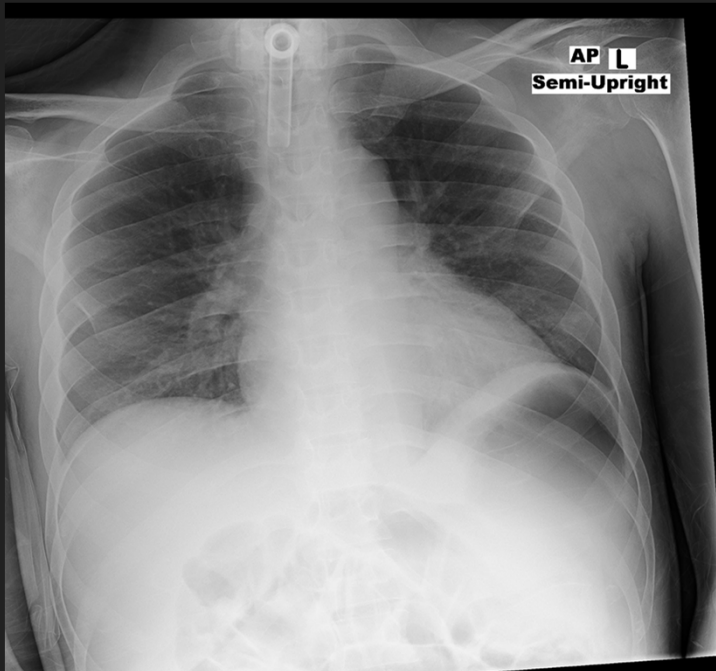
ET Tip and
balloon in
the neck



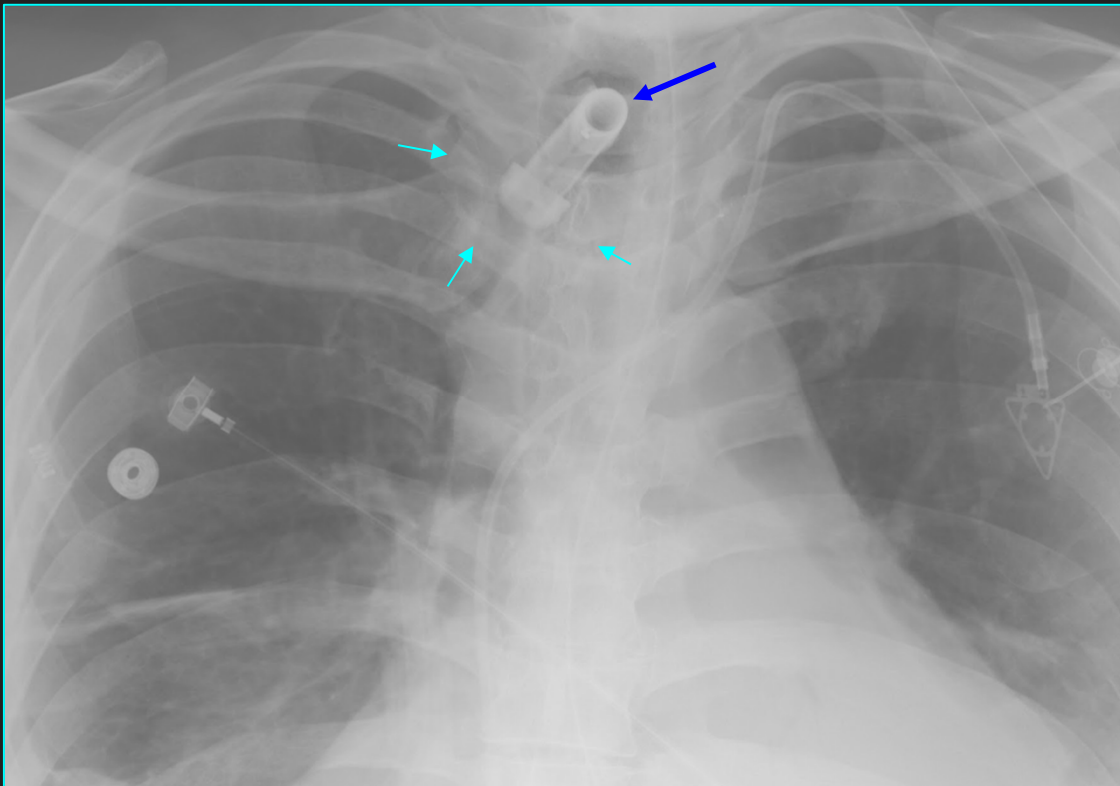
Tracheostomy Tube

- Purpose:
 - Long term airway access in patients with obstruction at or above larynx
- Proper placement:
 - Should terminate $\frac{1}{2}$ way between the stoma and carina (~T3 level)
- Complications:
 - Misplacement in lungs, mediastinum or subcutaneous tissues
 - Perforation of trachea
 - Aspiration
 - Pneumomediastinum or pneumothorax
 - Tracheal wall injury/stenosis

Tracheostomy Tube: Proper Placement



Tracheostomy Tube: Misplaced

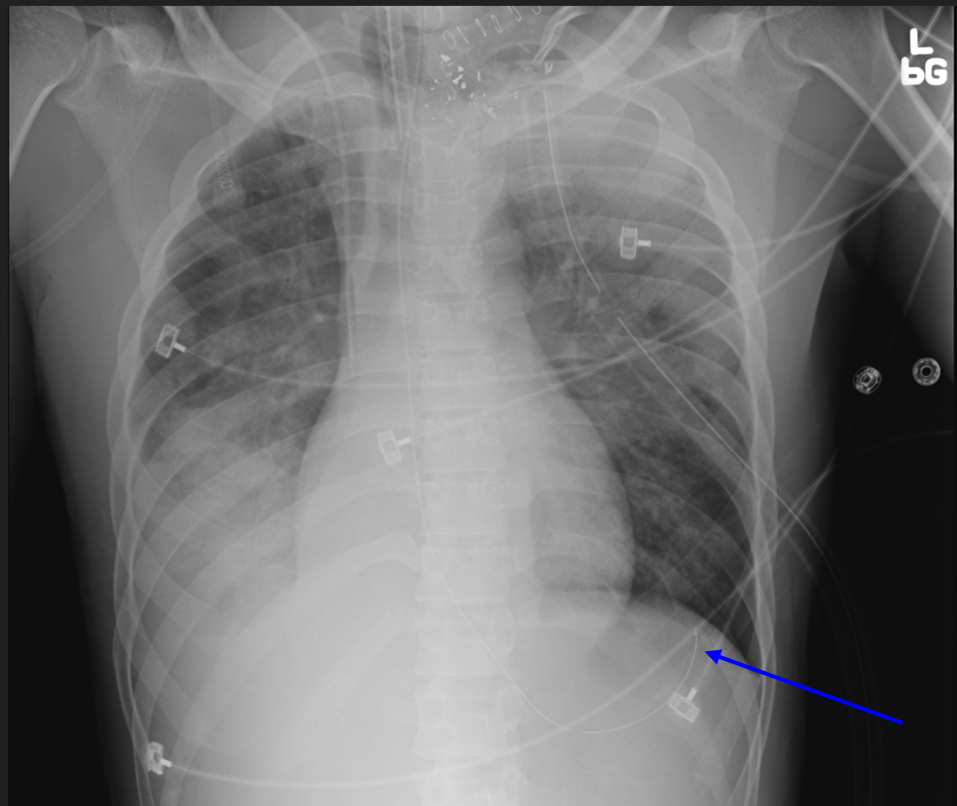


The flange (light blue arrows) marks the outside tip and the blue arrow points to the internal tip which is not curving into the trachea. The tracheostomy tube is almost out.

Nasogastric tube

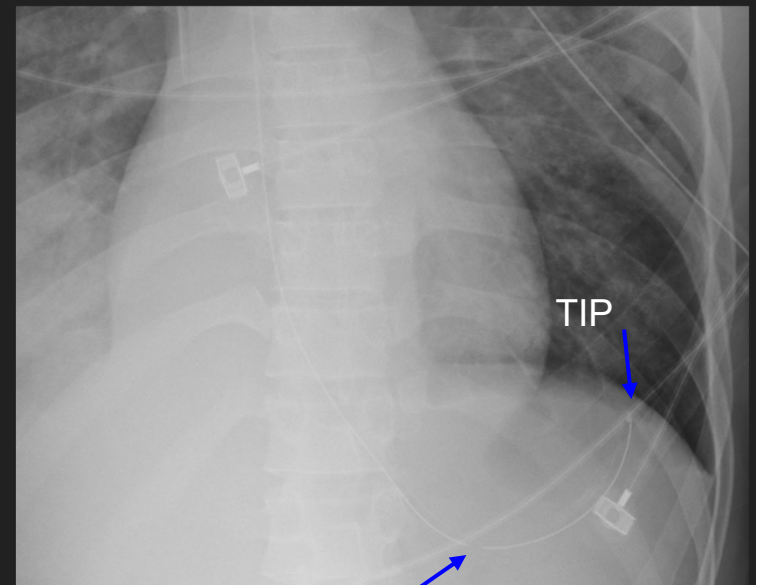
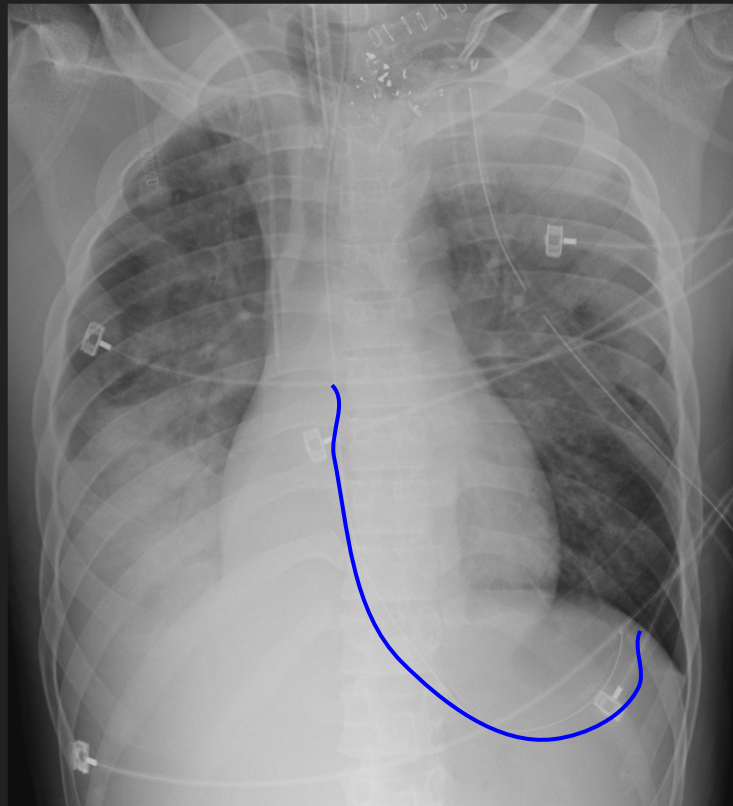
- Purpose
 - Short term feeding
 - Gastric suction & decompression
 - Medication administration
- Proper placement
 - Inserted via the nose, through esophagus into the stomach
 - Tip and side hole should extend into the stomach
- Complications
 - Misplacement in the oropharynx, esophagus or airway
 - Esophagitis, reflux, stricture, esophageal perforation
 - Aspiration
 - Lung injury, pneumothorax or hydropneumothorax

Nasogastric Tube: Proper Placement



Nasogastric Tube: Proper Placement

Both the tip and the sidehole are below the left diaphragm.

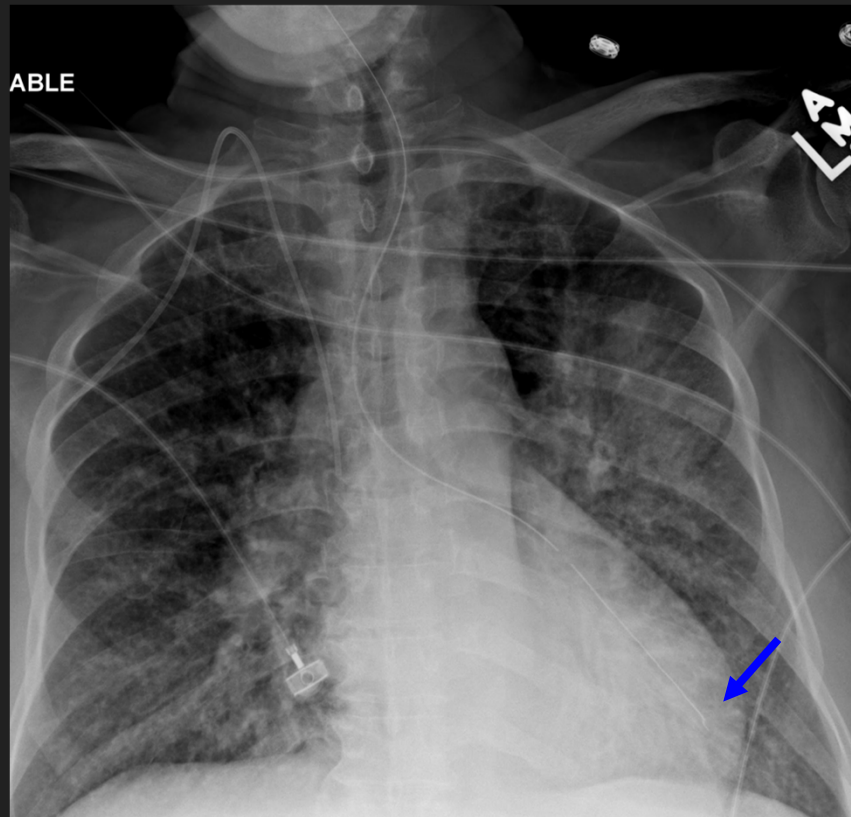


Sidehole

TIP

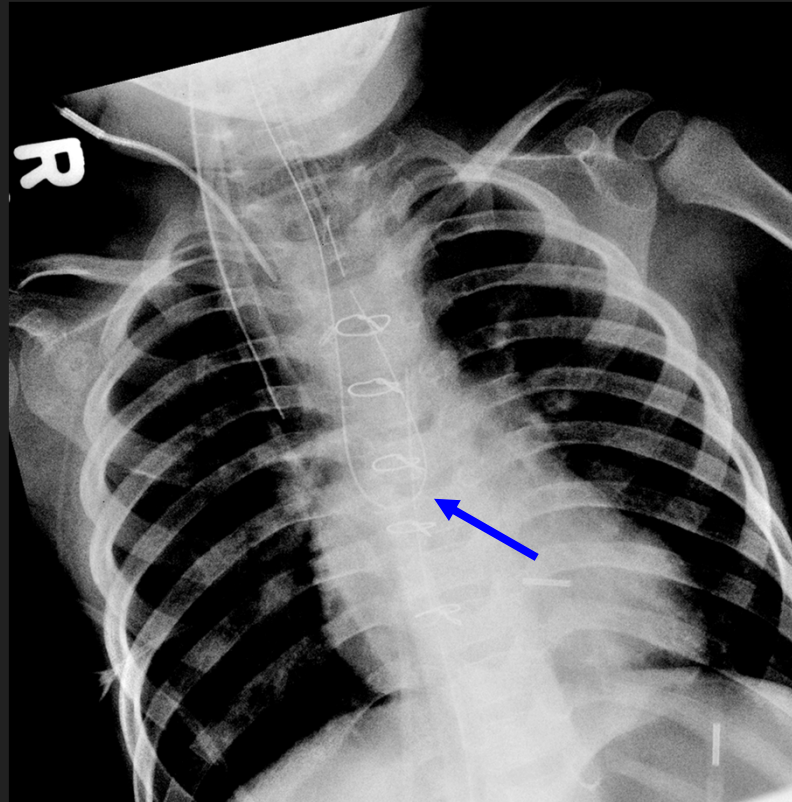
Nasogastric Tube: Misplaced

NG tube
terminates in
the Left Lower
Lobe bronchus



Nasogastric Tube: Misplaced

NG tube is
coiled in
Esophagus
with tip in
throat

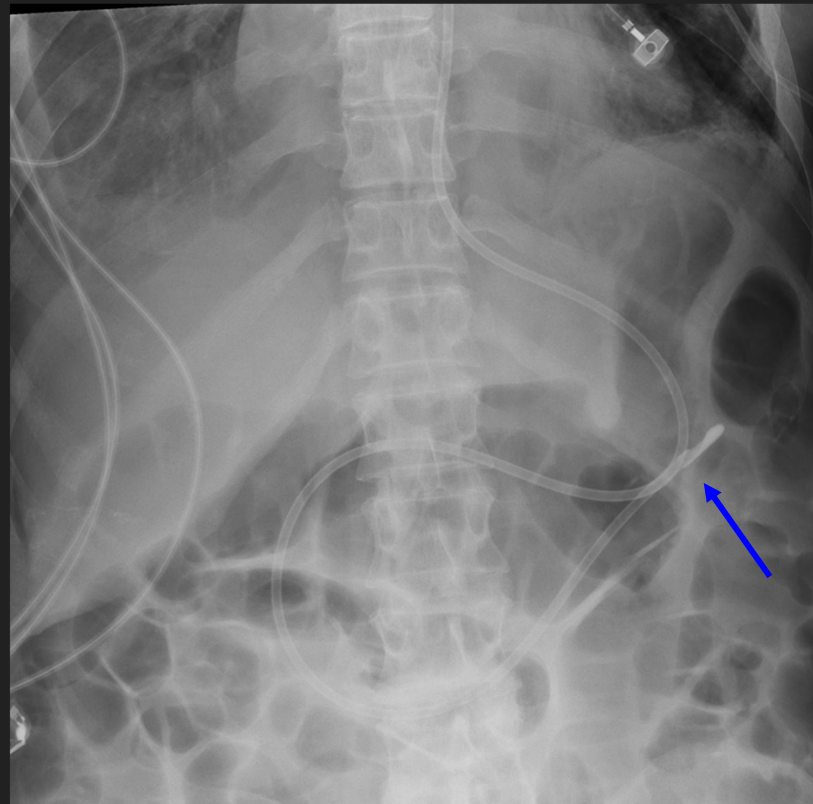
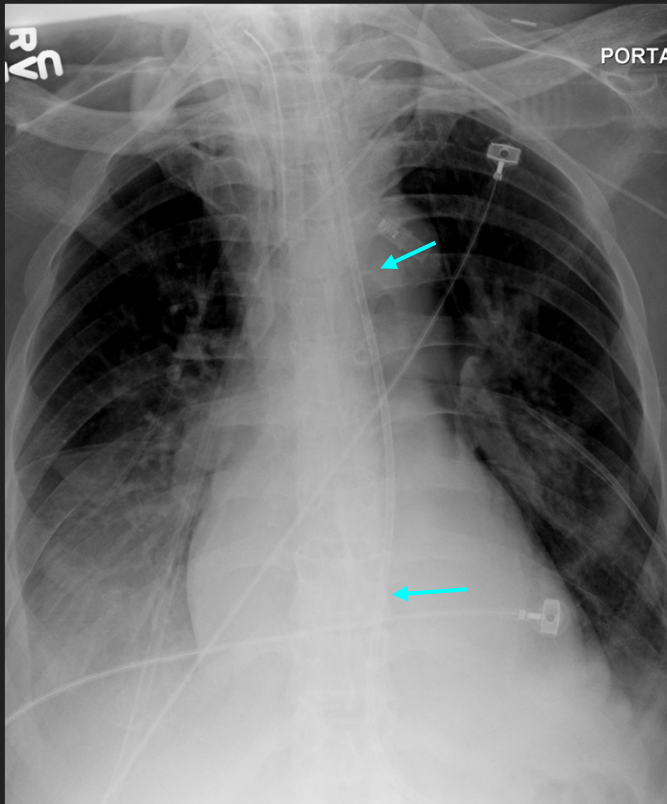


Dobbhoff Tube

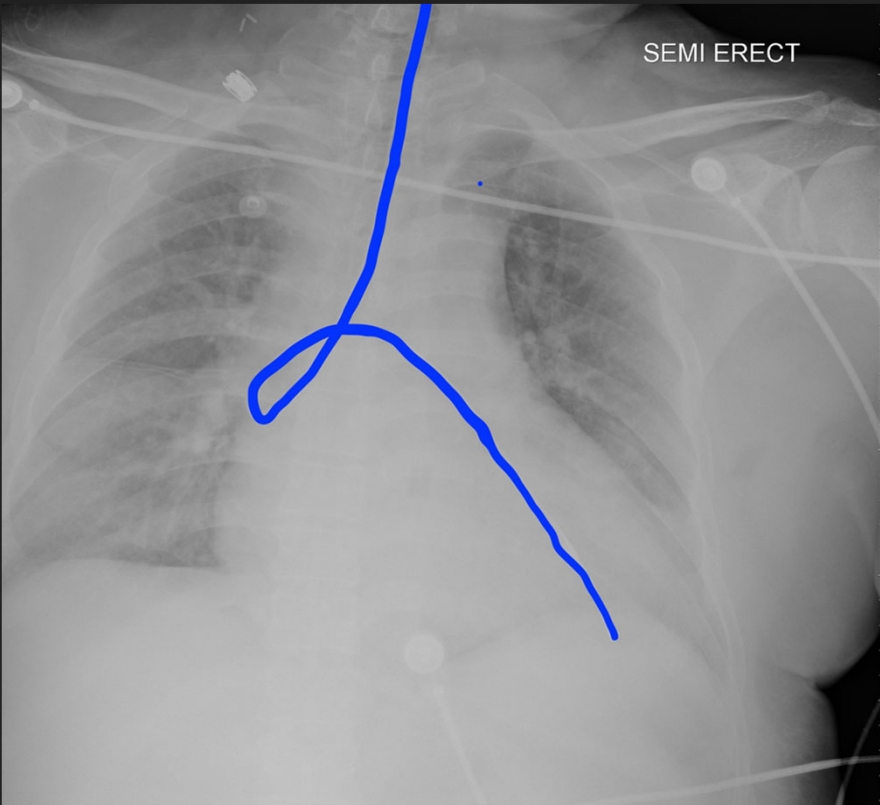
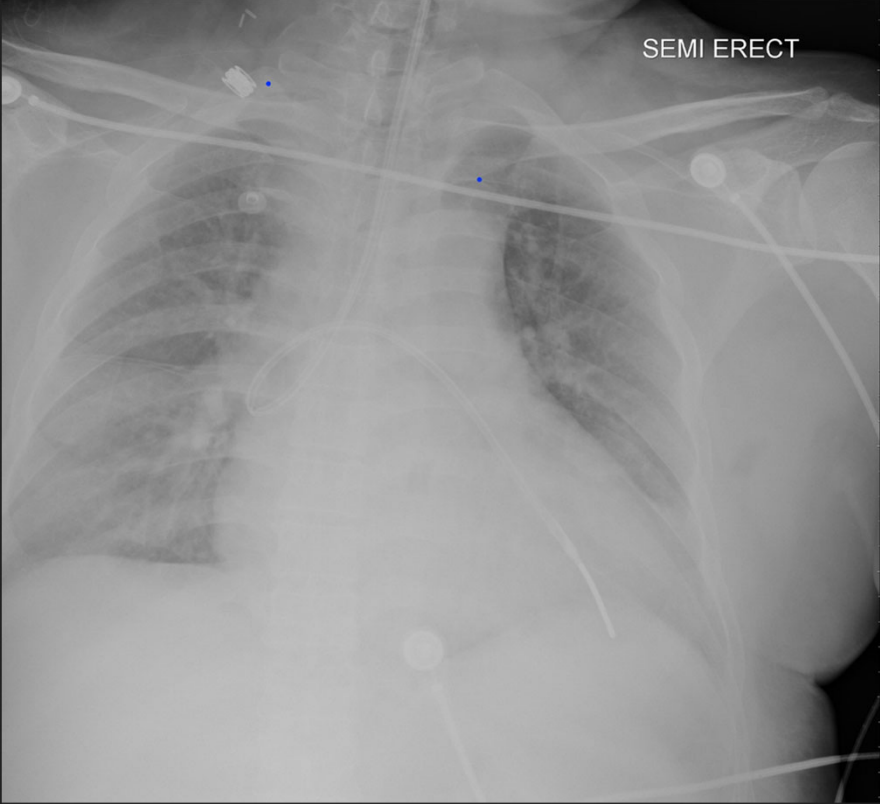
- Purpose
 - Short term feeding
 - Prevent aspiration
- Proper Placement
 - Inserted via the pharynx, through esophagus and stomach into the duodenum
 - Weighted tip should terminate in the proximal duodenum, past the level of the duodenal bulb [Ideally tip should be at the Ligament of Treitz.]
- Complications
 - Misplacement in the oropharynx, esophagus, stomach or airway
 - Esophagitis, reflux, stricture, esophageal perforation

Dobbhoff Tube: Proper Placement

Chest and abdomen exam show DT following the course of esophagus and stomach to the Ligament of Treitz



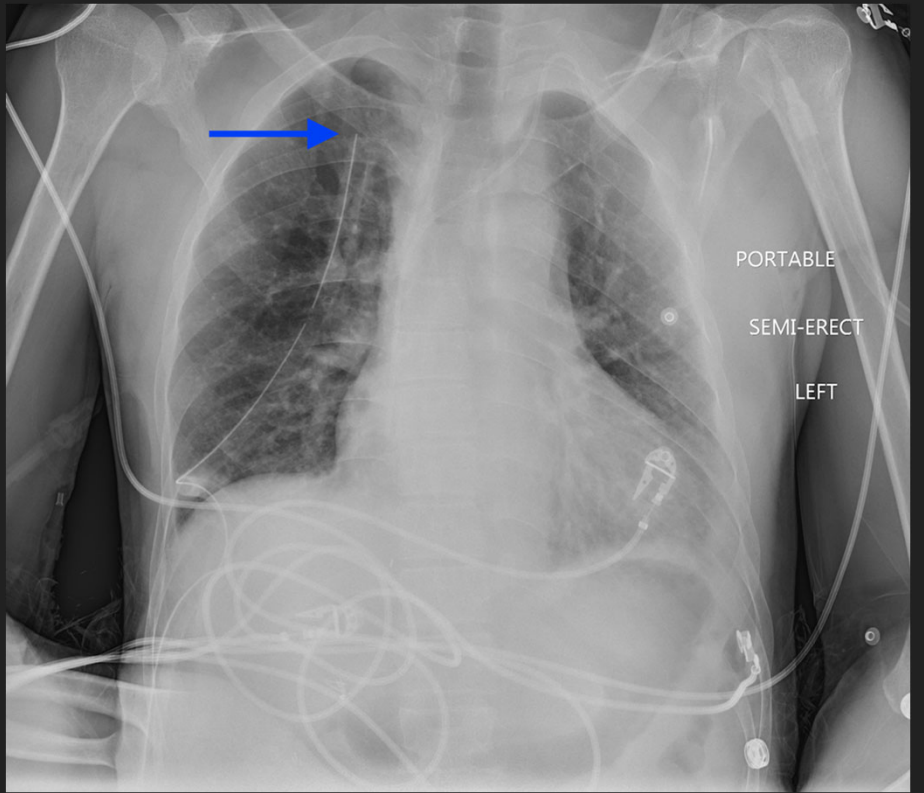
Dobbhoff Tube: Misplaced



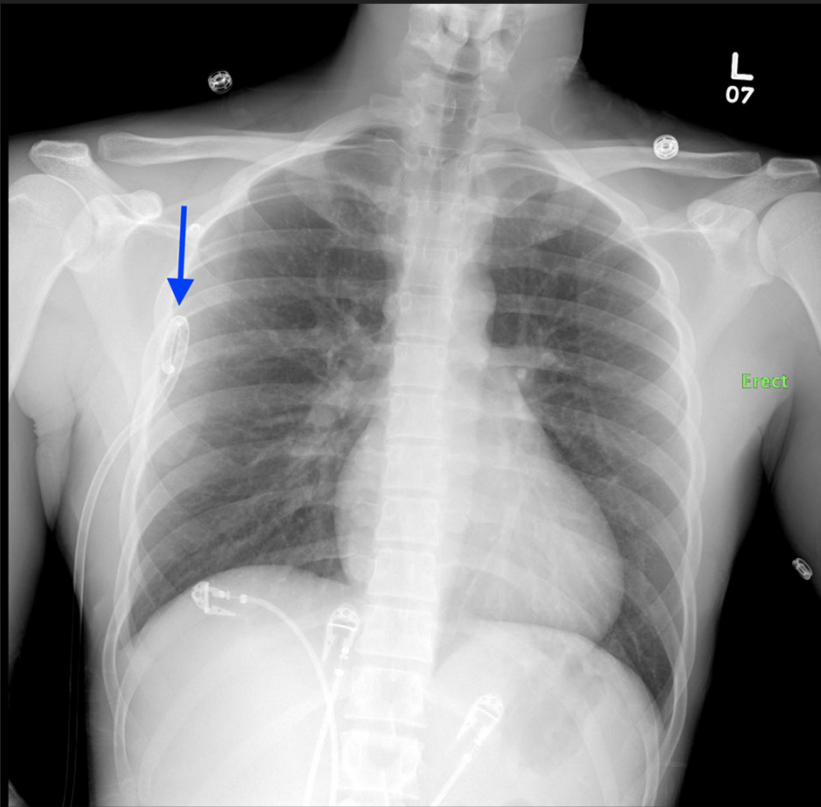
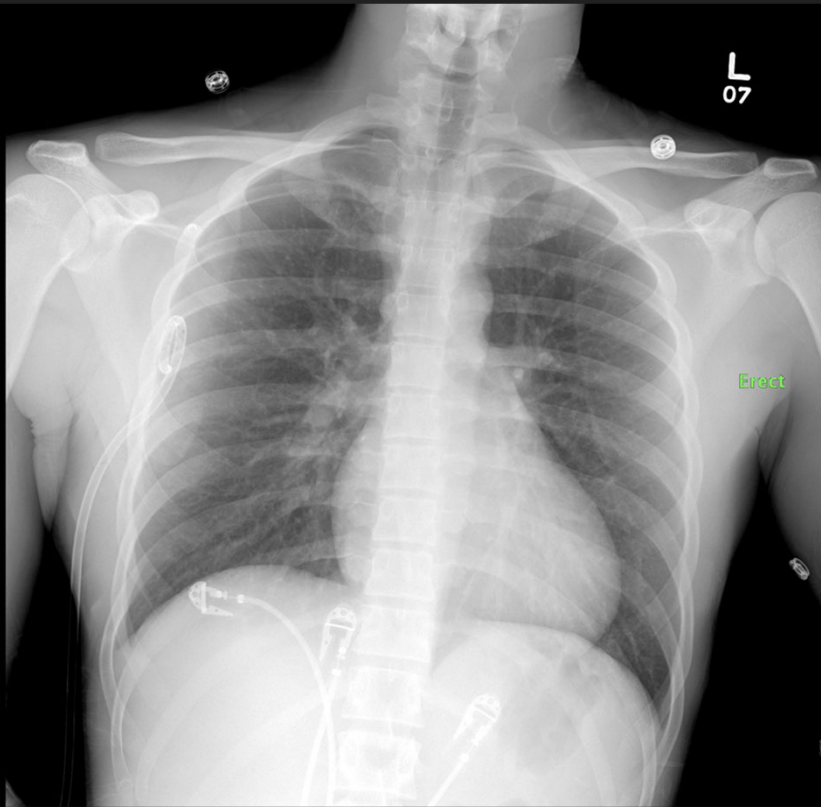
Chest Tube

- Purpose
 - Remove air or fluid from the pleural space
- Proper Placement
 - For air evacuation, tip should point anterosuperior
 - For fluid evacuation, tip should point posteroinferior
 - Side holes should be inside the thorax
- Complications
 - Misplacement in the fissures, parenchyma, mediastinum, or diaphragm
 - Pneumothorax
 - Inadequate drainage
 - Air leak
 - Infection
 - Bleeding from intercostal arteries
 - Injury to diaphragm or upper abdominal organs

Chest Tube: Proper Placement

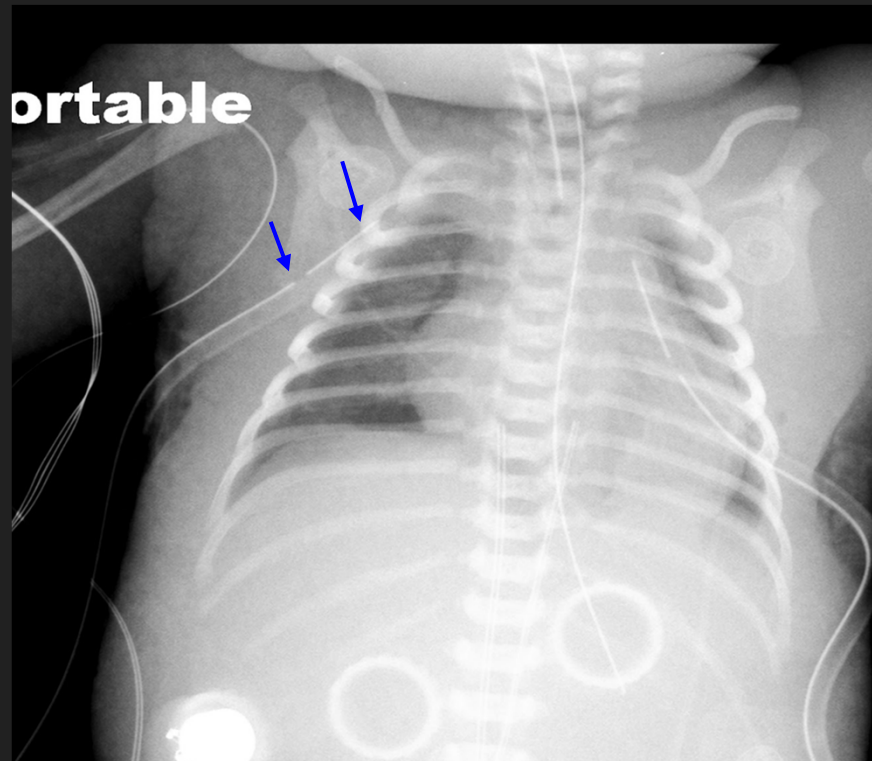


Chest Tube: Proper Placement



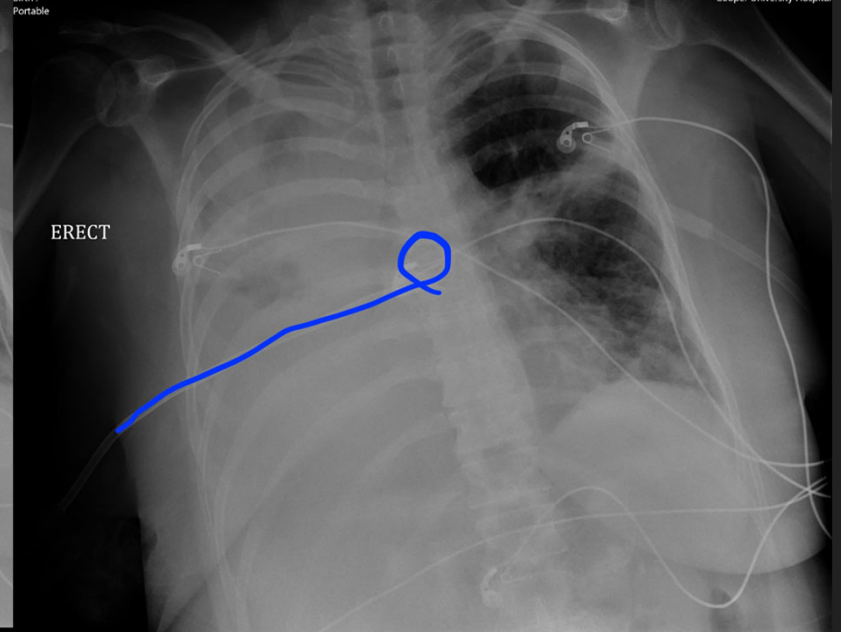
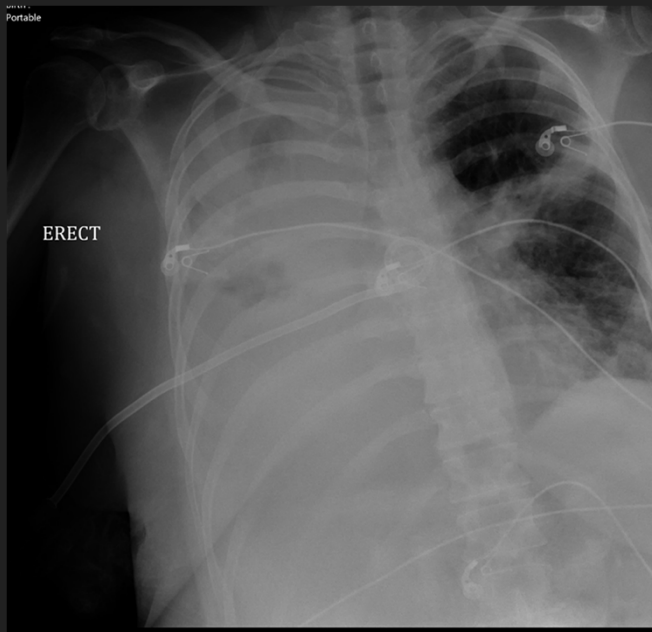
Chest Tube: Misplaced

Right chest
tube in chest
wall



Chest Tube: Misplaced

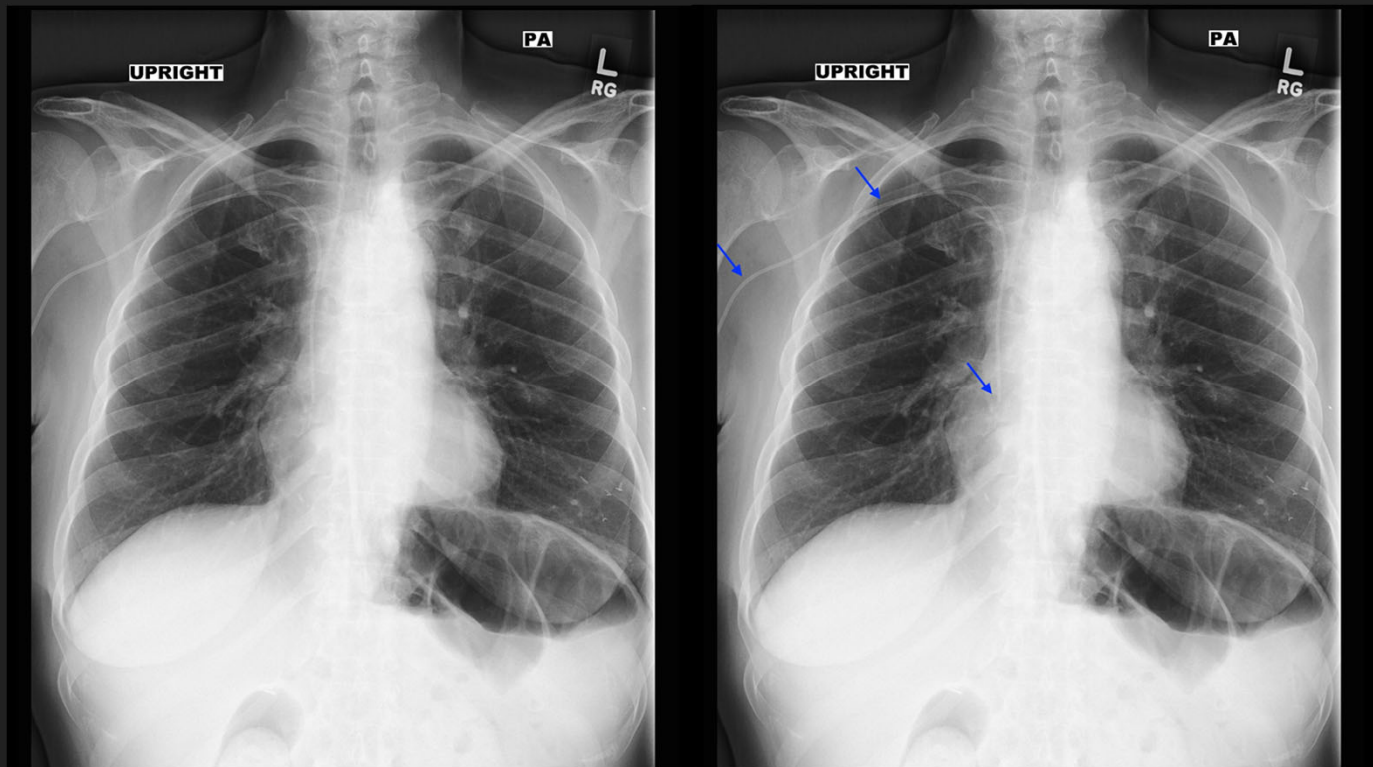
Right chest tube projects over the mediastinum and was coiled in right main pulmonary artery on subsequent CT



Peripherally Inserted Central Catheter

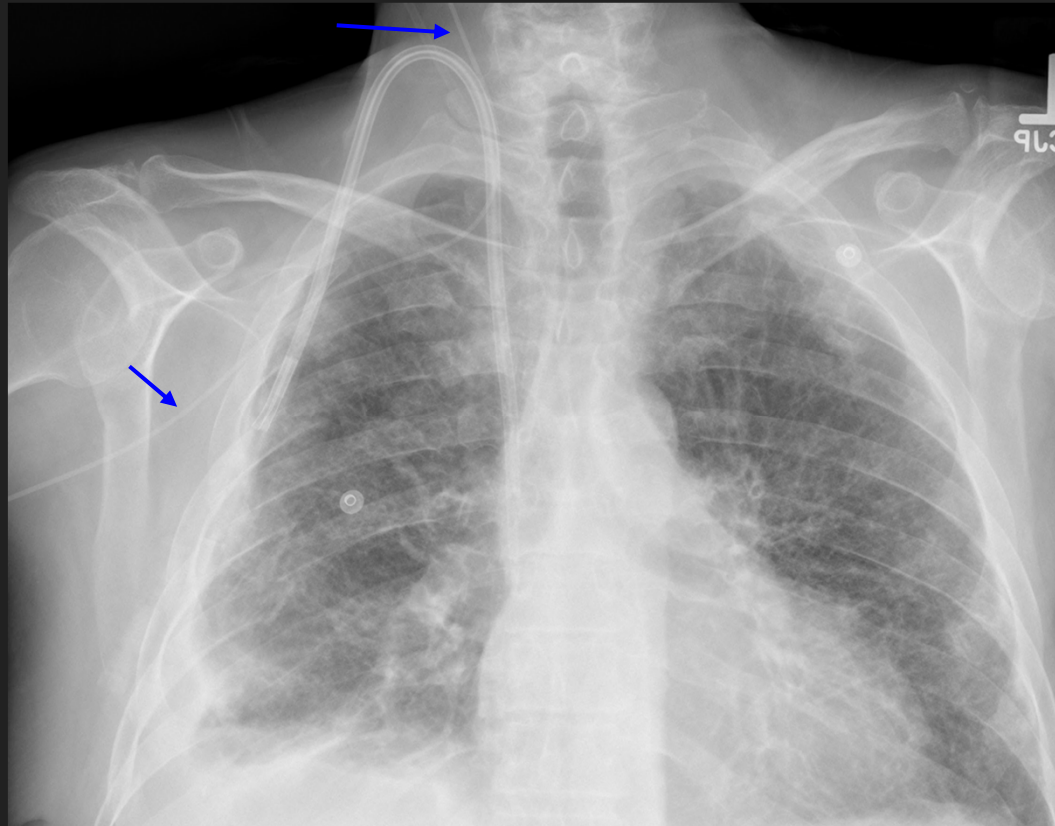
- Purpose
 - Establish long-term venous access
- Proper Placement
 - Inserted via peripheral veins (i.e. basilic vein, brachial vein, cephalic vein or axillary vein) to terminate in the superior vena cava
- Complications
 - Misplacement in right heart chambers
 - Phlebitis, bleeding, thrombosis
 - Venous perforation
 - Pain
 - Sepsis

Peripherally Inserted Central Catheter: Proper Placement



Peripherally Inserted Central Catheter: Misplaced

Right PICC
line going up
the right
jugular vein

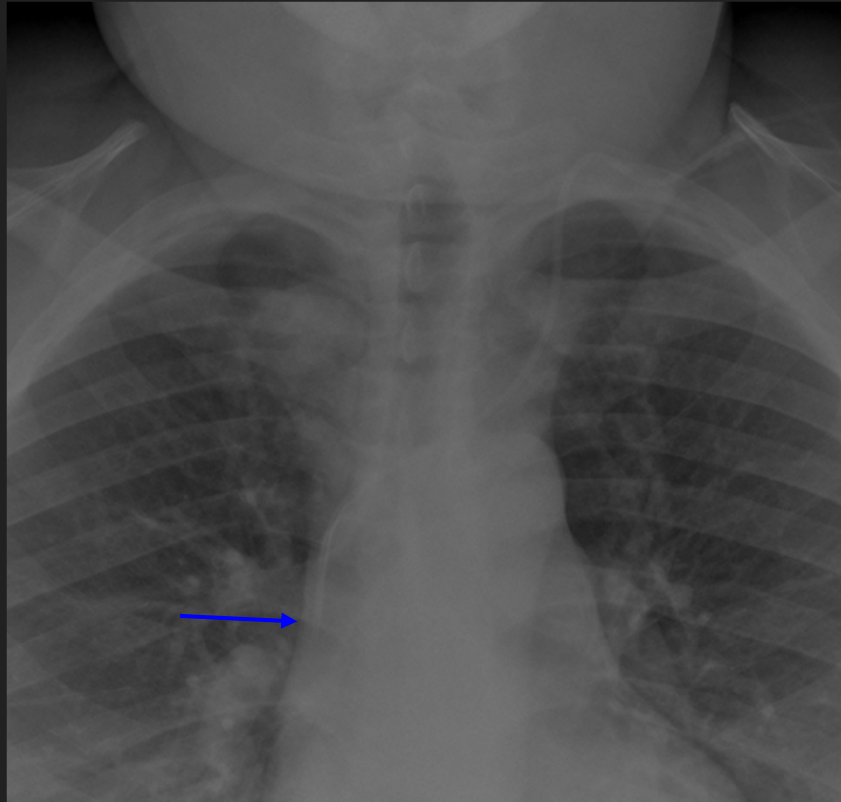


Central Venous Lines (CVL)

- Purpose
 - Central venous access for fluids, medications, IV contrast
- Proper Placement
 - Tip in the SVC-distal to subclavian/jugular junction and proximal to the right atrium
 - Small sleeve of SVC extends into right atrium
- Complications
 - Malposition
 - Pneumothorax
 - Hemothorax
 - Mediastinal hematoma
 - Fracture of the line

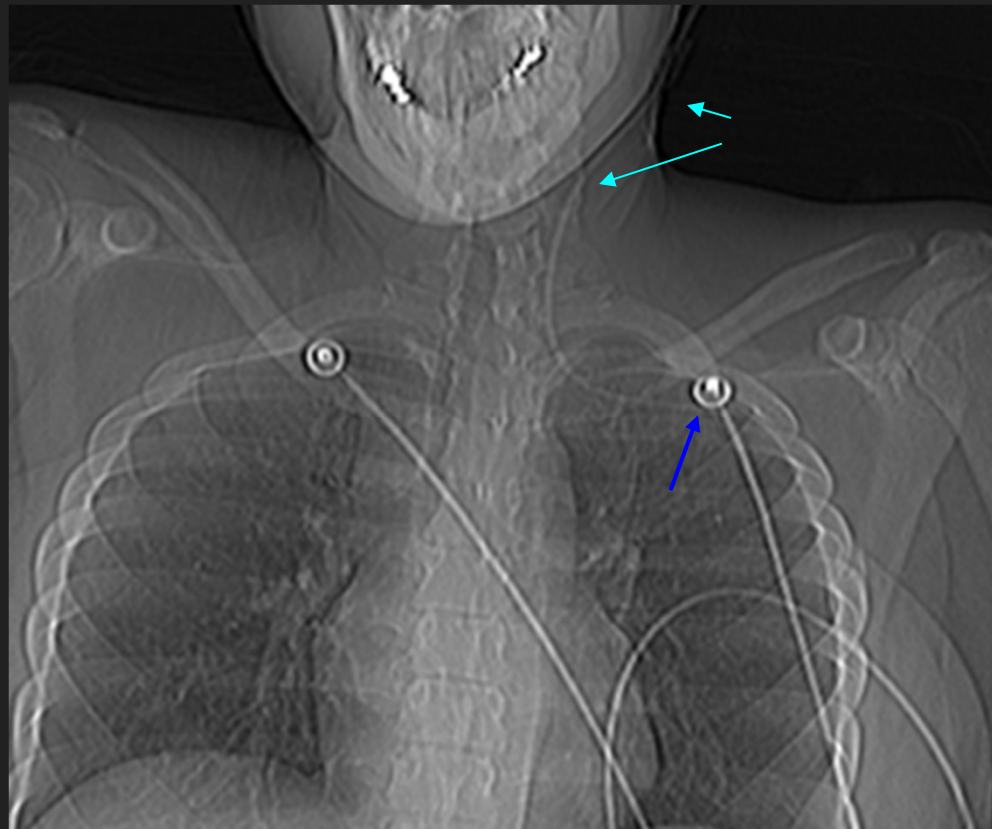
Central Venous Line: Proper Placement

Left Internal
Jugular (IJ)
line with tip in
mid-SVC



Central Venous Line: Misplaced

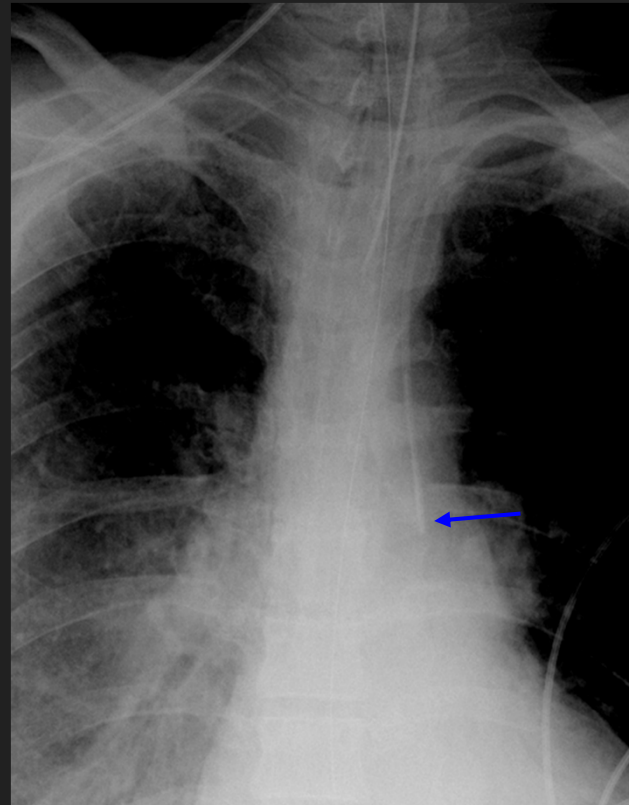
Left IJ (light blue arrow) with tip in Left Subclavian vein (Blue arrow)



Central Venous Line: Misplaced

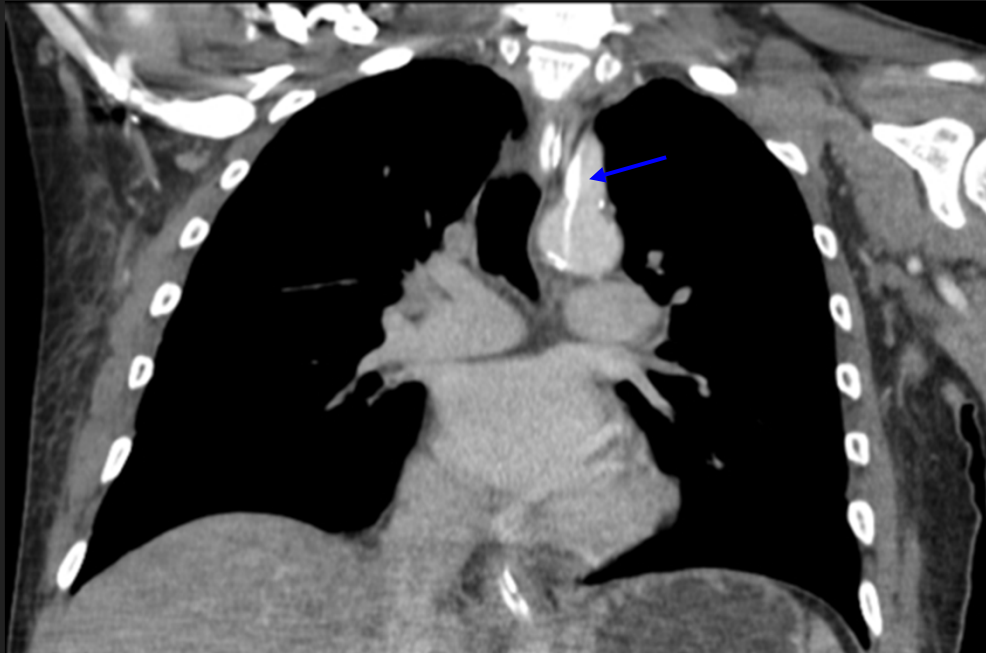
Left Subclavian line never crosses spine/midline. Tip projects over left mediastinum and aorta.

(Possible intra arterial placement)



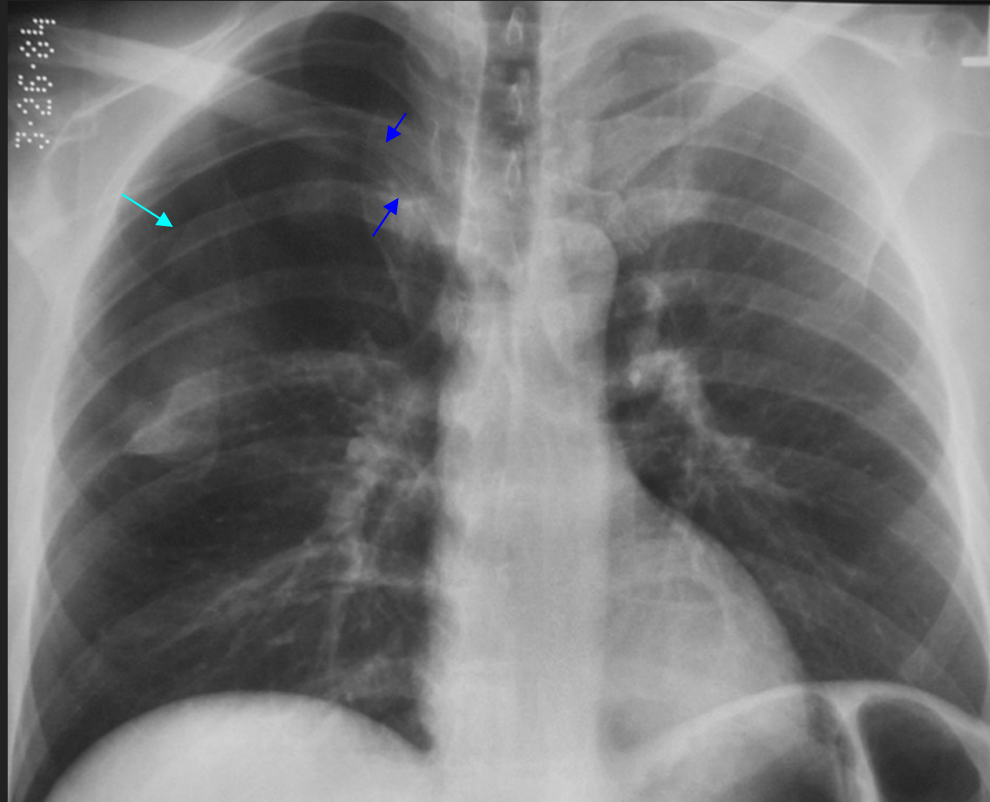
Central Venous Line: Misplaced

Intra arterial placement with line tip (Blue Arrow) in descending aorta.



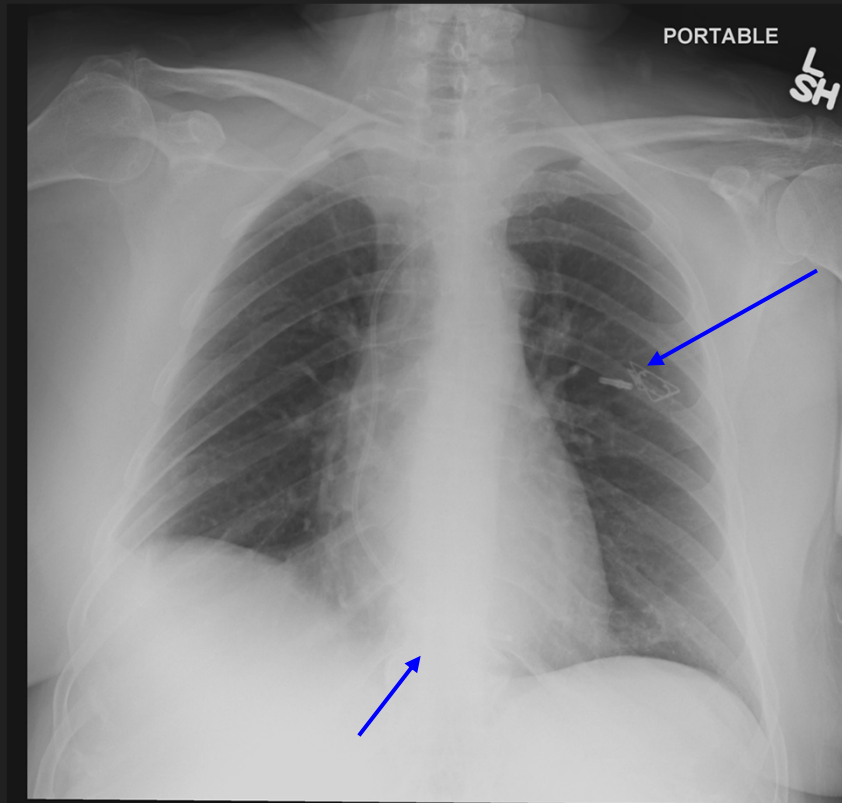
Central Venous Line, Complication: Pneumothorax

Right Subclavian
line (Blue arrow)
with
pneumothorax
(Light blue arrow).



Central Venous Line, Complication: Fracture

Port catheter that has fractured and migrated into heart



Swan Ganz Catheter

- Purpose

- Observe hemodynamic status of patient
- Distinguish cardiac from noncardiac pulmonary edema

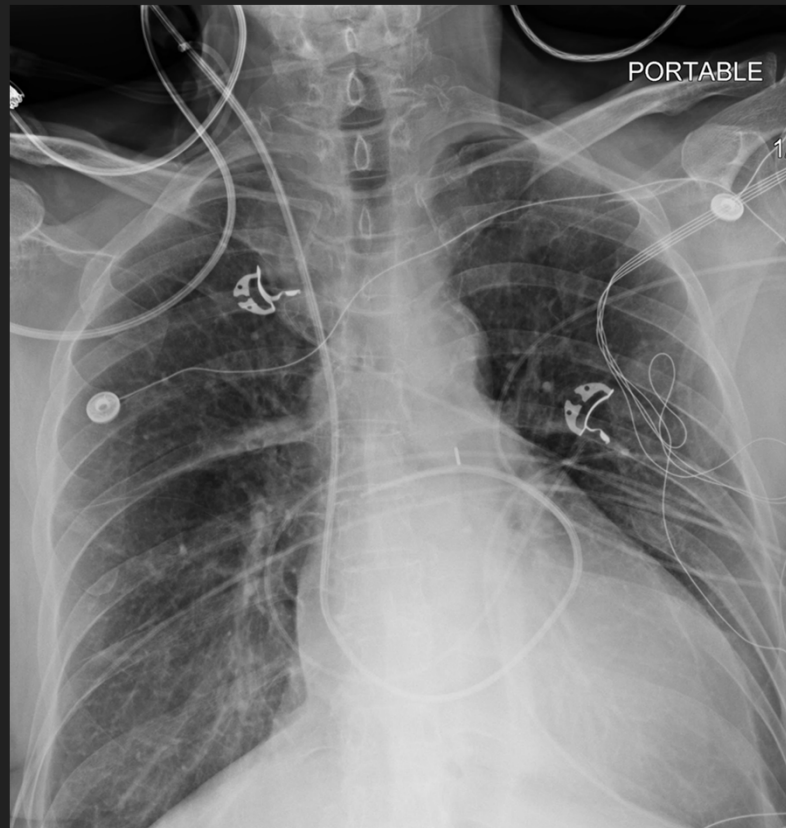- Proper Placement

- Inserted via a large vein (i.e. internal jugular or subclavian vein or common femoral vein) to terminate in proximal right or left pulmonary artery ~ 2cm from the hilum

- Complications

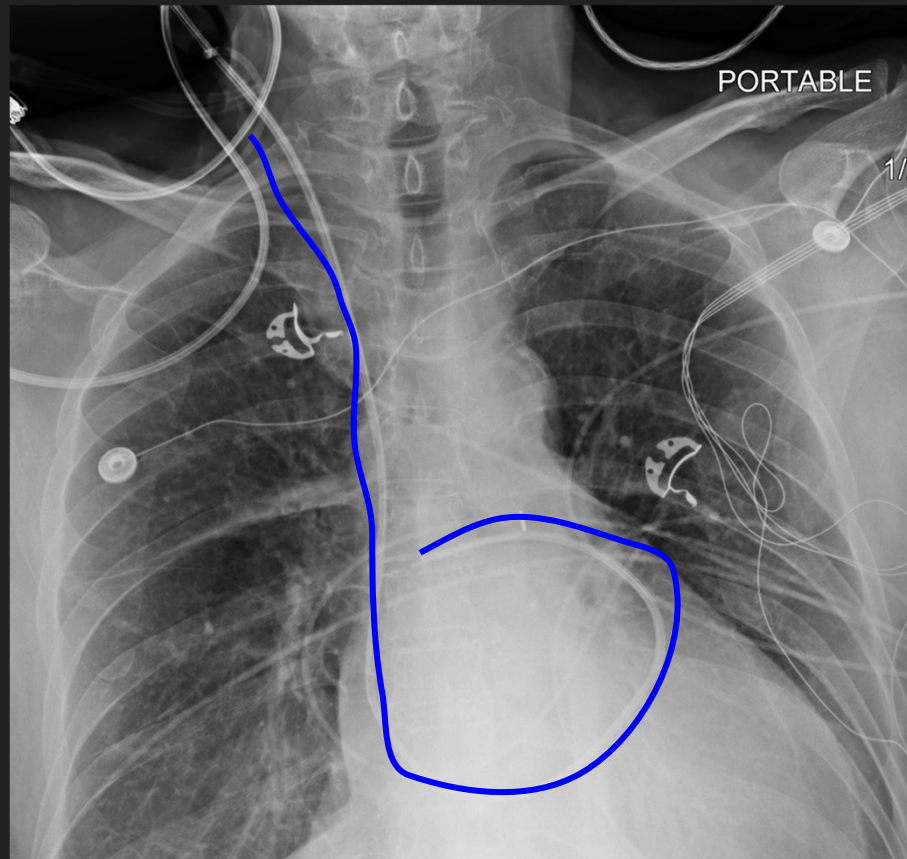
- Misplacement in large veins, right heart chambers, pulmonary trunk or peripheral pulmonary arteries
- Venous perforation
- Phlebitis, bleeding, thrombosis
- Right atrial or ventricular wall perforation
- Pulmonary infarction
- Pneumothorax

Swan Ganz Catheter: Proper Placement



Swan Ganz Catheter: Proper Placement

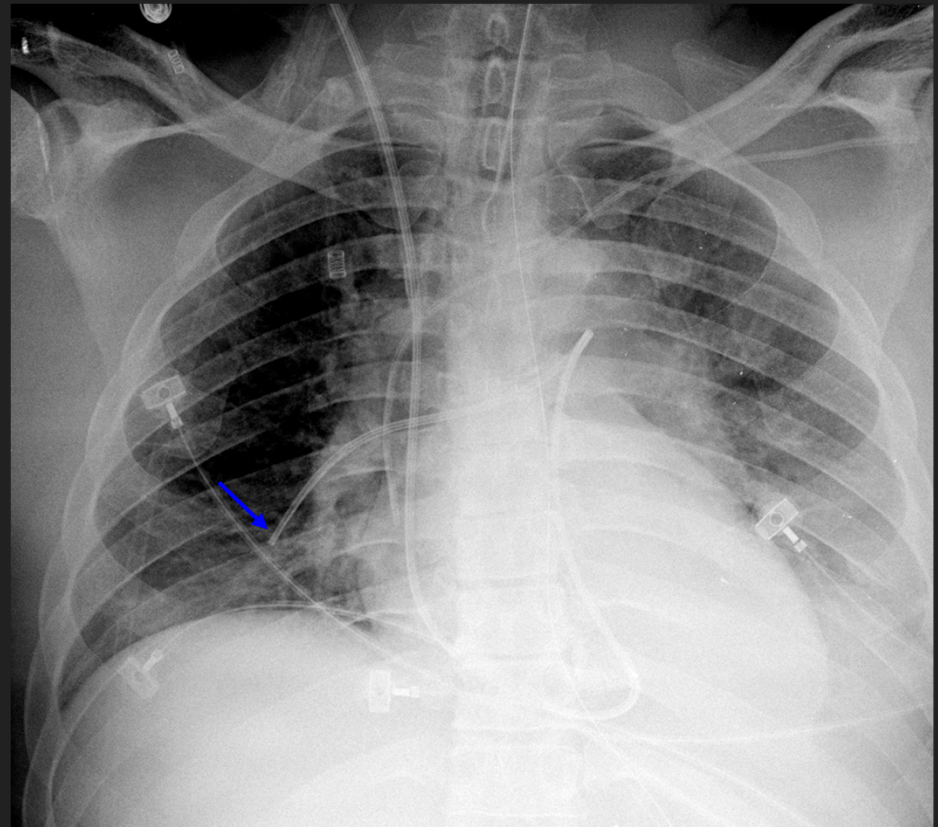
Right IJ
approach
with tip
projecting in
the mid right
pulmonary
artery



Swan Ganz Catheter: Misplaced

SG tip in distal right lower lobe artery.

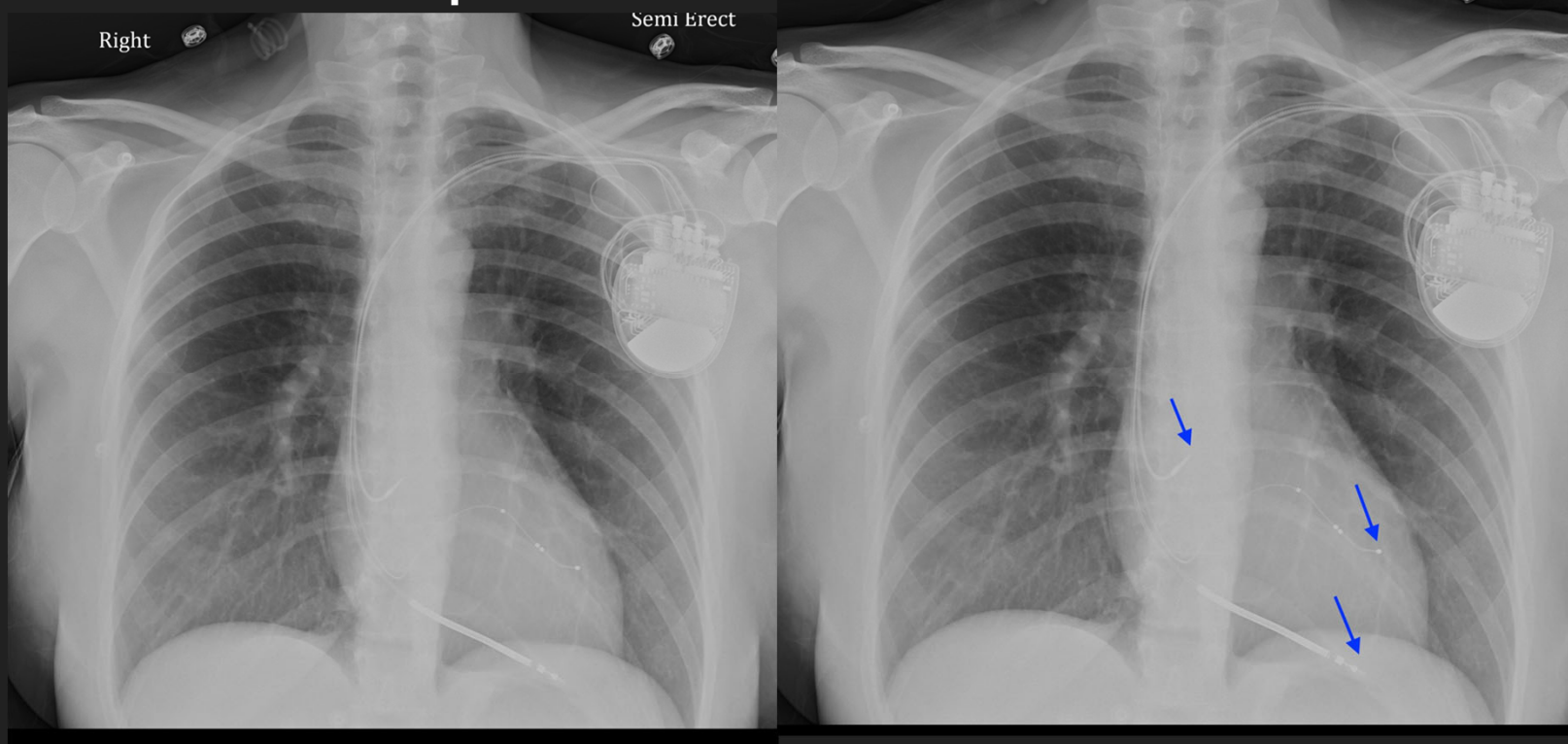
At risk of arterial rupture if the balloon is expanded and at risk of pulmonary infarction if tip enters smaller side branch.



Cardiac Pacemaker/Implantable Cardiac Defibrillator

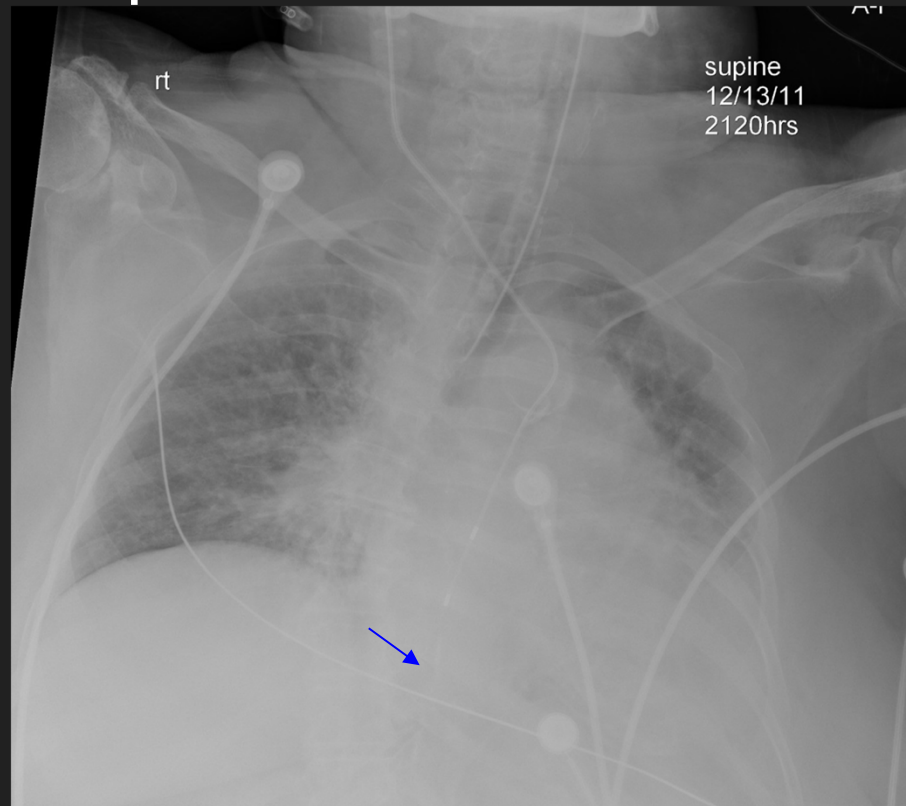
- Purpose
 - Assist in normal electrical conduction of the heart
 - Break ventricular fibrillation
- Proper Placement
 - Pulse generator/defibrillator is positioned in subcutaneous tissues of the anterior chest wall
 - Electrodes are guided via subclavian vein and SVC into right atrial appendage, right ventricle and coronary sinus
- Complications
 - Misplacement in the proximal veins or cardiac chambers
 - Perforation of the heart
 - Lead discontinuity
 - Pneumothorax
 - Pacemaker-mediated tachycardia
 - Infection

Cardiac Pacemaker/Implantable Cardiac Defibrillator: Proper Placement

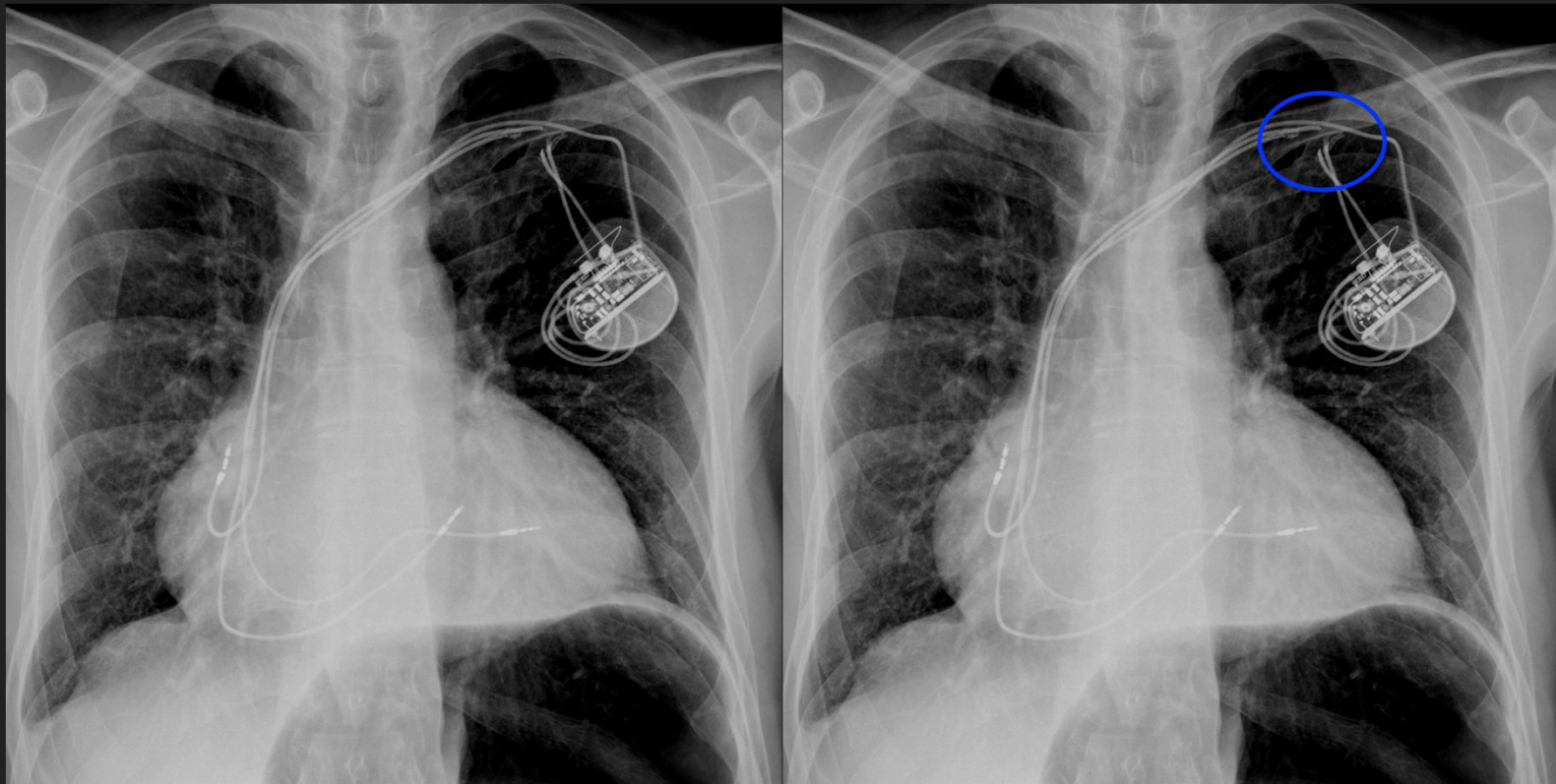


Cardiac Pacemaker/Implantable Cardiac Defibrillator: Misplaced

Right IJ cardiac lead extends into the aorta, terminating in the distal descending thoracic aorta

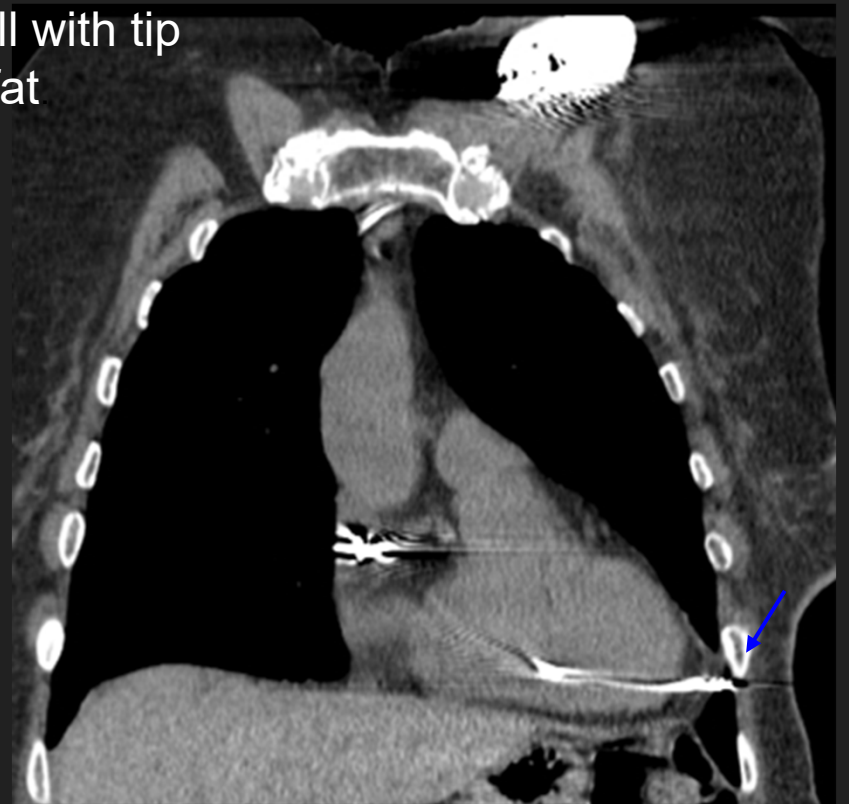
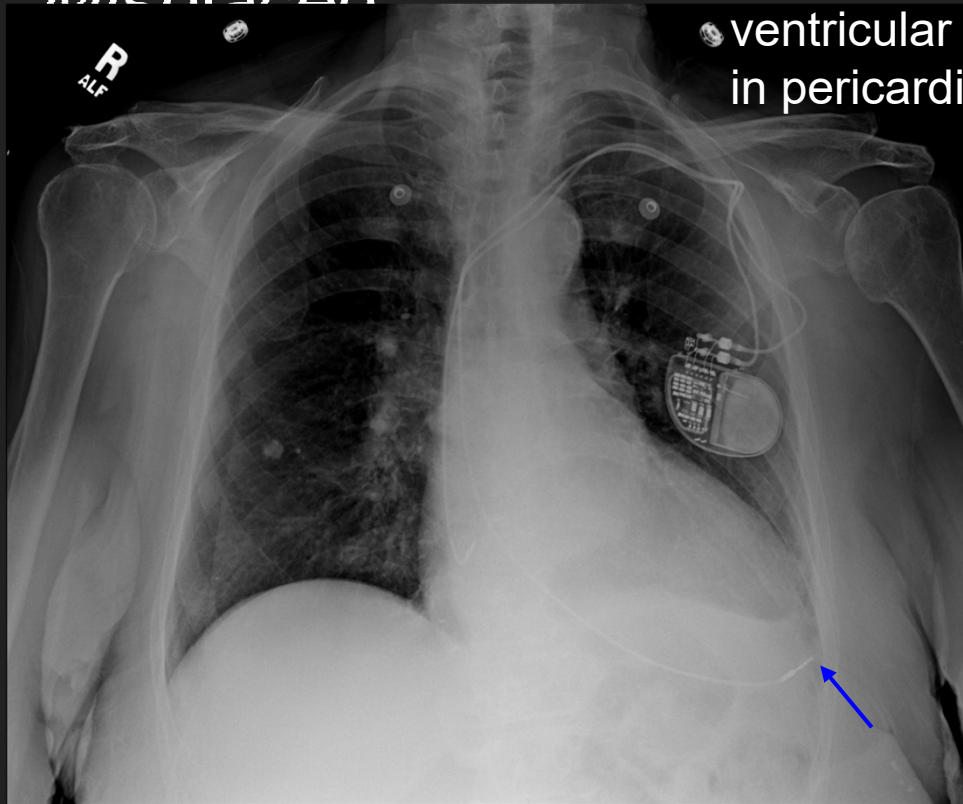


Cardiac Pacemaker/Implantable Cardiac Defibrillator: Fractured Leads



Cardiac Pacemaker/Implantable Cardiac Defibrillator: Misplaced

RV lead though right
ventricular wall with tip
in pericardial fat



The End