

AMSER Case of the Month

November 2021

83-year-old female with hematochezia



Kathryn Evey^{1,2}, David Petrov, MD², Andrew Klobuka, MD²

Lake Erie College of Osteopathic Medicine¹

Department of Vascular and Interventional Radiology, Allegheny Health Network²



Patient Presentation

- Patient is an 83-year-old female with PMHx of HTN, CAD, hypothyroidism, colonic diverticulosis and mechanical aortic valve on Coumadin, who presented to the ED from a nursing home with hematochezia.
- She reported large volume bright-red, clotted blood in her stool accompanied by abdominal pain. Patient denied chest pain, fever, chills, shortness of breath, fatigue, weakness and lightheadedness.
- Patient was scheduled for outpatient EGD and colonoscopy and had held Coumadin for 5 days prior to presentation to ED.
- Patient was hemodynamically stable and in no acute distress.
- Physical exam revealed LLQ tenderness to palpation, and maroon, tarry stool without hemorrhoids or palpable masses on DRE. Vitals were as follows: BP 174/68, pulse 80, RR 31, SpO₂ 93%.

Pertinent Labs

- CBC ordered upon patient presentation to the ED.
- Patient's baseline hemoglobin is 13.3 g/dL. Down trending hemoglobin noted on admission likely attributable to the GI bleeding.

CBC	
WBC	5.69
RBC	4.47
Hemoglobin	12.6
Hematocrit	39.5
MCV	88.4
MCH	28.2
MCHC	31.9
RDW	15.2
Platelet Count	224
MPV	10.0

What Imaging Should We Order?

CT Angiogram Abdomen & Pelvis

ACR Appropriateness Criteria

American College of Radiology
ACR Appropriateness Criteria®
Radiologic Management of Lower Gastrointestinal Tract Bleeding

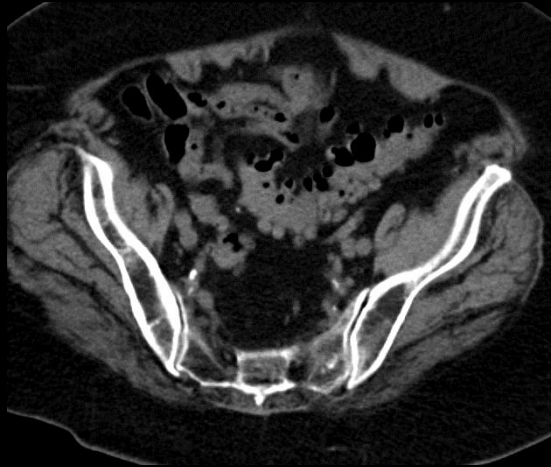Variant 1:

Lower gastrointestinal tract bleeding. Active bleeding clinically observed as hematochezia or melena in a hemodynamically stable patient. Next step.

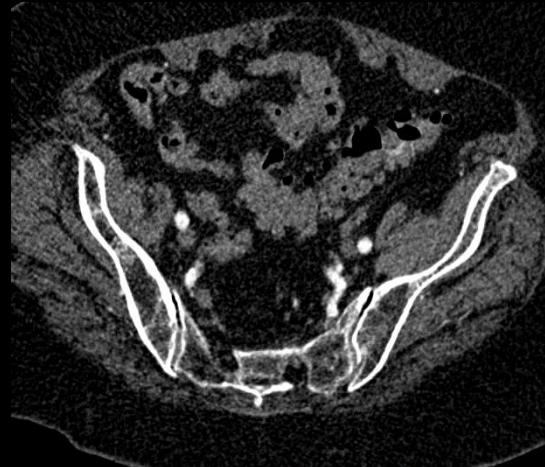
Procedure	Appropriateness Category
CTA abdomen and pelvis without and with IV contrast	Usually Appropriate
Diagnostic/therapeutic colonoscopy	Usually Appropriate
RBC scan abdomen and pelvis	Usually Appropriate
Transcatheter arteriography/embolization	May Be Appropriate
MRA abdomen and pelvis without and with IV contrast	Usually Not Appropriate
Surgery	Usually Not Appropriate

This imaging modality was ordered by the ER physician

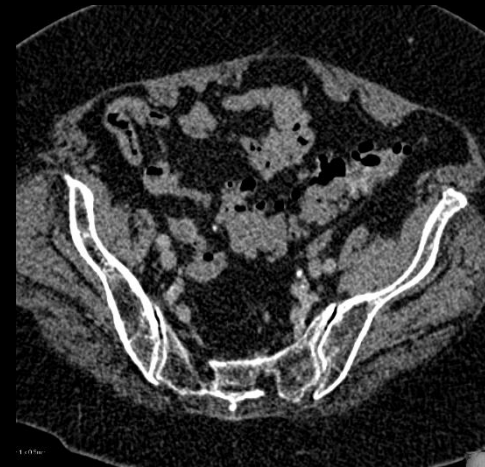
Findings (unlabeled)



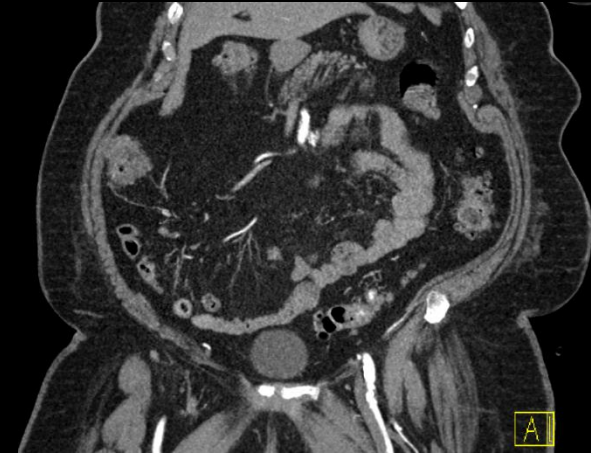Non contrast



Arterial Phase

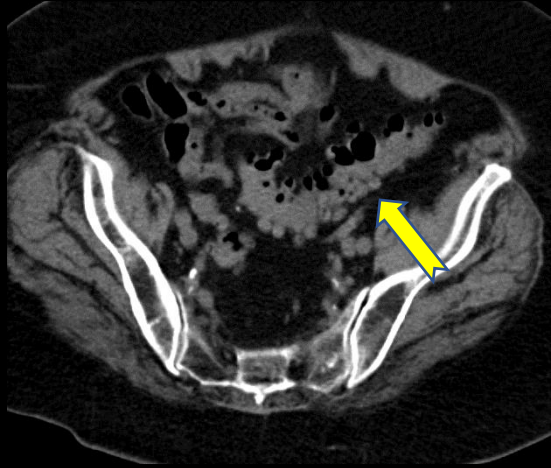


Venous Phase

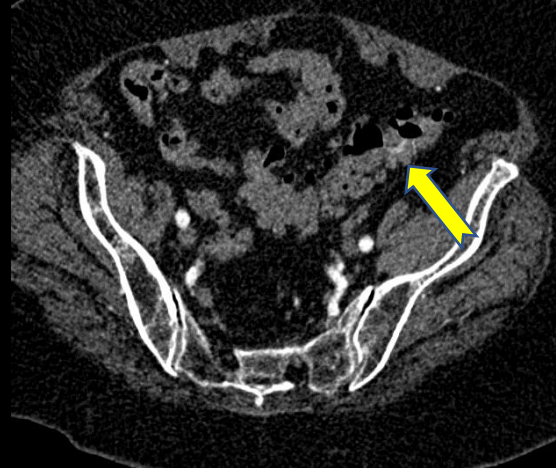


Coronal - Arterial Phase

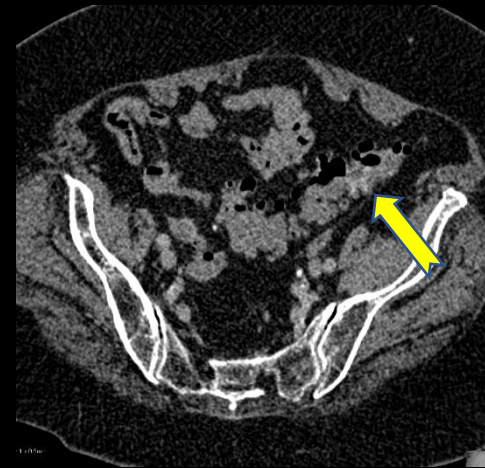
Findings: (labeled)



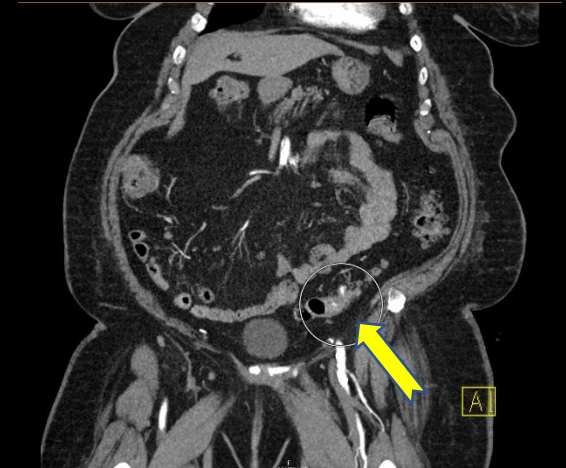
Non-contrast



Arterial Phase



Venous Phase



Coronal - Arterial Phase

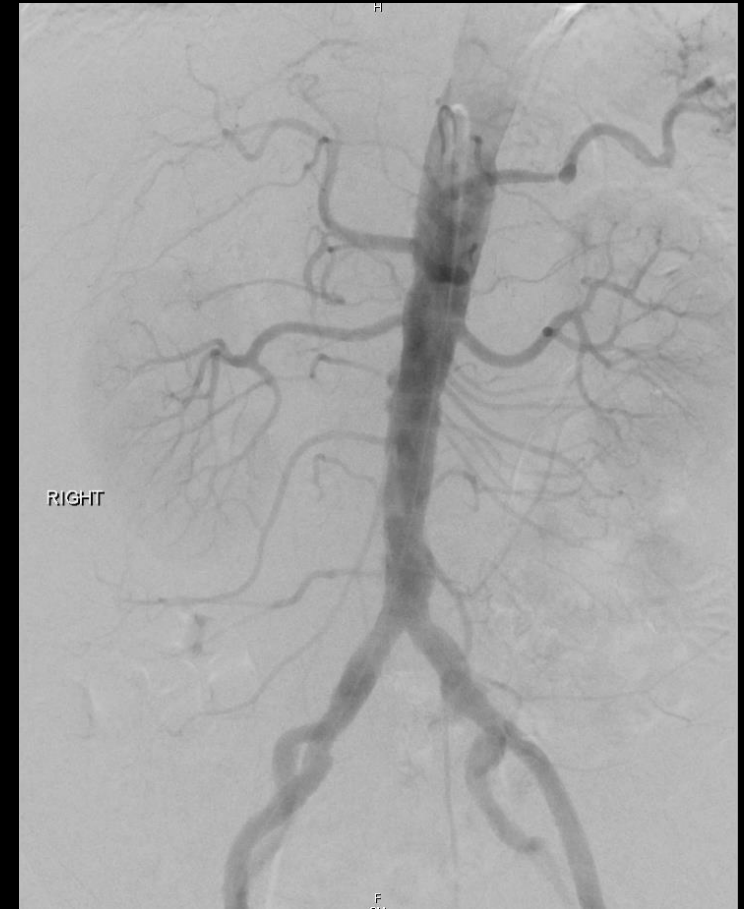Bleeding not visible on non-contrast study in absence of intravenous contrast. Focal intraluminal contrast extravasation is identified within a diverticulum during arterial phase imaging which pools during venous phase imaging, consistent with active arterial bleeding.

Final Dx:

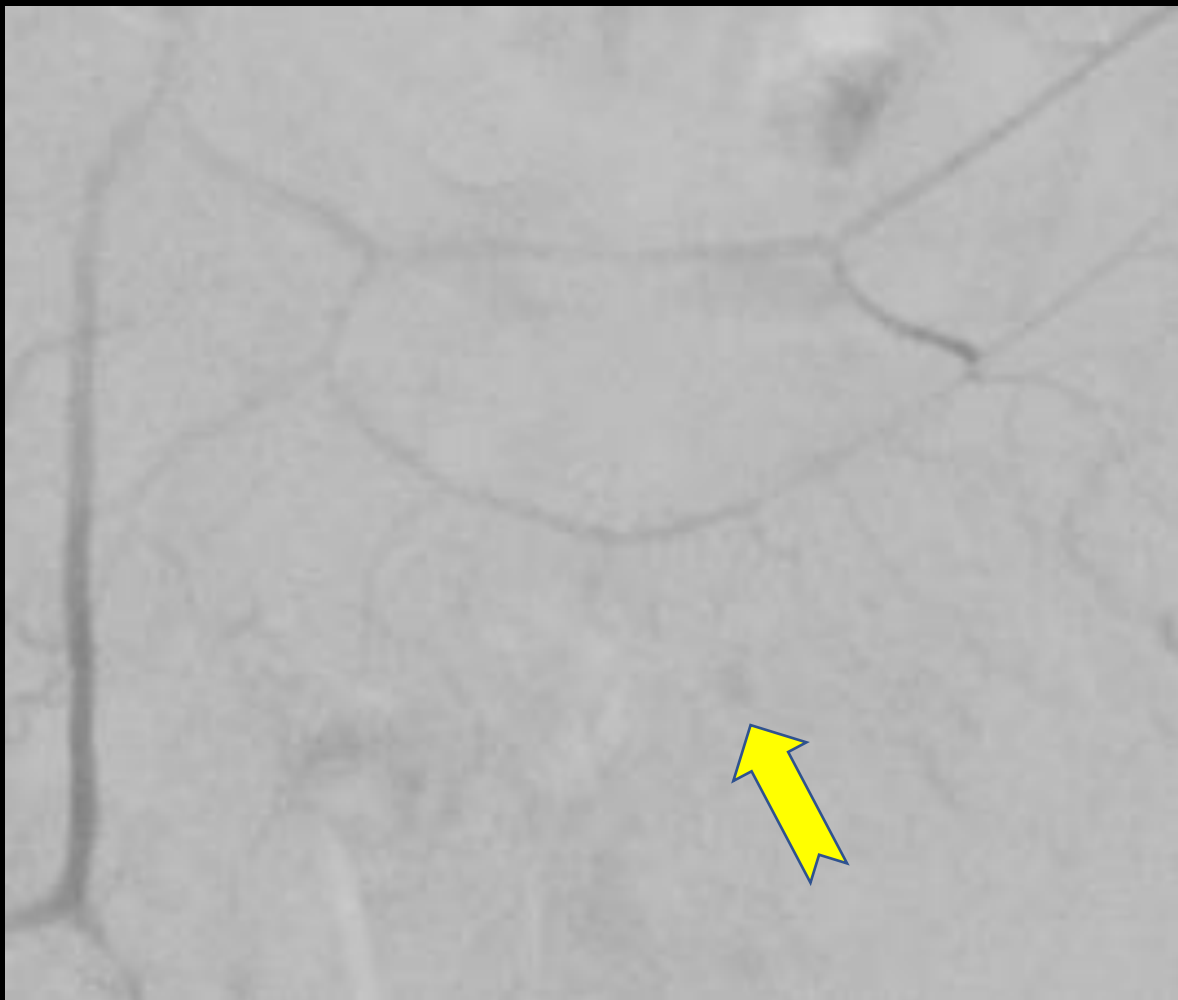
Lower GI Bleed Involving Sigmoid Diverticula

Case Discussion

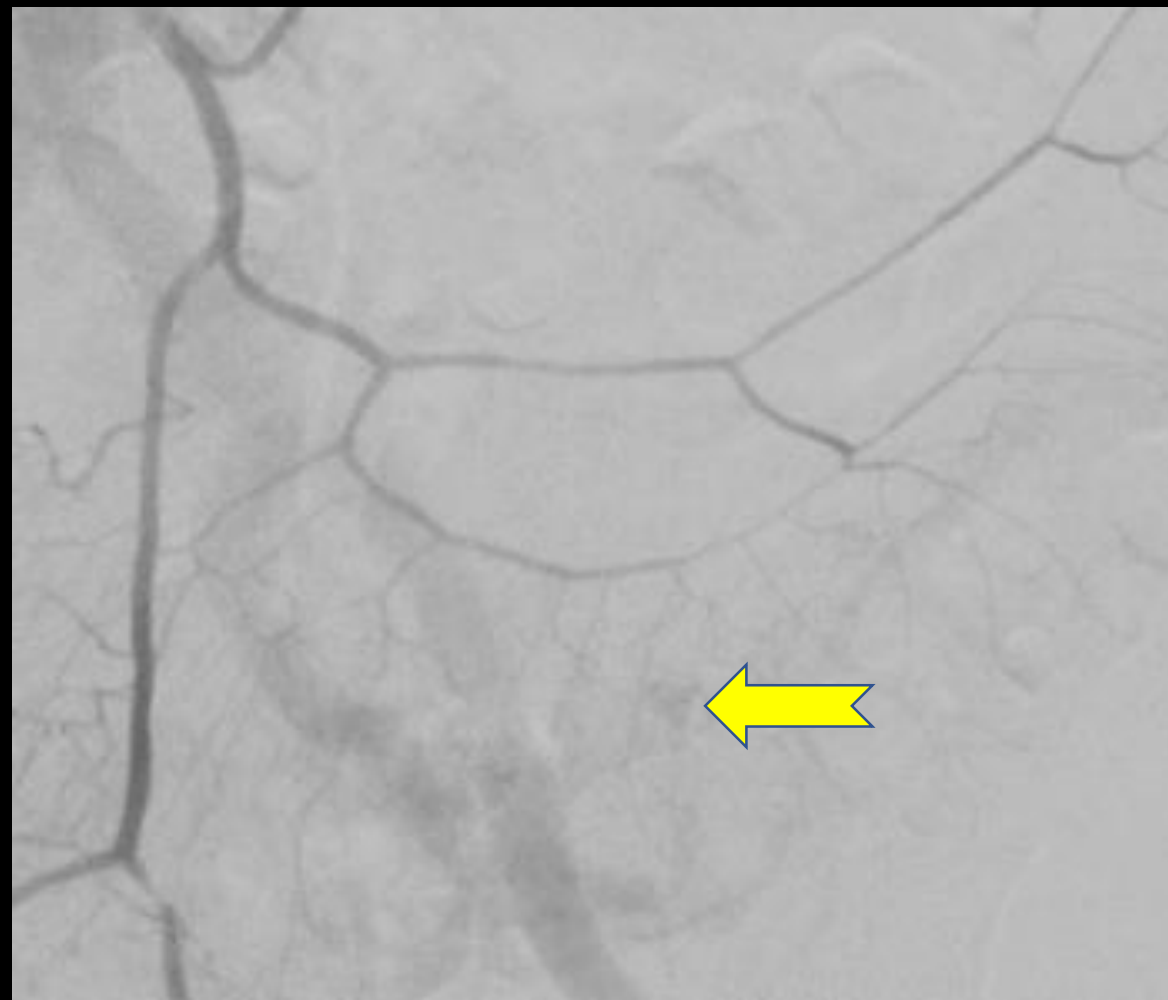- Interventional Radiology was consulted for a visceral angiogram with selective angiography and embolization of the bleeding vessel.
- Access was gained via the right femoral artery using a micropuncture system.
- Using a 4 French Omniflush catheter, an abdominal aortogram was performed, demonstrating normal patency and branching pattern of the visceral arteries.



Case Discussion (cont.)



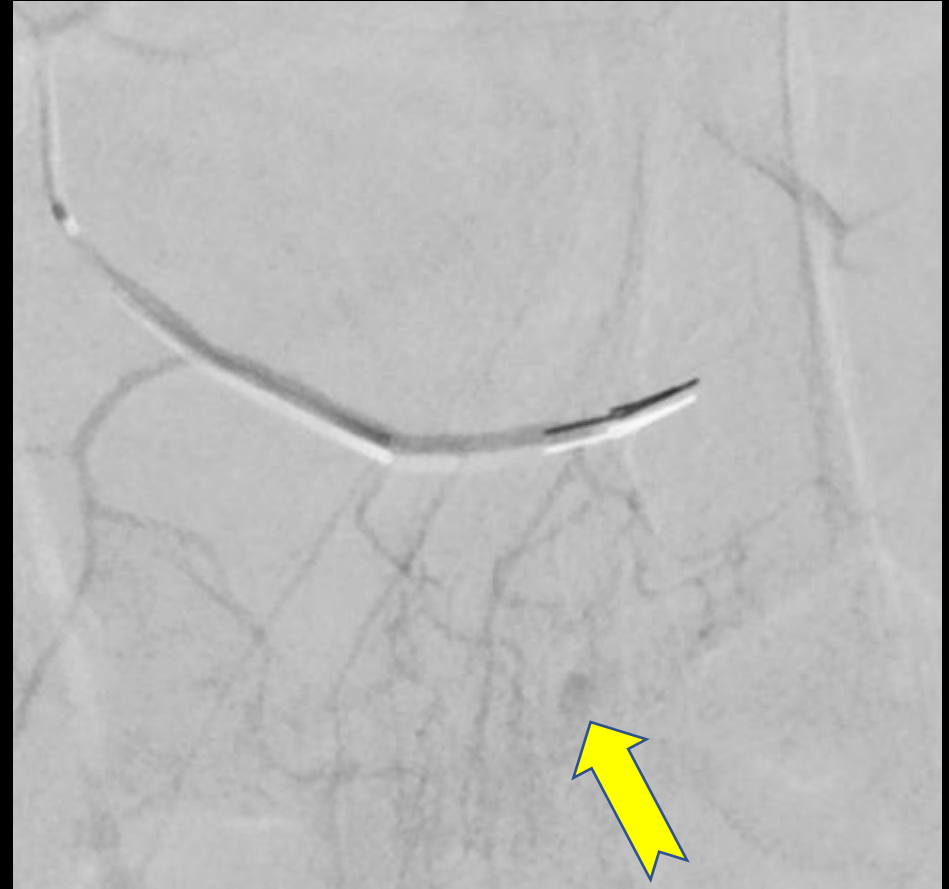Arterial Extravasation



Extravasation into Diverticula

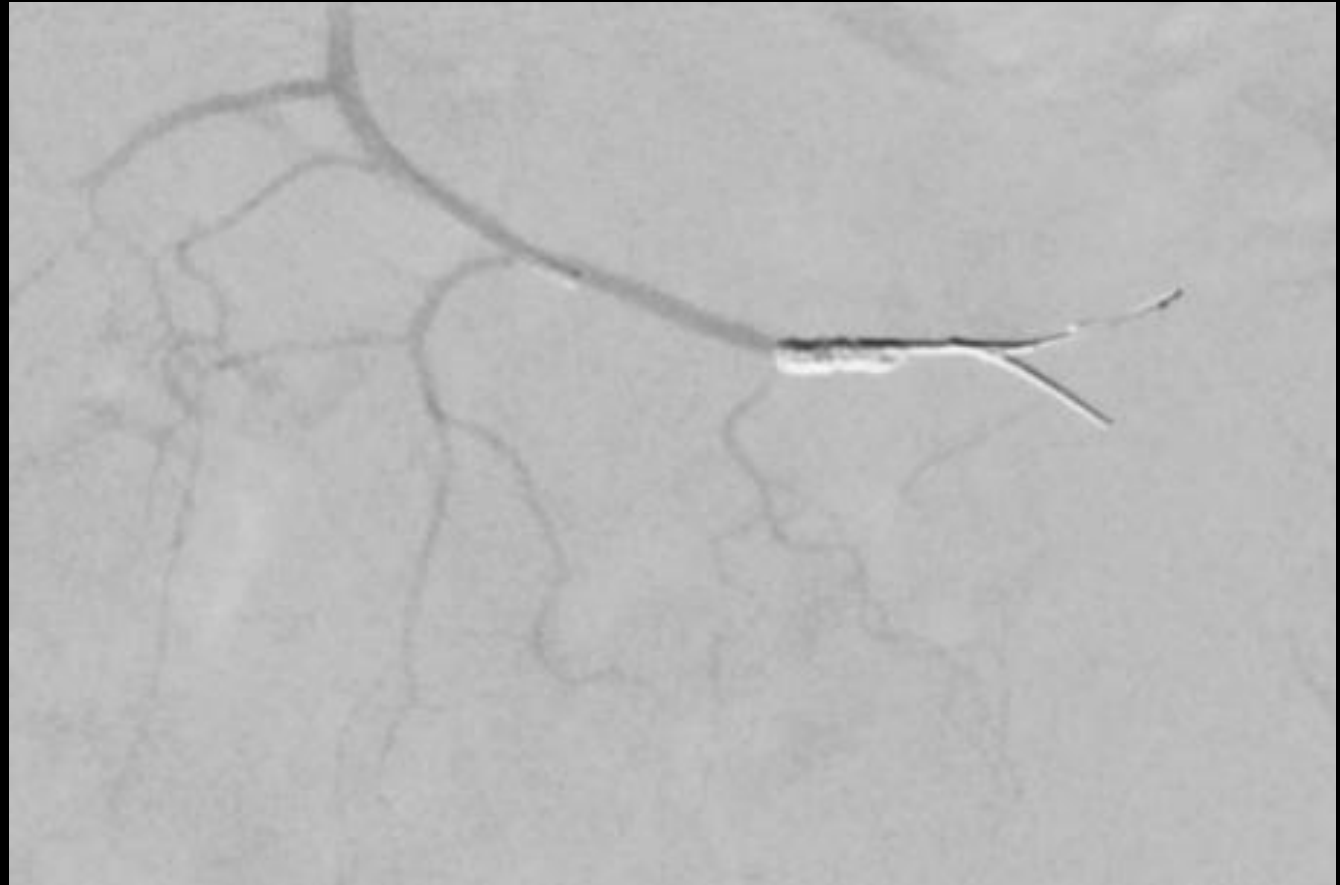
Case Discussion (cont.)

- Selective catheterization of the inferior mesenteric artery and subsequent angiography demonstrated contrast extravasation originating in sigmoid branches of the left colic artery.
- After identifying this focal extravasation, embolization of the area was performed using Hilal and Concerto coils across the feeding branches.



Case Discussion (cont.)

- Post-embolization angiogram demonstrated resolution of contrast extravasation in the area of interest.
- Patient tolerated the procedure well. Her hemoglobin remained stable after the embolization and she did not have recurrence of the GI bleed.
- The patient had stable vital signs for the duration of her hospital stay and was discharged 5 days post-procedure with plans for a follow up colonoscopy.



References:

1. d'Othée, B.J., Surapaneni, P., Rabkin, D. *et al.* Microcoil Embolization for Acute Lower Gastrointestinal Bleeding. *Cardiovasc Intervent Radiol* **29**, 49–58 (2006). <https://doi.org/10.1007/s00270-004-0301-4>
2. Ethan J. Speir, R. Mitchell Ermentrout, Jonathan G. Martin. Management of Acute Lower Gastrointestinal Bleeding. *Techniques in Vascular and Interventional Radiology* **20**, Issue 4 (2017). Pages 258-262. ISSN 1089-2516. <https://doi.org/10.1053/j.tvir.2017.10.005>.
3. Mauro, M. A., Murphy, K., Thomson, K. R., Venbrux, A. C., & Morgan, R. A. (2021). Management of Lower Gastrointestinal Hemorrhage. In *Image-guided interventions* (pp. 232–238). essay, Elsevier.
4. William T. Kuo, David E. Lee, Wael E.A. Saad, Nikhil Patel, Lawrence G. Sahler, David L. Waldman. Superselective Microcoil Embolization for the Treatment of Lower Gastrointestinal Hemorrhage. *Journal of Vascular and Interventional Radiology* **14**, Issue 12 (2003). Pages 1503-1509. ISSN 1051-0443. <https://doi.org/10.1097/01.RVI.0000099780.23569.E6>.