

AMSER Case of the Month

October 2021

74-year-old presents to the ED with fatigue and myalgias



Brenda Castlemain, MS4
Drexel University, College of Medicine
Dr. Matthew Hartman MD
Allegheny Health Network



Patient Presentation

- The patient is a 74-year-old female with atrial fibrillation, currently on Pradaxa, and type 2 diabetes presenting with fatigue, myalgias and urinary frequency for one week. No aggravating or relieving factors reported.
- Denies fever, chills, nausea, vomiting, chest pain, shortness of breath, coughing, abdominal pain, diarrhea, dysuria, hematuria, black/red stools/vomit

Pertinent Labs

- Comprehensive metabolic panel significant for glucose of 170 mg/dL
- Hemoglobin A1c: 6.8% in March 2021
- Urinalysis
 - Nitrite +
 - Blood 3+
 - Urobilinogen 2.0
 - RBC 10-25
 - Bacteria- moderate
 - Mucus- rare
- Microbiology- >100,000 CFU/ml *Escherichia coli*

What Imaging Should We Order?

CT abdomen pelvis w/ contrast

Select the applicable ACR Appropriateness Criteria

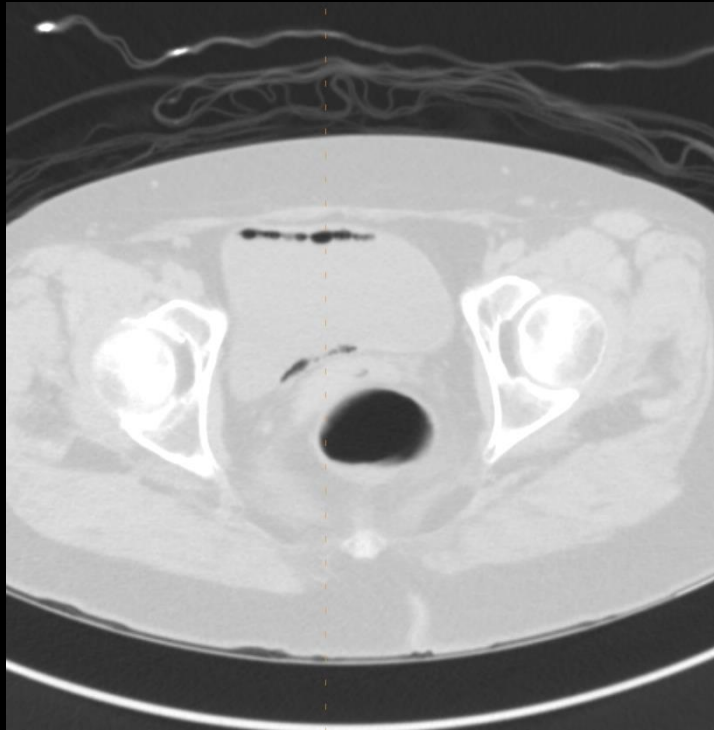Variant 2:

Acute pyelonephritis. Complicated patient (eg, diabetes or immunocompromised or history of stones or prior renal surgery or not responding to therapy). Initial imaging.

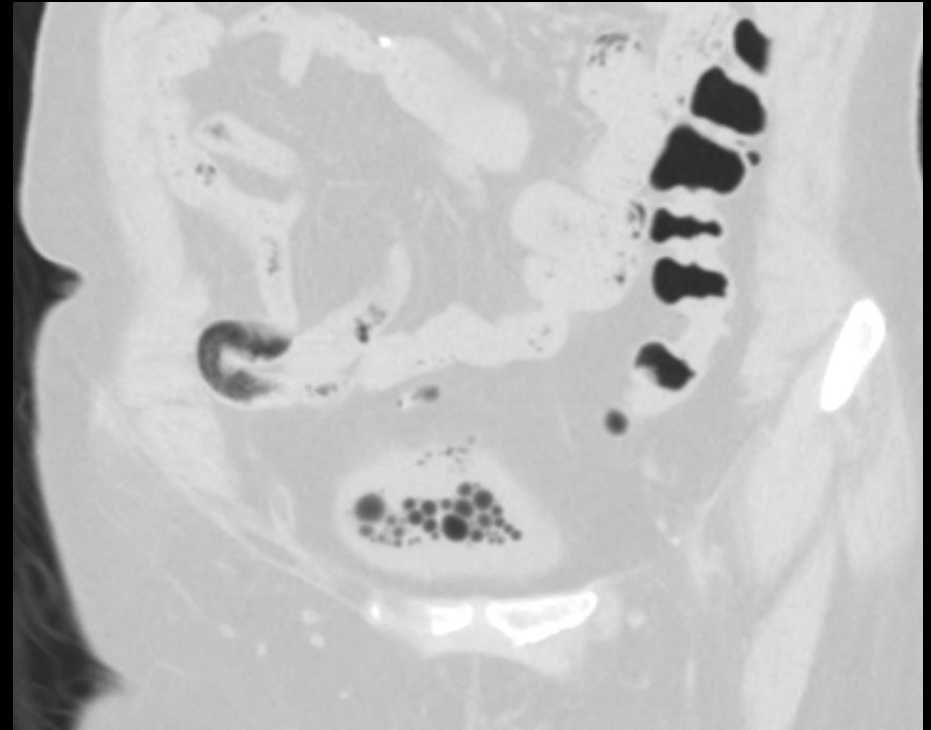
Procedure	Appropriateness Category	Relative Radiation Level
CT abdomen and pelvis with IV contrast	Usually Appropriate	☼ ☼ ☼
CT abdomen and pelvis without and with IV contrast	Usually Appropriate	☼ ☼ ☼ ☼
MRI abdomen without and with IV contrast	May Be Appropriate	0
CT abdomen and pelvis without IV contrast	May Be Appropriate	☼ ☼ ☼
MRI abdomen and pelvis without and with IV contrast	May Be Appropriate (Disagreement)	0
MRI abdomen and pelvis without IV contrast	May Be Appropriate	0
MRI abdomen without IV contrast	May Be Appropriate	0
US color Doppler kidneys and bladder retroperitoneal	May Be Appropriate	0
Tc-99m DMSA scan kidney	May Be Appropriate	☼ ☼ ☼
Fluoroscopy voiding cystourethrography	Usually Not Appropriate	☼ ☼
Radiography abdomen and pelvis (KUB)	Usually Not Appropriate	☼ ☼
Fluoroscopy antegrade pyelography	Usually Not Appropriate	☼ ☼ ☼
Radiography intravenous urography	Usually Not Appropriate	☼ ☼ ☼

This imaging modality was ordered by the ER physician

Findings: unlabeled

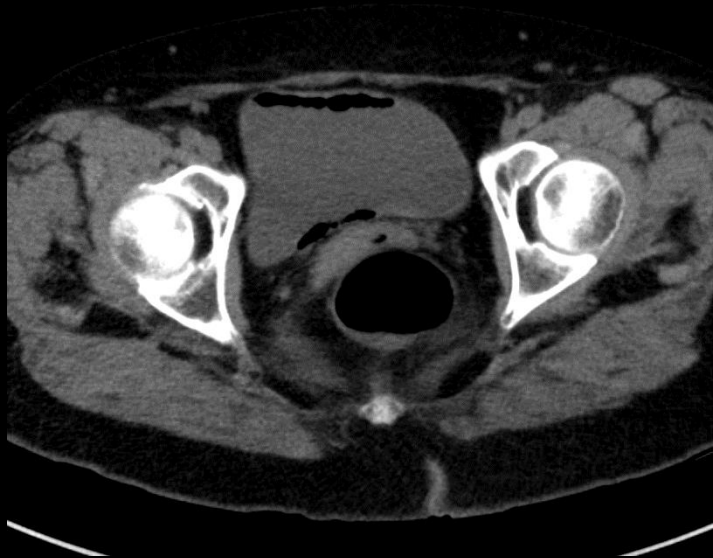


Lung window axial

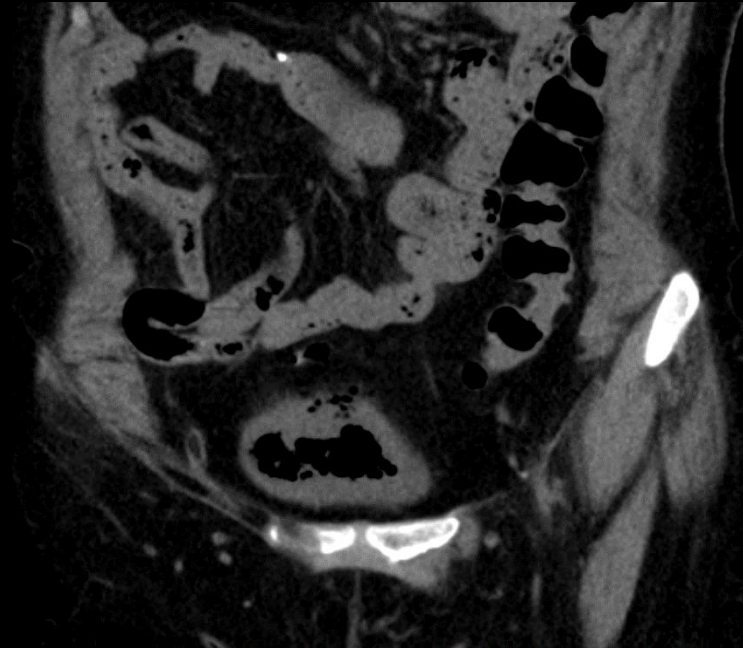


Lung window sagittal

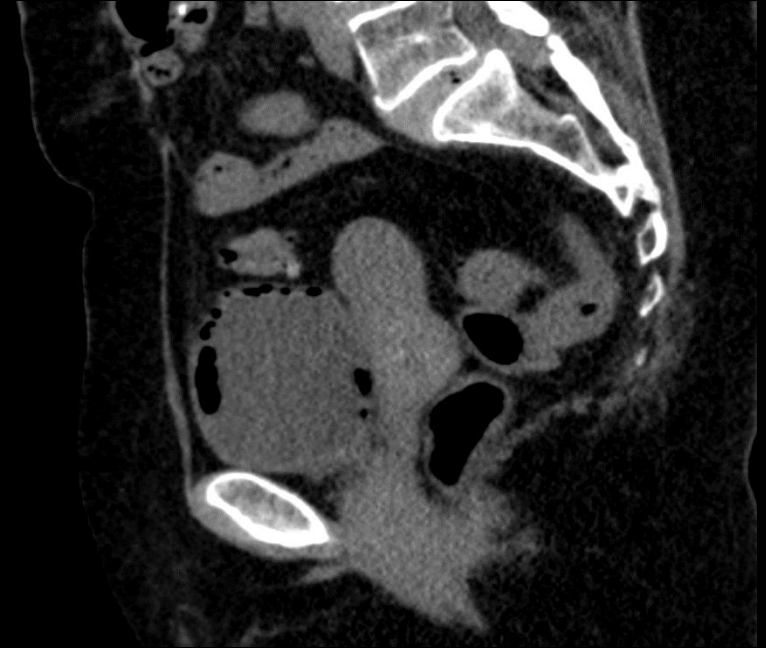Findings: unlabeled



Soft tissue window axial



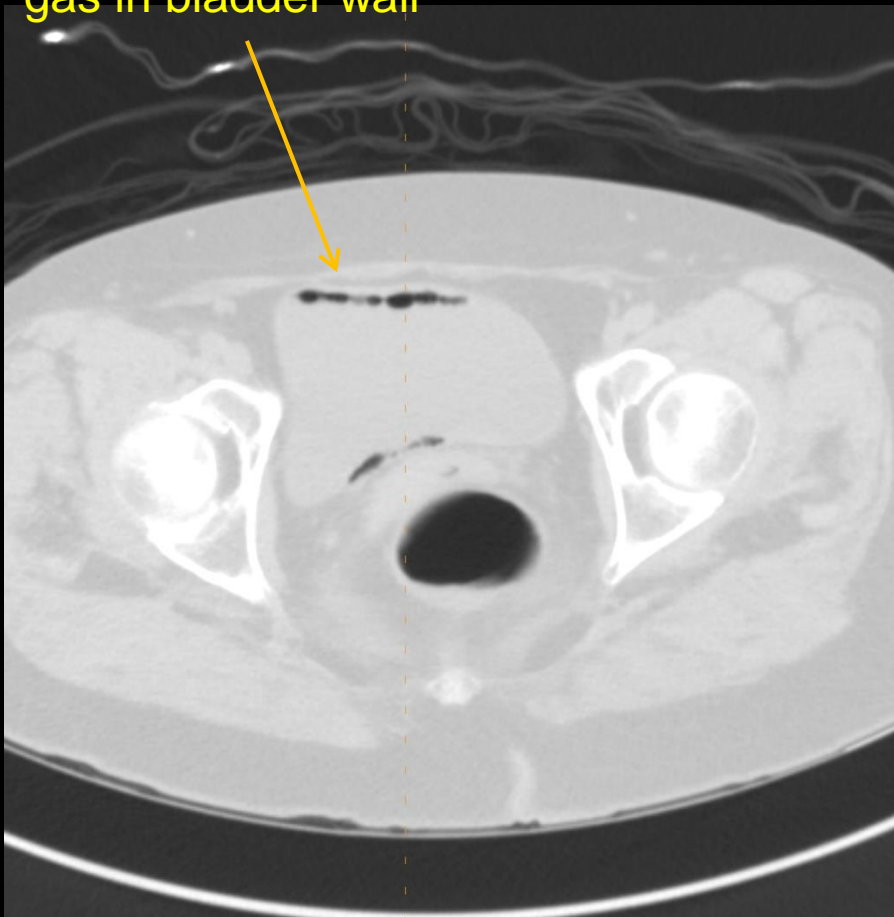
Soft tissue window coronal



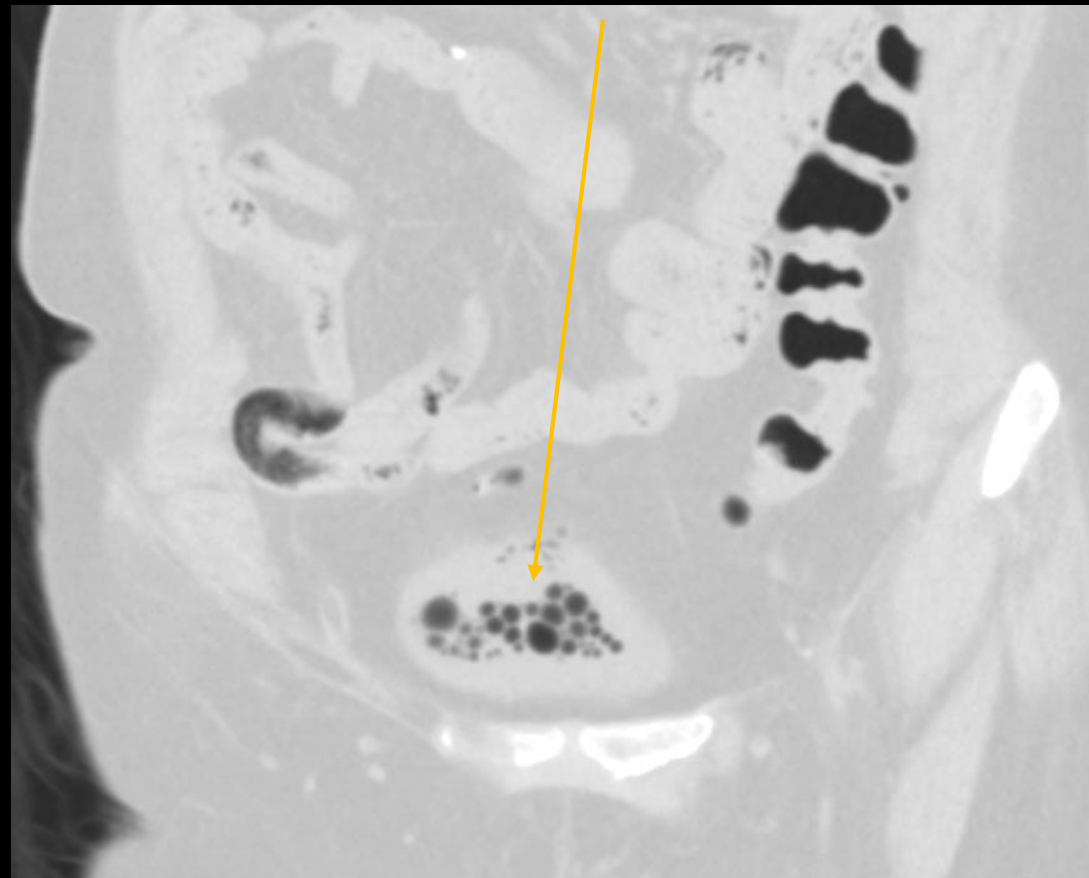
Soft tissue window sagittal

Findings: (labeled)

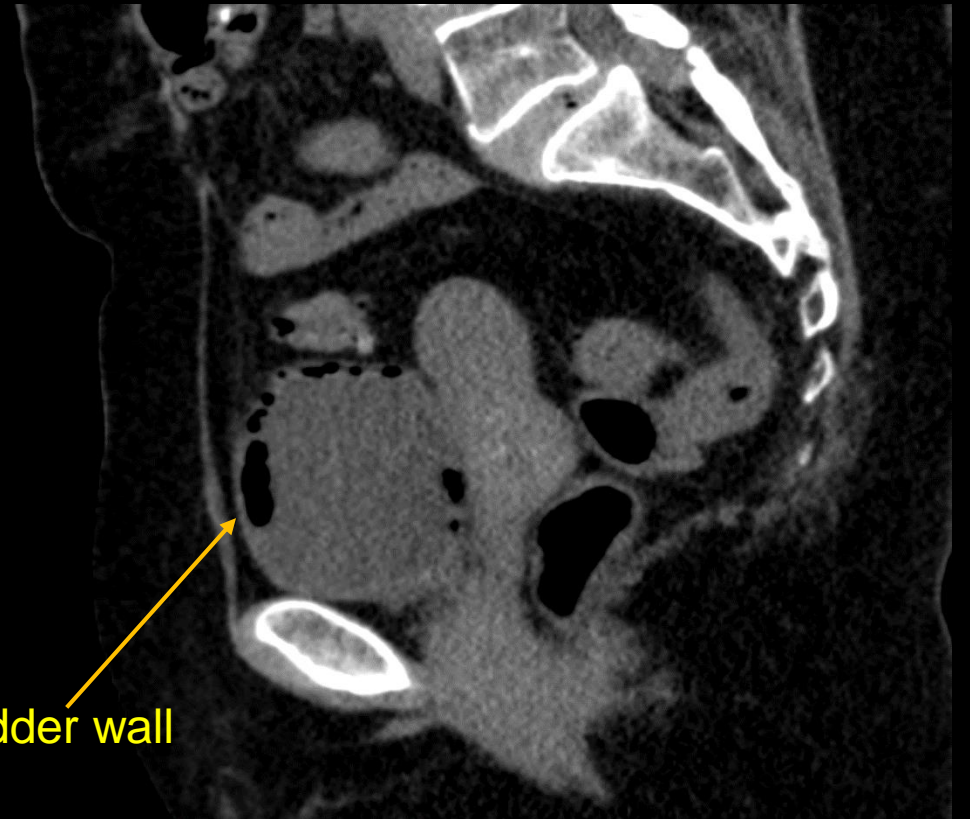
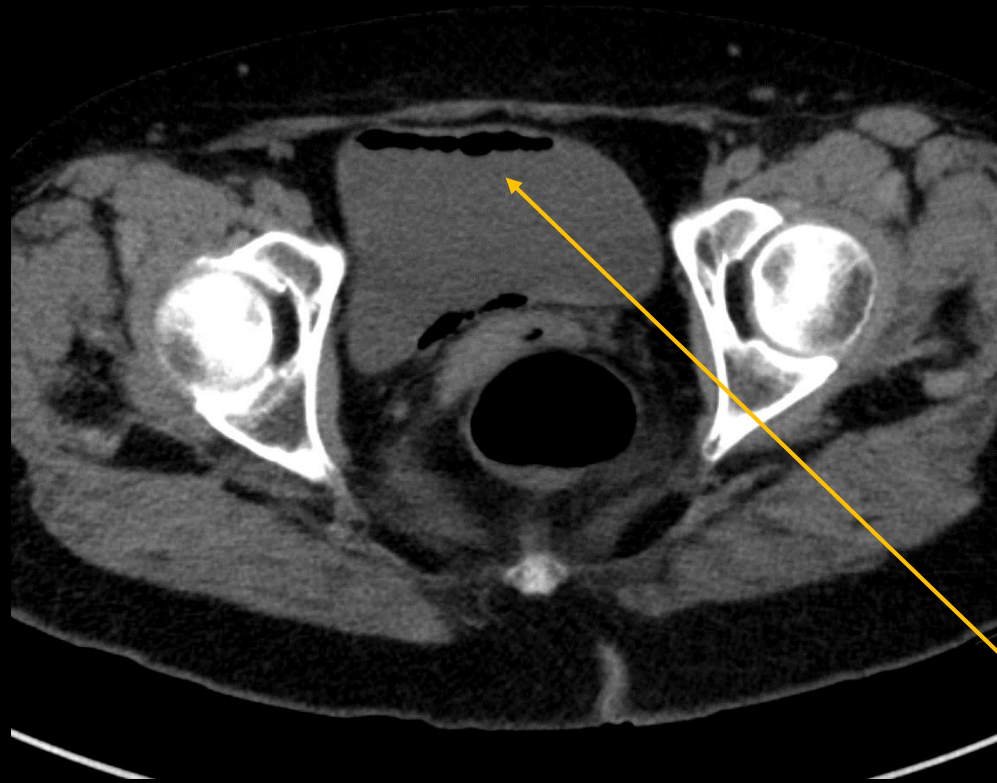
gas in bladder wall



Gas in bladder lumen



Findings- labeled

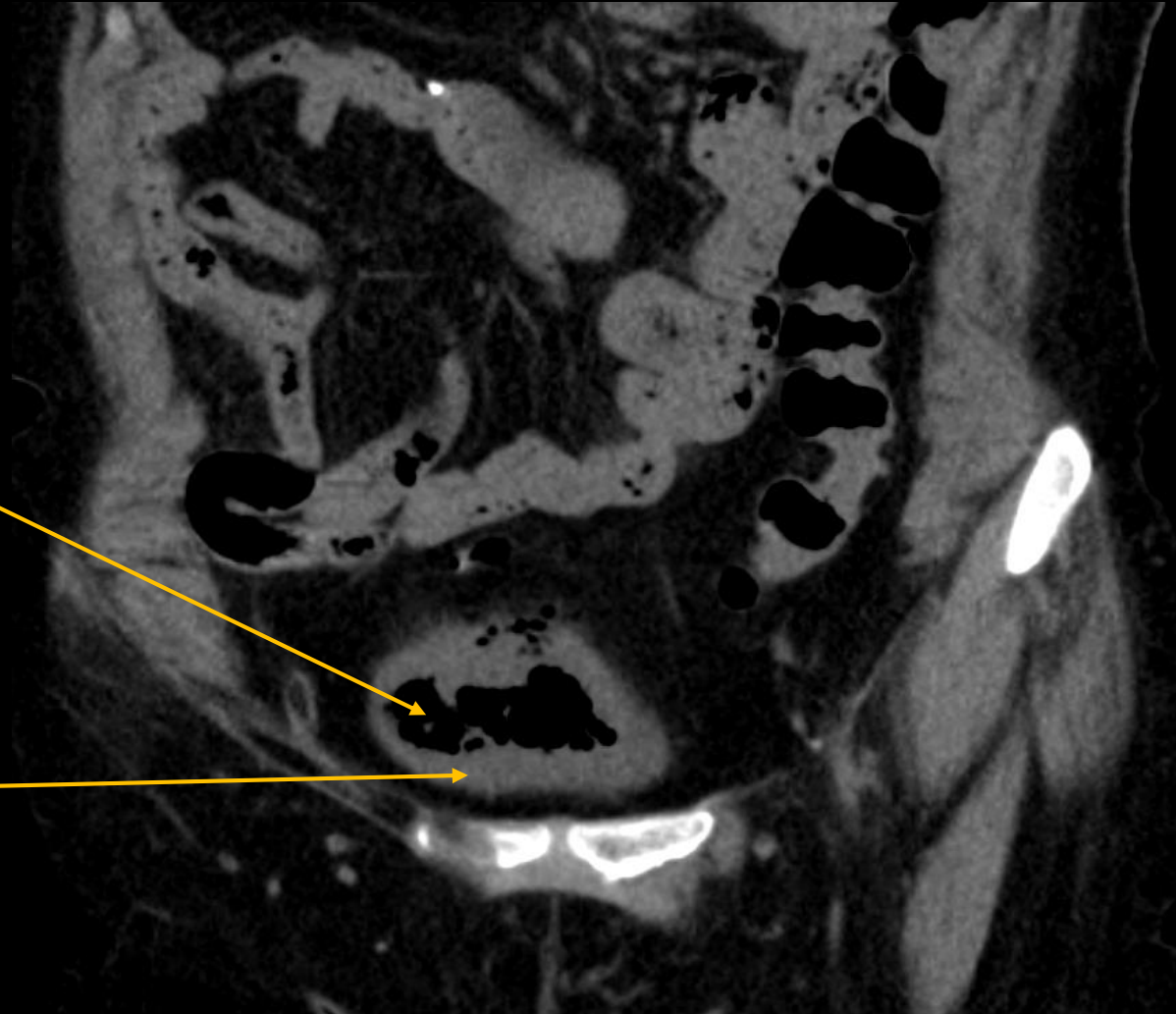


gas in bladder wall

Findings: (labeled)

Decreased bladder capacity

Bladder wall thickening



Differential Diagnoses

1. Emphysematous cystitis
2. Vesicocolic fistula
3. Vesicovaginal fistula
4. Traumatic

Final Dx:
Emphysematous cystitis

Case Discussion

- Emphysematous UTIs can be of the upper or lower urinary tracts and are associated with gas formation
- Diabetes mellitus is a risk factor- elevated tissue glucose levels may provide favorable conditions for gas-forming organisms
- Common microorganisms include *Escherichia coli* or *Klebsiella pneumoniae*
- Less commonly, *Proteus*, *Enterococcus*, *Pseudomonas*, *Clostridium* and rarely *Candida* can cause these infections

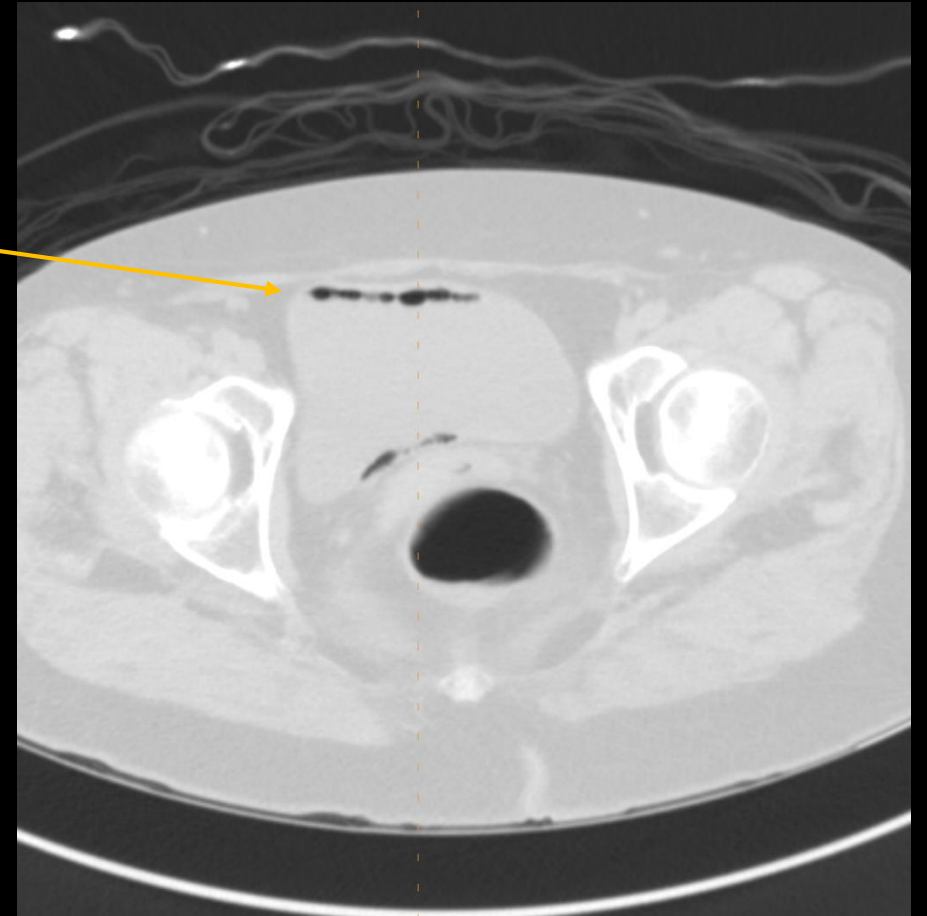
Case Discussion cont'd

Other conditions that can cause gas in the bladder

- Iatrogenesis- catheter insertion or cystoscopy
- Trauma
- Bladder-bowel fistula

Case Discussion cont'd

- Cobblestoned or “beaded necklace” appearance on abdominal X-ray and CT reflects irregular thickening of the mucosa due to submucosal blebs
- CT helps detect presence of upper UTI and/or other causes of pelvic air



Case Discussion cont'd

Treatment

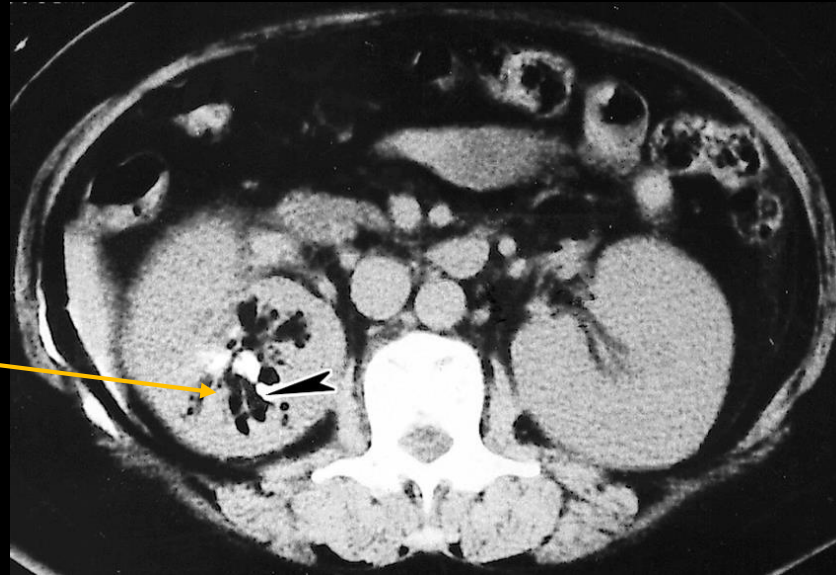
Emphysematous cystitis- parenteral antibiotics

Emphysematous pyelonephritis- additional management with percutaneous drainage (PCD) or surgery may be necessary, depending on severity

- Emphysematous pyelitis- gas restricted to lumen of collecting system
- Emphysematous pyelonephritis- gas in renal collecting system **and /or** the renal parenchyma

An example of emphysematous pyelonephritis

Gas within the renal parenchyma



References:

Amano M, Shimizu T. Emphysematous cystitis: a review of the literature. Intern Med. 2014;53(2):79-82. doi: 10.2169/internalmedicine.53.1121. Epub 2012 Mar 1. PMID: 24429444.

Gay, S. B., & Woodcock, R. J. (2008). *Radiology recall* (2nd ed., Vol. 1). Wolters Kluwer Health.

Image:

Huang, Jeng-Jong & Tseng, Chin-Chung. (2000). Emphysematous Pyelonephritis: Clinicoradiological Classification, Management, Prognosis, and Pathogenesis. Archives of internal medicine. 160. 797-805. 10.1001/archinte.160.6.797.