

AMSER Case of the Month

September 2021

50-year-old male with sudden right flank pain

Nihal Thapa, MS4 - Washington State University
Elson S. Floyd College of Medicine



Elson S. Floyd
College of Medicine

Dr. Julie Kaczmark, MD - Inland Imaging

Dr. Douglas Murrey, MD – Inland Imaging


Inland Imaging®

AMSER

Patient Presentation

- **HPI:** Patient presented to ER with sudden onset, constant, severe right flank pain. Denies any changes in urination, bowel movements, nausea, or vomiting.
- **PMHx:** HTN, OSA, Hx of Papillary Thyroid Cancer
- **SHx:** Total thyroidectomy, Gastric bypass
- **ROS:** No fever, jaundice, or hematuria
- **Vitals:** BP 150/90, HR 65, RR 14, SpO2 99% RA, 97.5°F
- **Physical exam:** Pale, moderate distress. Cardiovascular and lung exams normal. Diffuse abdominal tenderness, most pronounced in the right upper quadrant and flank, splinting but nondistended.

Pertinent Labs

CBC

- WBC: 18.38 (H)
- RBC: 3.92 (L)
- Total Hemoglobin: 11.3 (L)
- Hematocrit: 34.1 (L)
- MCV: 87.0
- Platelet Count: 269

LFTs

- Albumin: 3.7
- ALT: 78
- AST: 33
- Bilirubin: 0.9
- Lipase: 142

- BUN: 16
- Cr: 0.97
- Venous Lactate: 2.5 (H)

What Imaging Should We Order?

Applicable ACR Appropriateness Criteria

American College of Radiology ACR Appropriateness Criteria®

Clinical Condition: Acute Onset Flank Pain—Suspicion of Stone Disease (Urolithiasis)

Variant 1: Suspicion of stone disease.

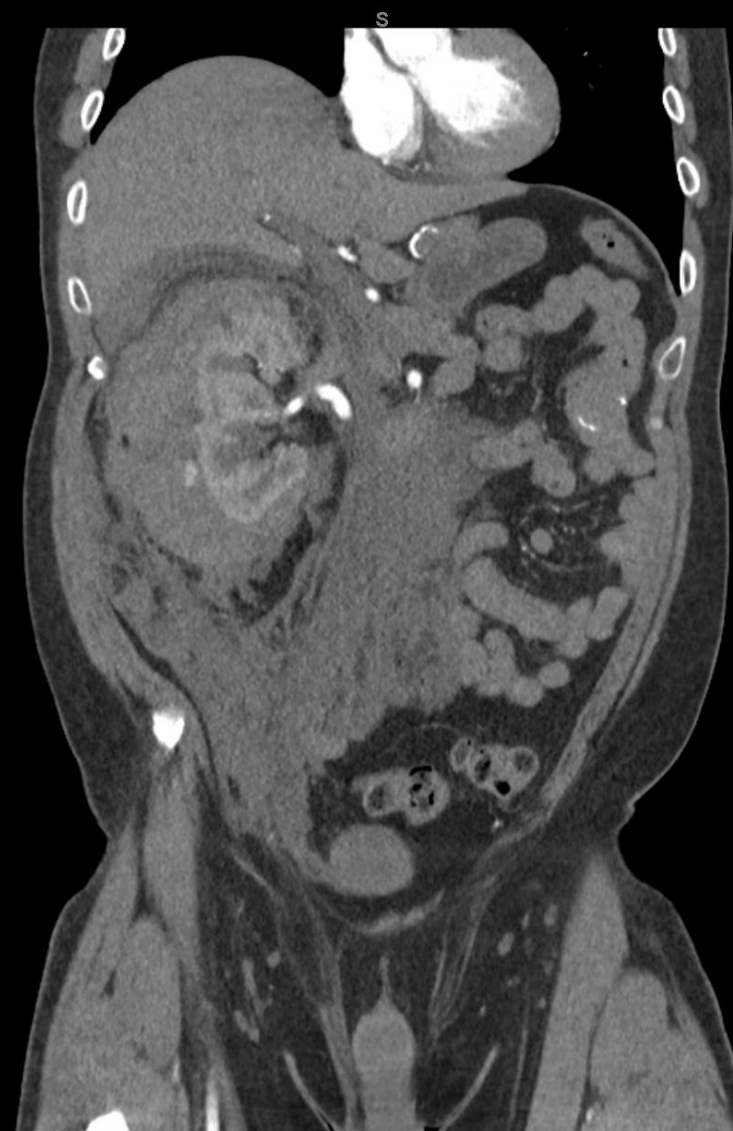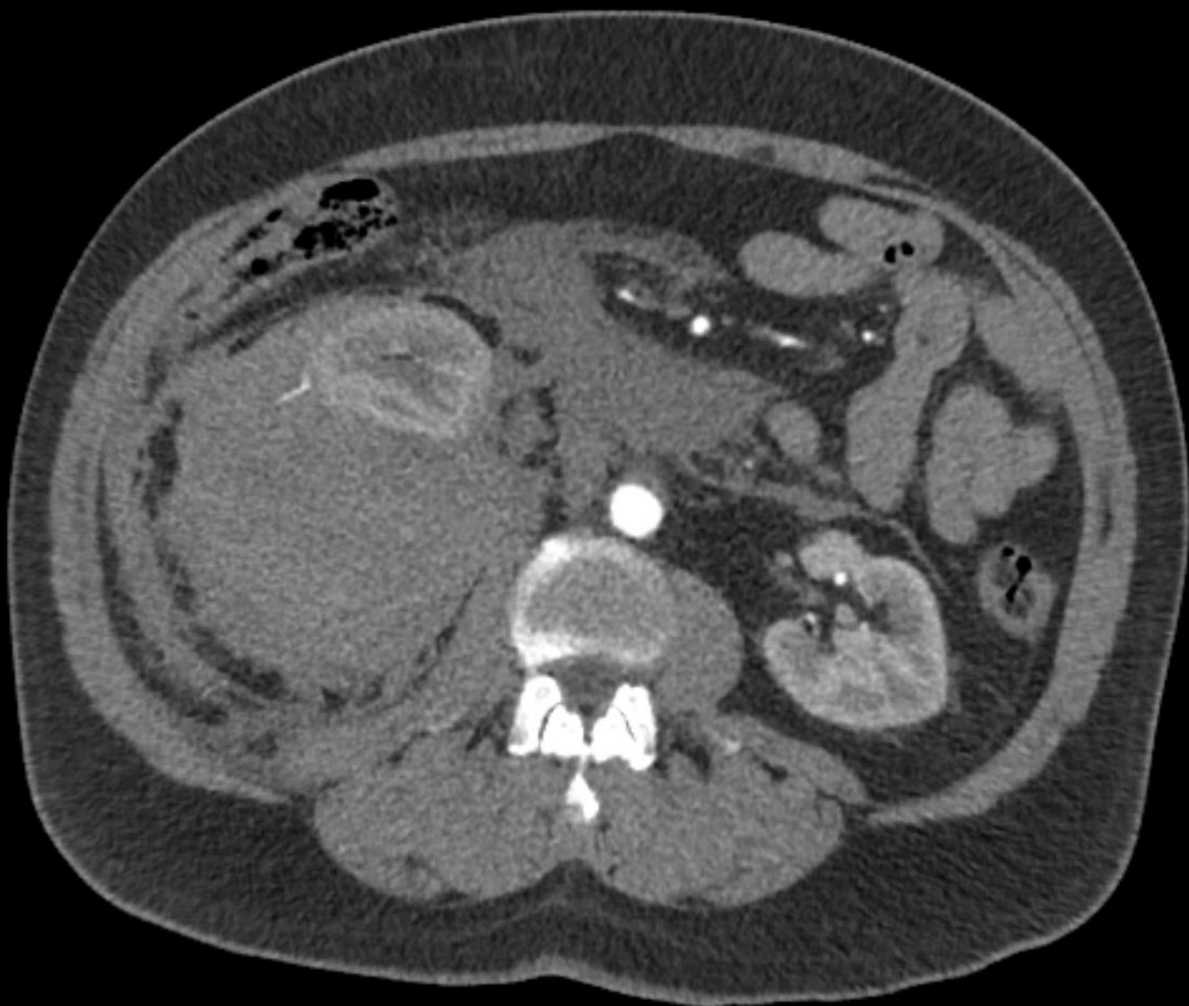Radiologic Procedure	Rating	Comments	RRL*
CT abdomen and pelvis without IV contrast	8	Reduced-dose techniques are preferred.	☼☼☼
CT abdomen and pelvis without and with IV contrast	6	This procedure is indicated if CT without contrast does not explain pain or reveals an abnormality that should be further assessed with contrast (eg, stone versus phleboliths).	☼☼☼☼
US color Doppler kidneys and bladder retroperitoneal	6		0
Radiography intravenous urography	4		☼☼☼
MRI abdomen and pelvis without IV contrast	4	MR urography.	0
MRI abdomen and pelvis without and with IV contrast	4	MR urography.	0
X-ray abdomen and pelvis (KUB)	3	This procedure can be performed with US as an alternative to NCCT.	☼☼
CT abdomen and pelvis with IV contrast	2		☼☼☼

Rating Scale: 1,2,3 Usually not appropriate; 4,5,6 May be appropriate; 7,8,9 Usually appropriate

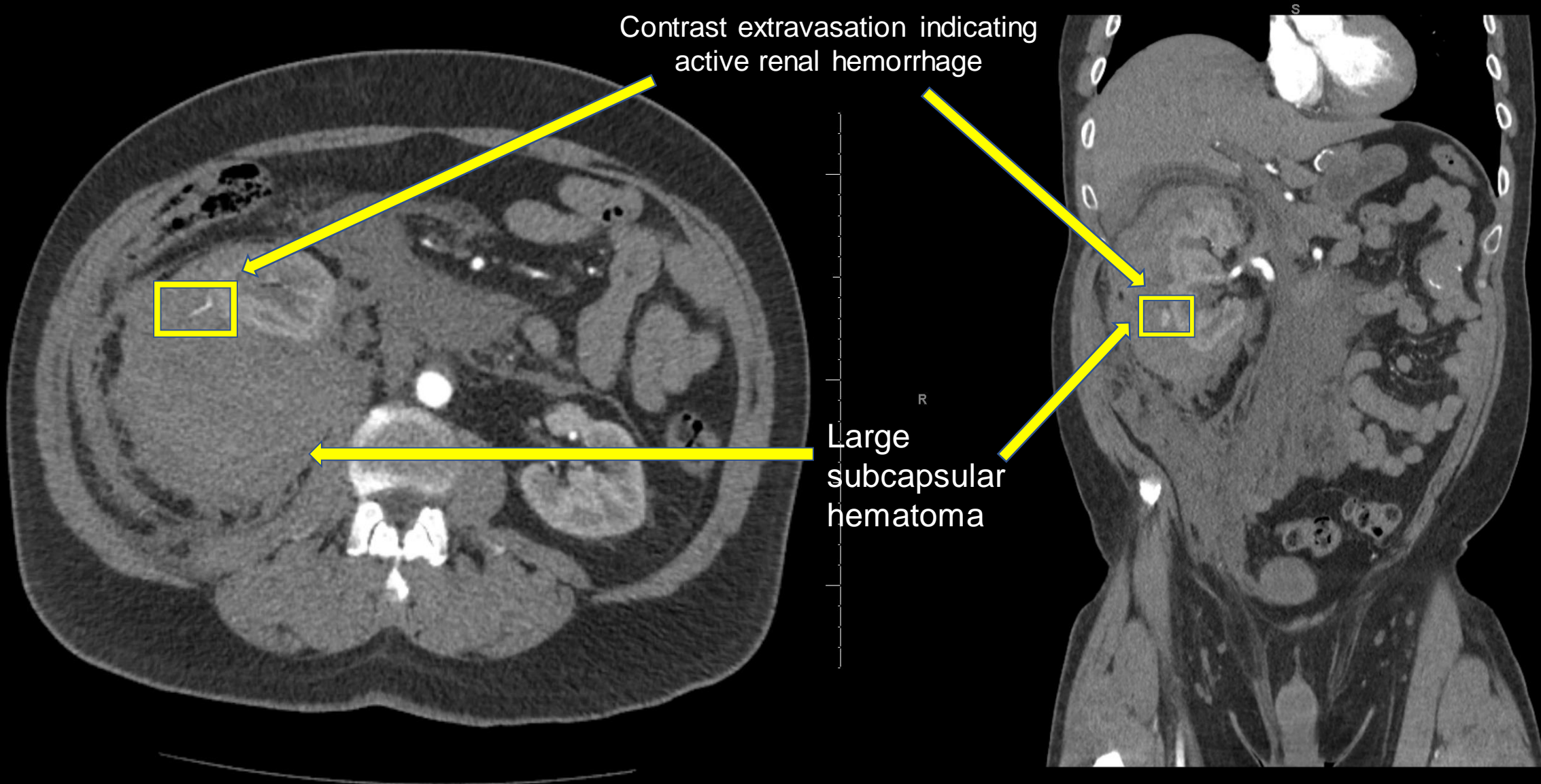
*Relative Radiation Level

This imaging modality was ordered by the ER physician

Findings CT with contrast (unlabeled)



Findings CT with contrast (labeled)



Contrast extravasation indicating active renal hemorrhage

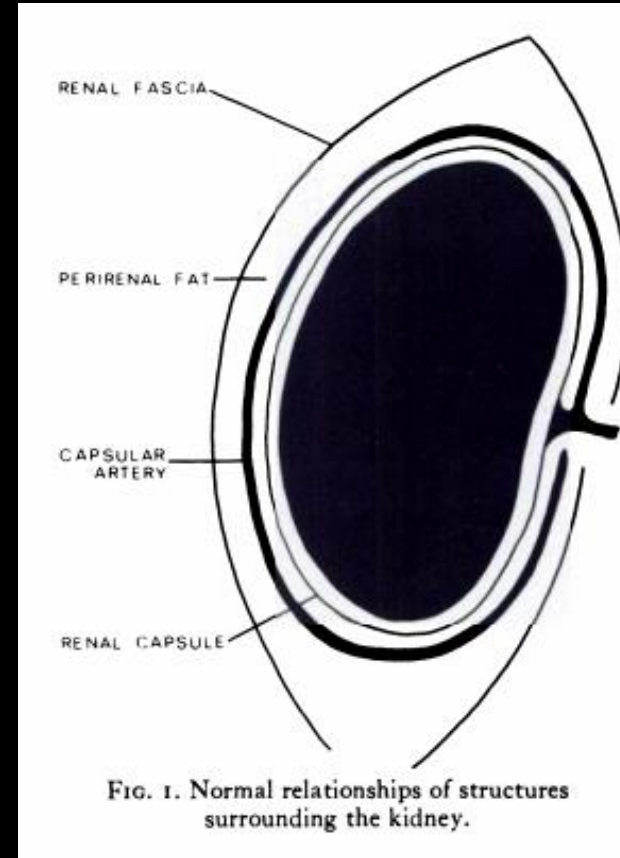
Large subcapsular hematoma

Final Dx:

Spontaneous renal hemorrhage and subsequent
subcapsular hematoma

Perinephric Hematoma 1/3

- Within retroperitoneal space, kidneys are surrounded by anterior (Gerota's) and posterior (Zuckerkandl) renal fascia
- Hematoma can be subcapsular or perinephric depending on whether it is contained by, or external to the renal capsule.
 - Given significant compression of the kidney in our patient, most likely subcapsular
- Etiologies of hematoma formation can include
 - Traumatic-(MVA, sports injury, falls, etc)
 - Most common
 - Iatrogenic (Biopsy, surgical injury, extracorporeal lithotripsy)
 - Spontaneous- (malignancy, anticoagulation, arteriovenous malformation)
 - **As in our patient, but exact etiology remains uncertain**
- Presentation
 - Any features or history suggesting above etiologies along with presence of flank pain \pm hematuria or hemodynamic instability



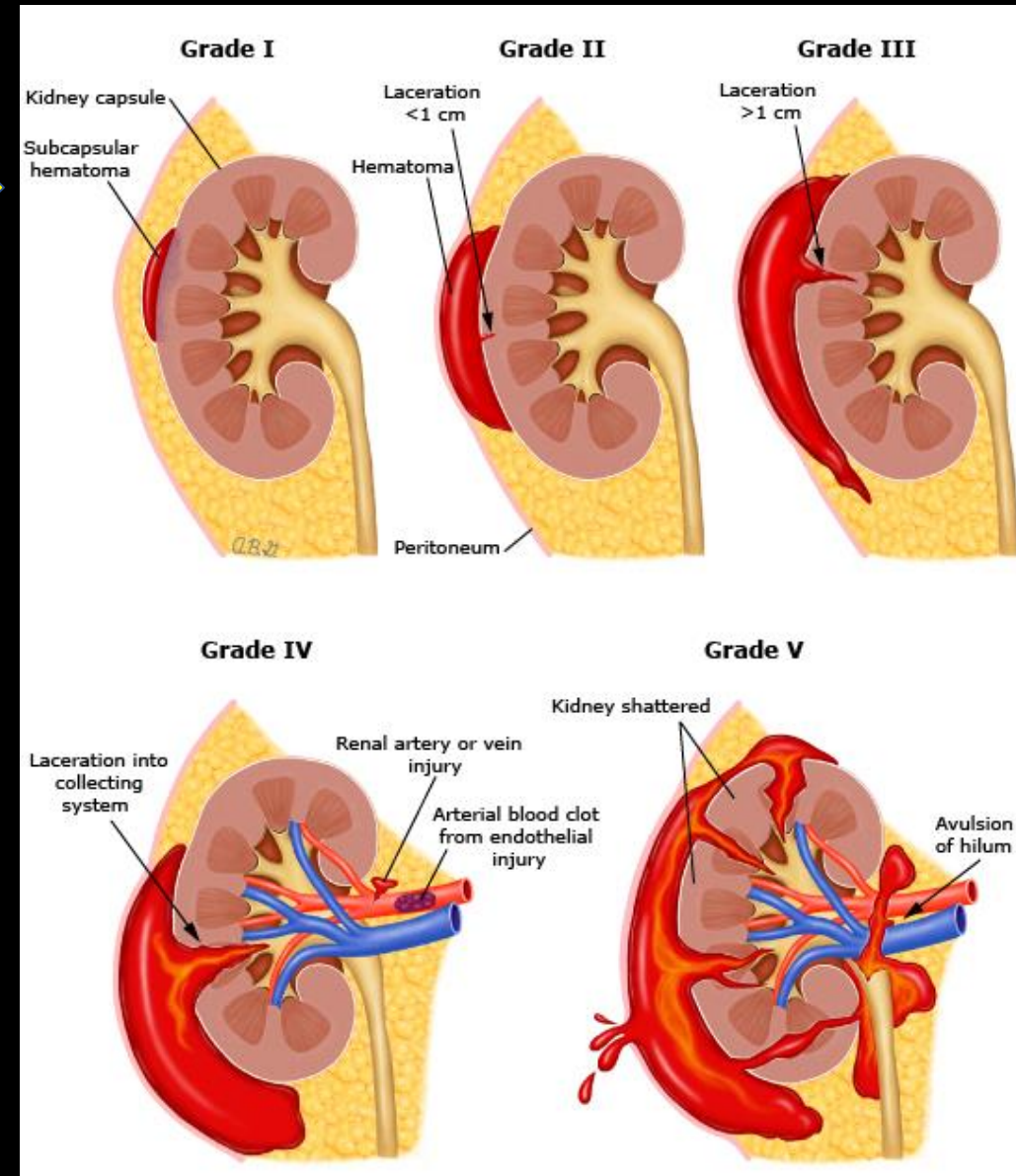
Meyers et. al

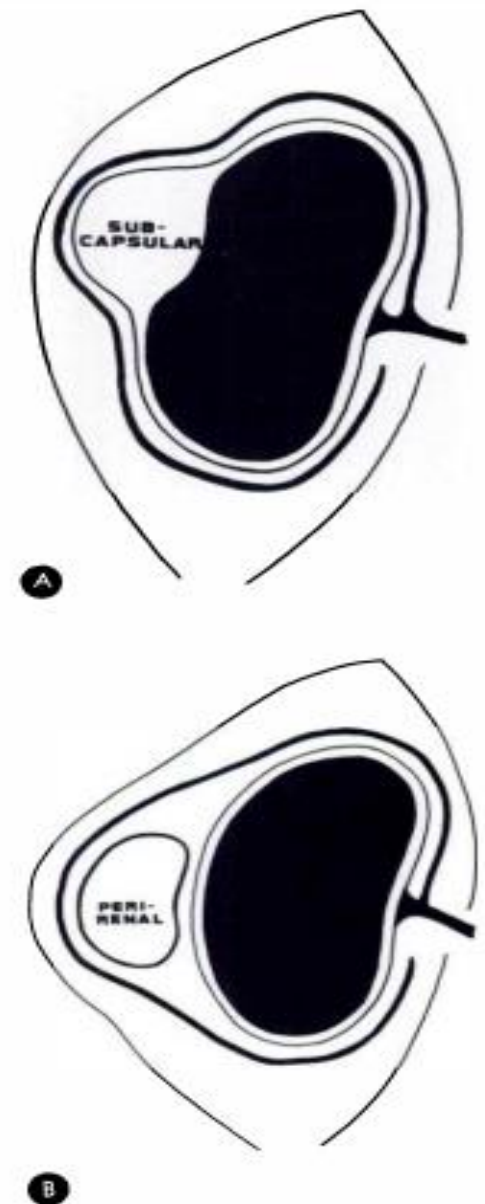

FIG. 9. Major findings distinguishing (A) a subcapsular from (B) a perinephric collection. Note particularly the relationships of the displaced renal capsule, perirenal fascia and capsular arteries at the borders of the mass. Flattening of the underlying renal parenchyma is more commonly found in subcapsular collections.

Perinephric Hematoma 2/3

- Hematoma formation can be graded based on size and invasion into collecting system
- Page Kidney: potential sequela of subcapsular hematoma
 - Rare cause of secondary hypertension
 - Pathophysiology
 - Extrinsic compression of kidney leads to decreased renal blood flow and perceived hypovolemia
 - Subsequent activation of RAAS (renin-angiotensin-aldosterone system) leads to hypertension
- Variable timing of presentation from immediate to few weeks after insult
 - This may or may not be present in our patient, BP is confounded by hypovolemia from hemorrhage



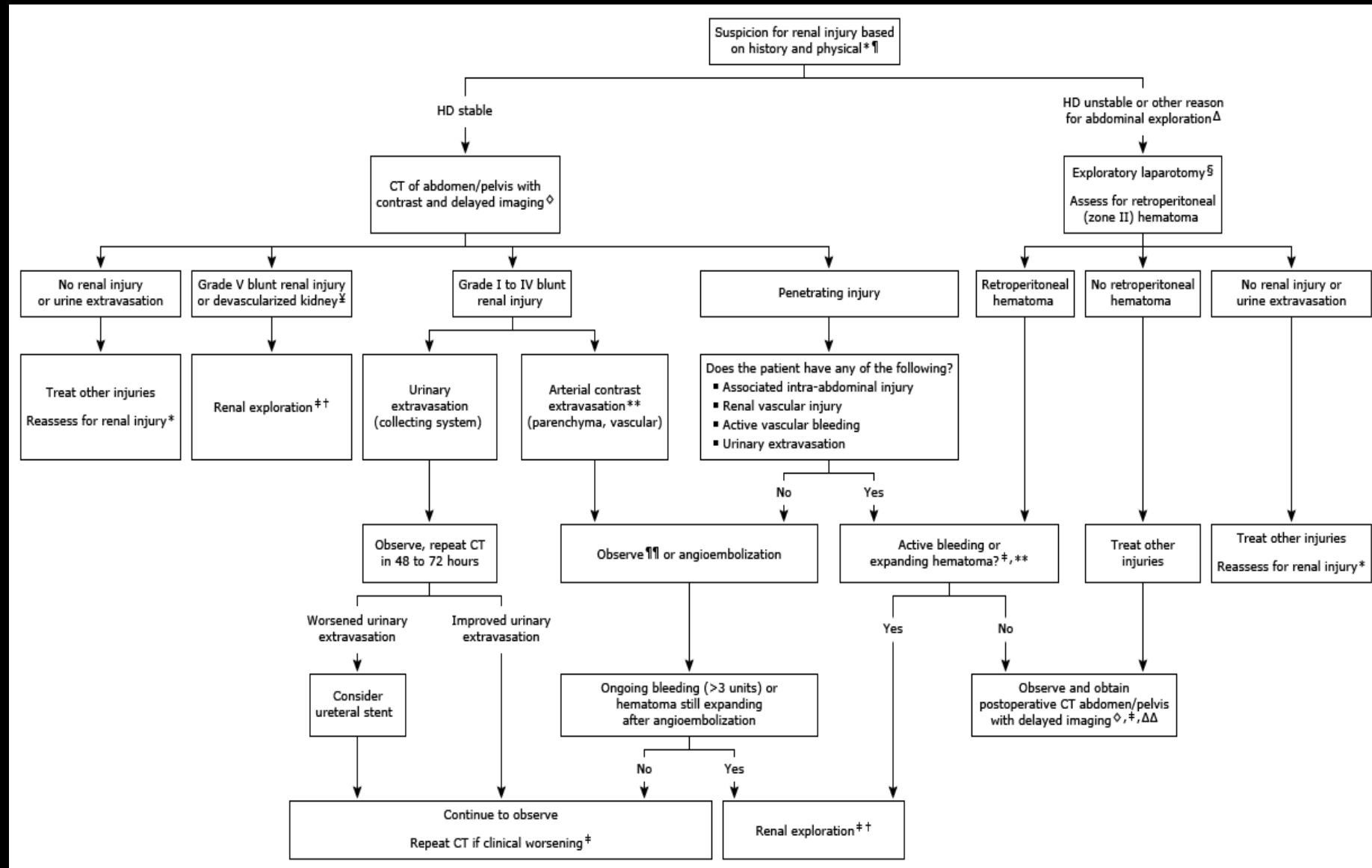
Perinephric Hematoma 3/3

Management flowchart per UpToDate

- General principles:
 - If HD stable, image and then embolize vs observation if <Grade IV blunt injury with active bleed, or penetrating without bleed
 - If HD stable and urinary involvement, image ± consult urology
 - If HD unstable, penetrating active bleed, or >Grade V blunt injury, proceed to laparotomy

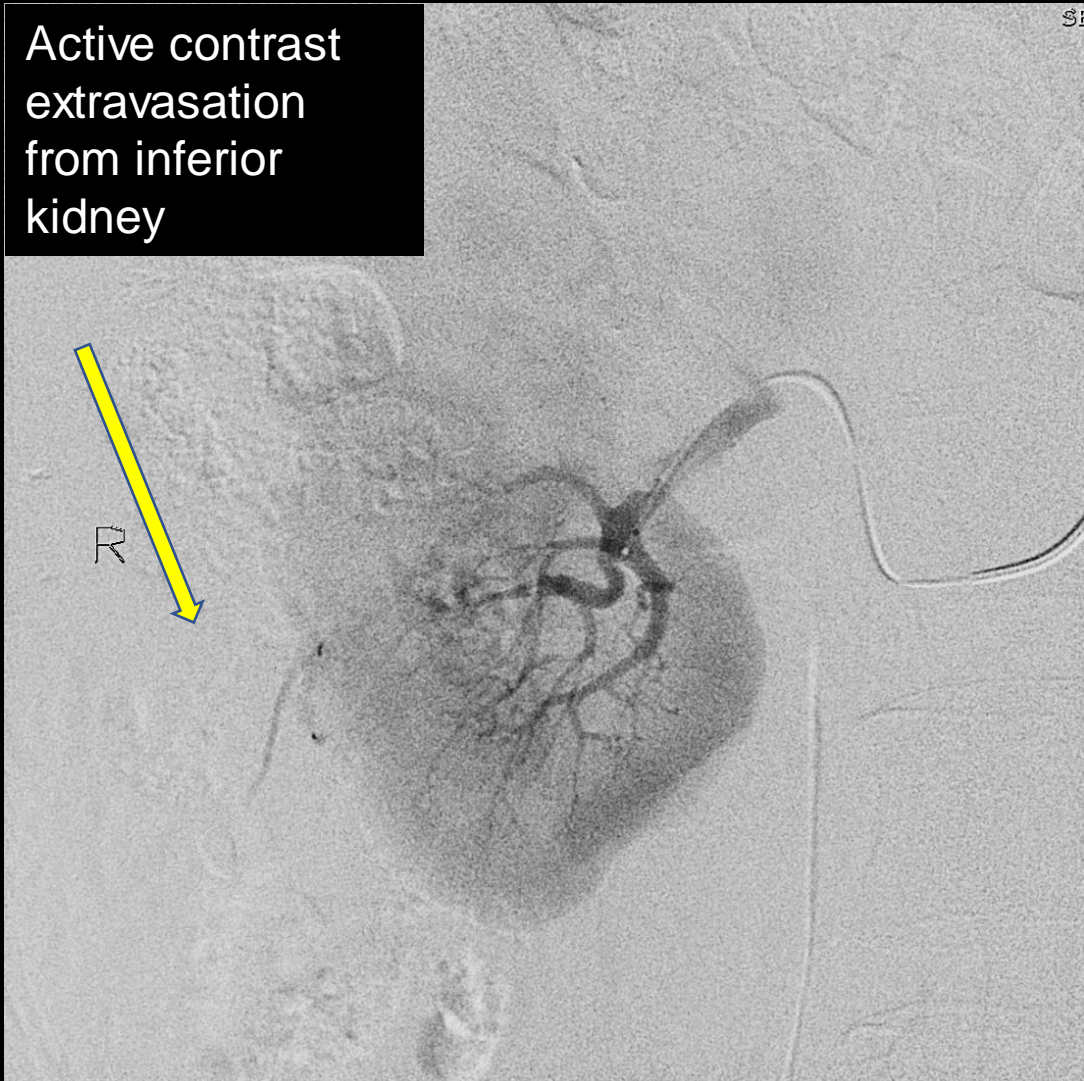
Patient outcome

- Underwent successful angioembolization (imaging next slide)
- Following up outpatient with urology for evaluation of etiology

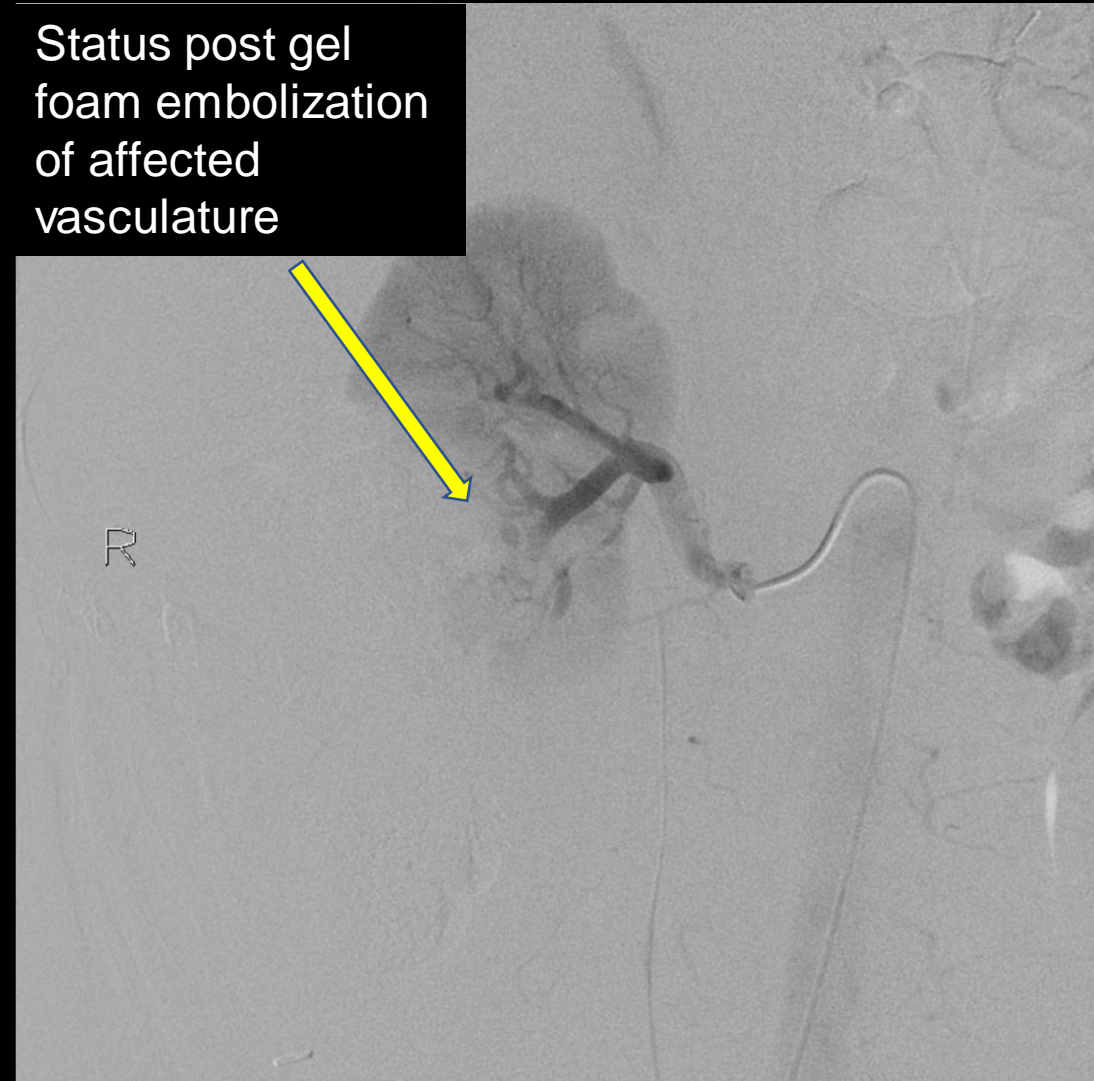


Fluoroscopic Angiography + Gel Foam Embolization: (labeled)

Active contrast extravasation from inferior kidney



Status post gel foam embolization of affected vasculature



References:

- American College of Radiology ACR Appropriateness Criteria Acute Onset Flank Pain – Suspicion of Stone Disease
<https://acsearch.acr.org/docs/69362/Narrative/>
- Vaidya PN, Rathi BM, Finnigan NA. Page Kidney. [Updated 2021 Apr 7]. In: StatPearls [Internet]. Treasure Island (FL): StatPearls Publishing; 2021 Jan-. Available from: <https://www.ncbi.nlm.nih.gov/books/NBK482486/>
- UpToDate. Voelzke B. “Management of Blunt and Penetrating Renal Trauma” In: *UpToDate*, Post TW (Ed), UpToDate, Waltham, MA. (Accessed on June 28, 2021.) <https://www.uptodate.com/contents/management-of-blunt-and-penetrating-renal-trauma#H1736971940>
- Meyers, Morton A., et al. “Diagnosis of Perirenal and Subcapsular Masses.” *American Journal of Roentgenology*, vol. 121, no. 3, American Roentgen Ray Society, July 1974, pp. 523–538. Crossref, doi:10.2214/ajr.121.3.523