

AMSER Case of the Month

August 2023

77-year-old male presenting for pre-operative evaluation prior to orthopedic surgery



Callie Deng, MS3

Dr. Elizabeth Lee

University of Michigan Medical School



Patient Presentation

- **HPI:** 77-year-old male with a right hip fracture after being struck by an automobile. Pre-operative assessment was performed prior to orthopedic surgery due to his complex medical history
- **PMHx:** Atrial fibrillation, coronary artery disease with history of myocardial infarction and ischemic cardiomyopathy
- **Surg Hx:** s/p cardiovascular implantable electronic device (CIED) placement
- **Physical exam:** Vital signs within normal limits. A&Ox3, in no acute distress.
 - Normal work of breathing. Heart regular rate and rhythm, normal S1 and S2
 - MSK exam shows R lower extremity foreshortened, externally rotated. No focal neurological deficits

Labs:

- **WBC:** 11.1 K/uL (H)
- **Hgb:** 11.2 g/dL (L)
- **INR:** 2.8 (on coumadin)

EKG: Normal sinus rhythm

What Imaging Should We Order?

Select the applicable ACR Appropriateness Criteria

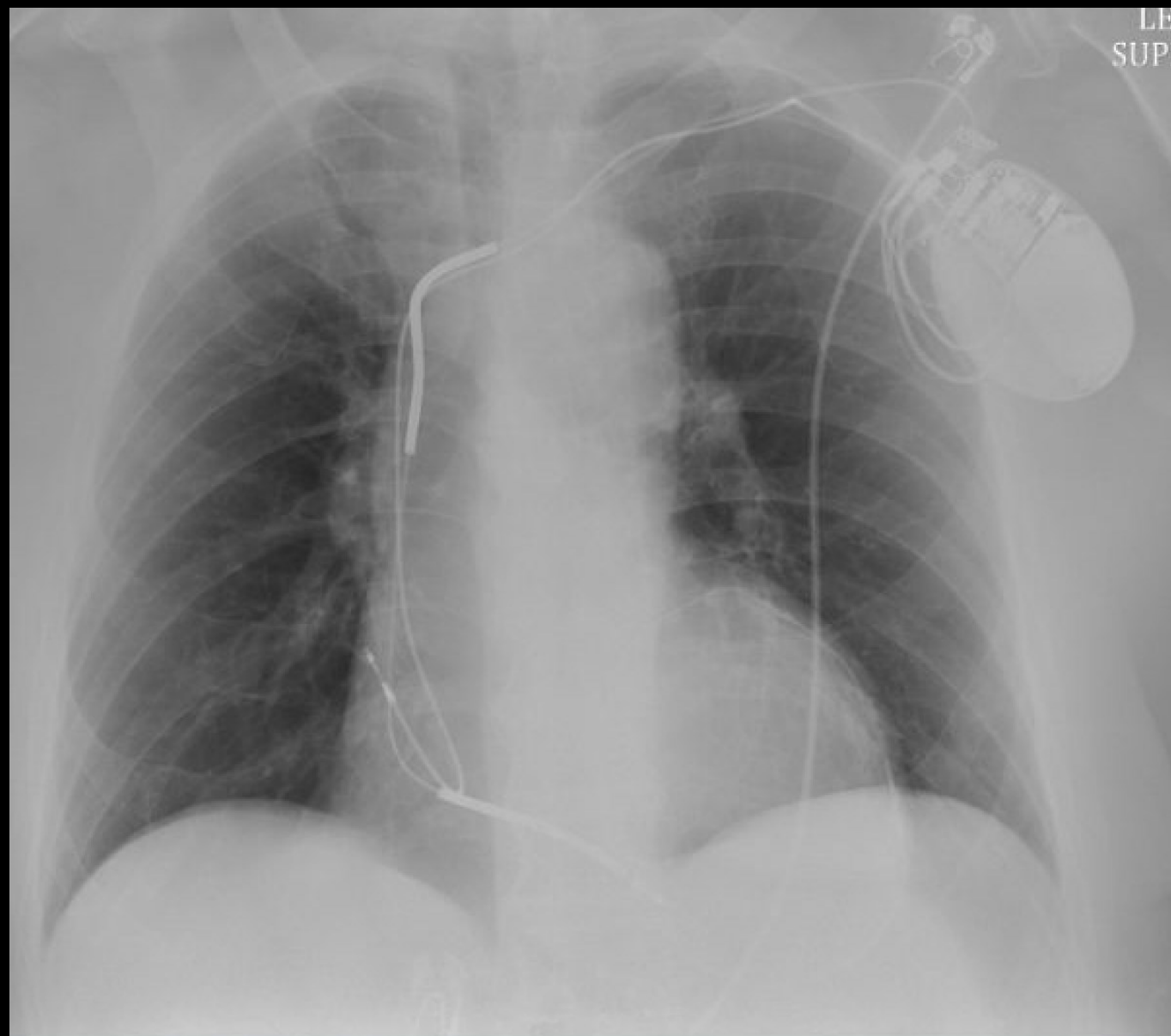
Variant 3:

Routine preoperative chest imaging for noncardiothoracic surgery. History of chronic cardiopulmonary disease or cardiothoracic surgery. Initial imaging.

Procedure	Appropriateness Category	Relative Radiation Level
Radiography chest	May Be Appropriate	☢
MRI chest without and with IV contrast	Usually Not Appropriate	○
MRI chest without IV contrast	Usually Not Appropriate	○
CT chest with IV contrast	Usually Not Appropriate	☢☢☢
CT chest without and with IV contrast	Usually Not Appropriate	☢☢☢
CT chest without IV contrast	Usually Not Appropriate	☢☢☢

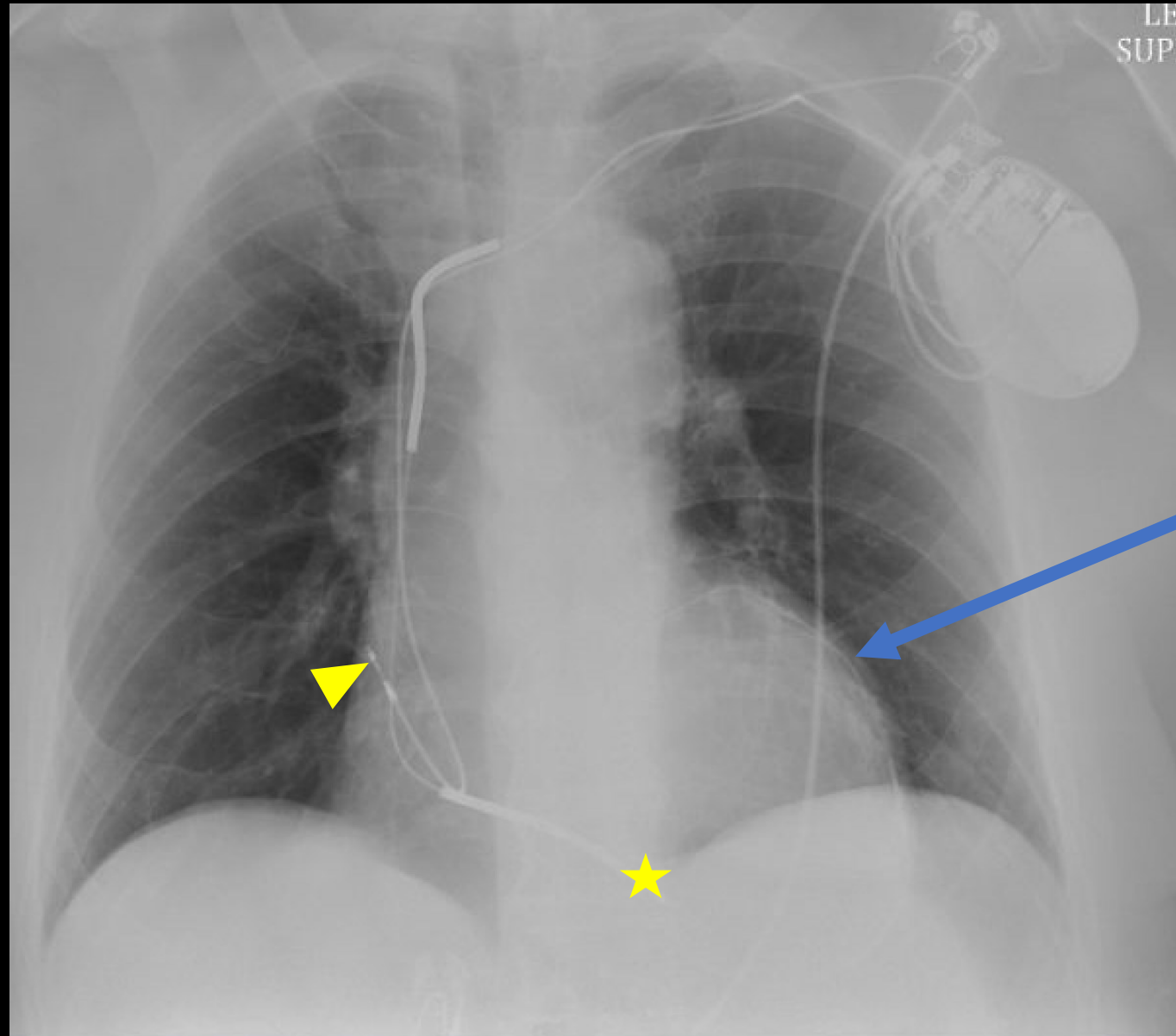
This was ordered as part of the pre-operative assessment

Findings (unlabeled)



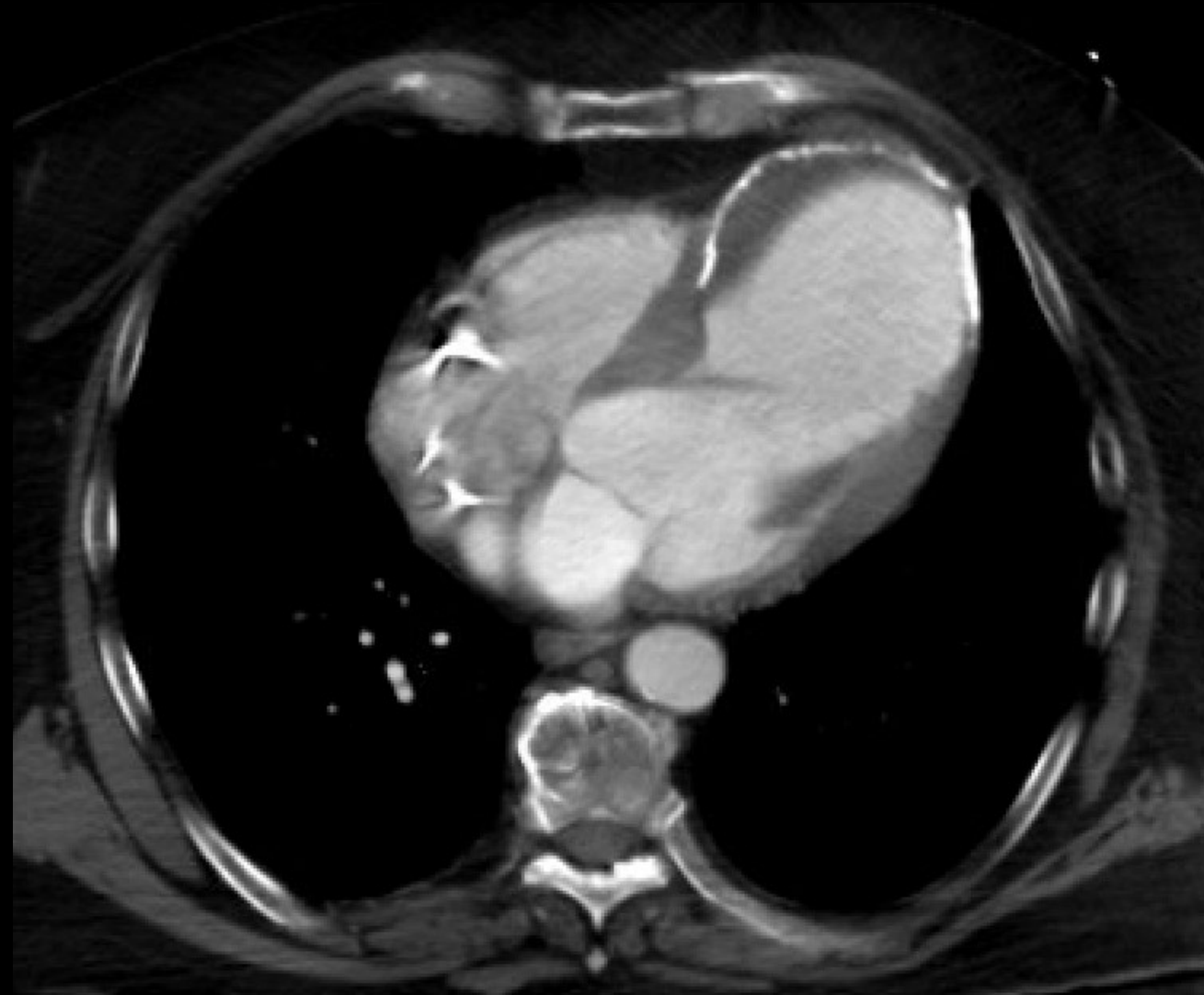
Findings (labeled)

Left chest wall CIED with leads terminating in the right atrium (arrowhead) and right ventricle (star).



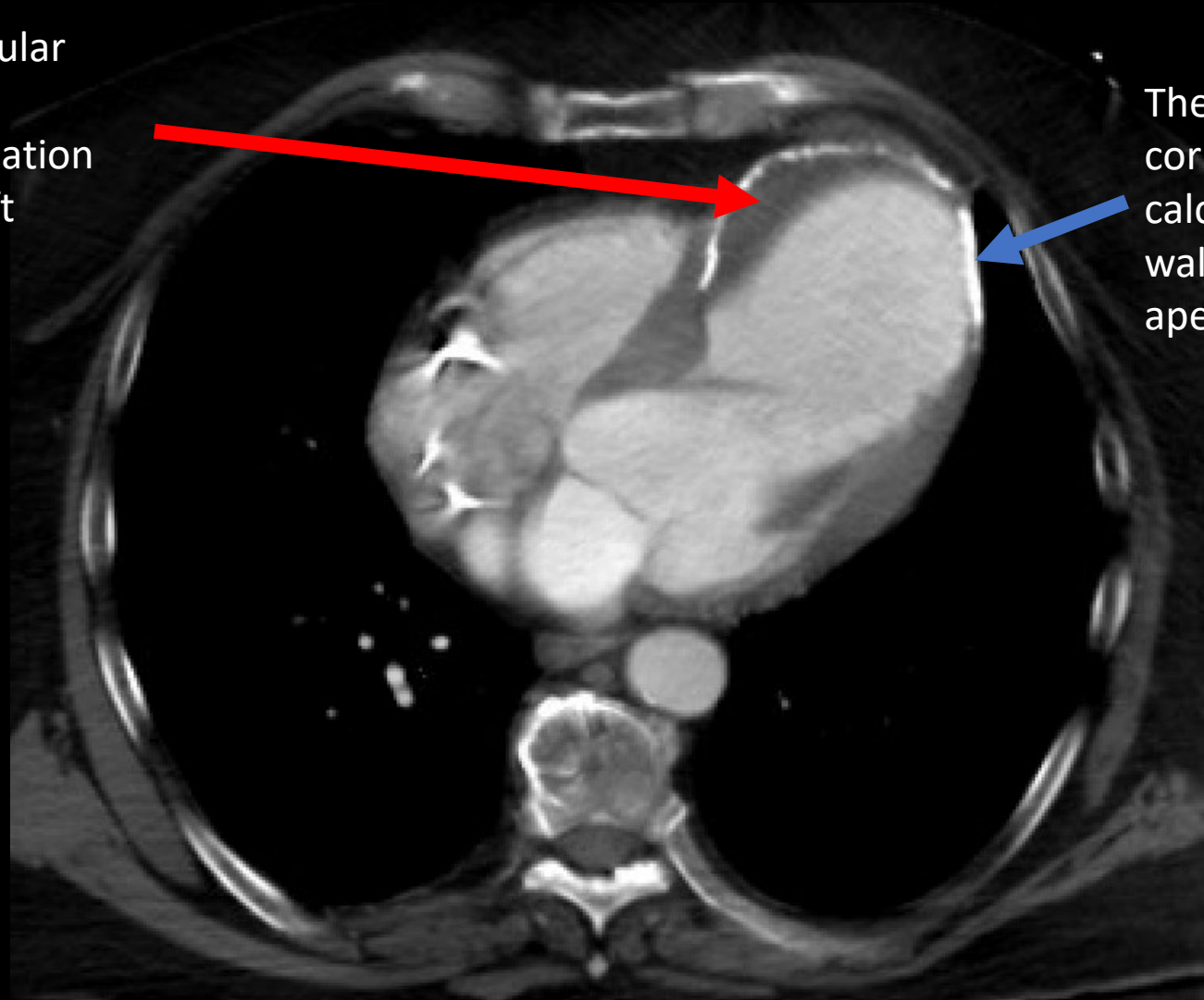
Calcifications along the left side of the cardiac silhouette

Findings (unlabeled) of recently performed CT of the chest with contrast



Findings (labeled) of recently performed CT of the chest with contrast

Along the left ventricular calcifications there is crescentic low attenuation located within the left ventricular cavity.



The calcifications seen on the CXR correspond to myocardial calcification of the left ventricular wall which is also thinned at the apex. The left ventricle is dilated.

Final Dx:

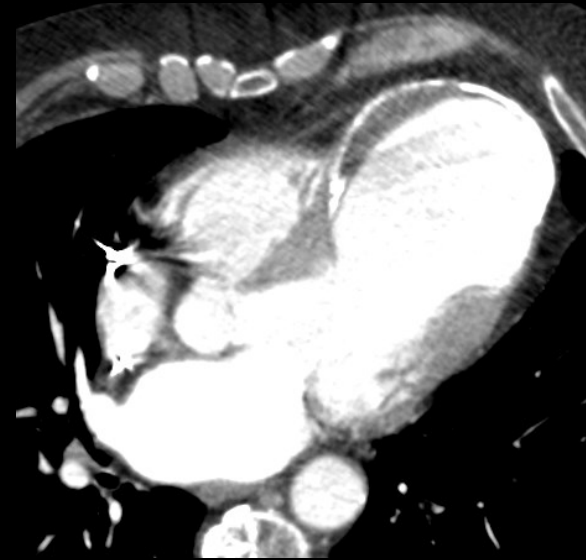Left ventricular apical aneurysm w/ thrombus

Case Discussion

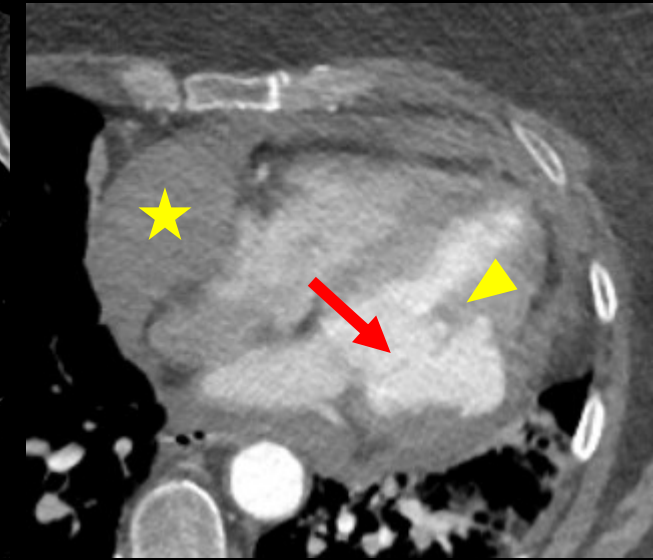
LV apical aneurysm

- **Causes:** Sequelae of acute MI, prior cardiac surgery, Chagas disease, cardiac sarcoidosis, hypertrophic cardiomyopathy
- **Imaging features:**
 - Well-delineated area of myocardium that is thin and nonfunctional (akinetic/dyskinetic)
 - Arises from a **broad base** or "neck" of uninterrupted myocardium
 - **Compared to pseudoaneurysm**, which arises from a **narrow neck** with abrupt interruption in ventricular myocardium
 - 70-85% of LV aneurysms are located in the **anterior or apical walls**, associated with LAD occlusion w/o collateralization
 - **Compared to pseudoaneurysm**, which are often located in the posterior and lateral walls

Aneurysm



Pseudoaneurysm

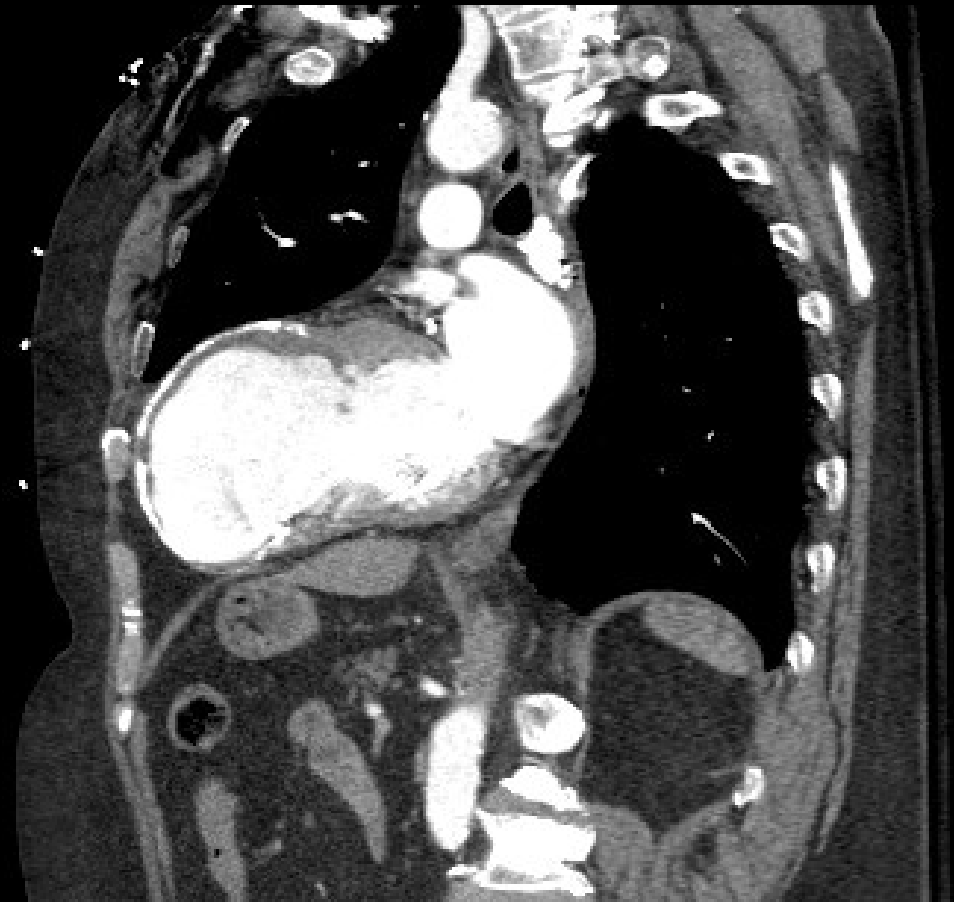


Notice the large neck of the apical aneurysm compared to the narrow neck of a pseudoaneurysm (**arrow**) as well as the presence of hemopericardium (**star**) and abruptly interrupted myocardium (**arrowhead**).

Case Discussion

LV apical aneurysm

- **Sequelae:** approximately 50% of LV aneurysms are filled with **thrombus**
- **Prognosis:** Survival in patients with chronic LV aneurysms is comparable to patients without aneurysms after adjusting for degree of LV dysfunction
- **Treatment:** Medical therapy for reduced systolic function, anticoagulation, longitudinal monitoring for changes in LV function and aneurysm size; resection considered in select cases
 - Compared to pseudoaneurysm, which **requires urgent surgical repair** due to high risk of rupture (30-45%) and death



References:

1. El Ouazzani J, Jandou I. Aneurysm and pseudoaneurysm of the left ventricle. *Ann Med Surg (Lond)*. 2022;75:103405. Published 2022 Feb 24. doi:10.1016/j.amsu.2022.103405
2. Oyedeji AT, Lee C, Owojori OO, Ajegbomogun OJ, Akintunde AA. Successful medical management of a left ventricular thrombus and aneurysm following failed thrombolysis in myocardial infarction. *Clin Med Insights Cardiol*. 2013;7:35-41. doi:10.4137/CMC.S10929
3. Sattar Y, Alraies MC. Ventricular Aneurysm. [Updated 2022 Nov 14]. In: StatPearls [Internet]. Treasure Island (FL): StatPearls Publishing; 2023 Jan-. Available from: <https://www.ncbi.nlm.nih.gov/books/NBK555955/>
4. Keeley EC, Hillis LD. Left ventricular mural thrombus after acute myocardial infarction. *Clin Cardiol*. 1996;19(2):83-86. doi:10.1002/clc.4960190203
5. Sui Y, Teng S, Qian J, Zhao Z, et al. Treatment outcomes and therapeutic evaluations of patients with left ventricular aneurysm. *J Int Med Res*. 2019, 47:244-51. 10.1177/0300060518800127
6. Cho MN, Mehta SK, Matulevicius S, et al. Differentiating true versus pseudo left ventricular aneurysm: a case report and review of diagnostic strategies. *Cardiol Rev*. 2006;14 (6): e27-30. doi:10.1097/01.crd.0000233756.66532.45
7. Ousaka D, Obara N, Fujiwara M, et al. A case of conservative management for left ventricular giant pseudoaneurysm without ST segment changes. *J Cardiol Cases*. 2018;17(5):167-170. Published 2018 Feb 9. doi:10.1016/j.jccase.2018.01.006
8. Inayat F, Ghani AR, Riaz I, et al. Left Ventricular Pseudoaneurysm: An Overview of Diagnosis and Management. *J Investig Med High Impact Case Rep*. 2018;6:2324709618792025. Published 2018 Aug 2. doi:10.1177/2324709618792025