

AMSER Case of the Month

February 2023

Bouverete Syndrome

Chinedu Ezikanyi (MS3)
Drexel University College of Medicine

Lawrence Uradu, MD
University Of Pittsburgh Medical Center



Patient Presentation

- 77y/o M with h/o CAD with MI s/p PCI (2019) CHF with LV dysfunction and TIIDM
- Presents with Intermittent abdominal pain and N/V x 2-3 weeks. Worse with food. Vomited 5-8 times. No blood. 8-10lb weight loss over 1 week.
- Vital:
 - BP 153/77 mmHg, HR 64, RR 18, Temp 36.6
- Physical:
 - Generalized abdominal pain, no guarding or rebound tenderness

Pertinent Labs

- CBC: WNL
- CMP: WNL

What Imaging Should We Order?

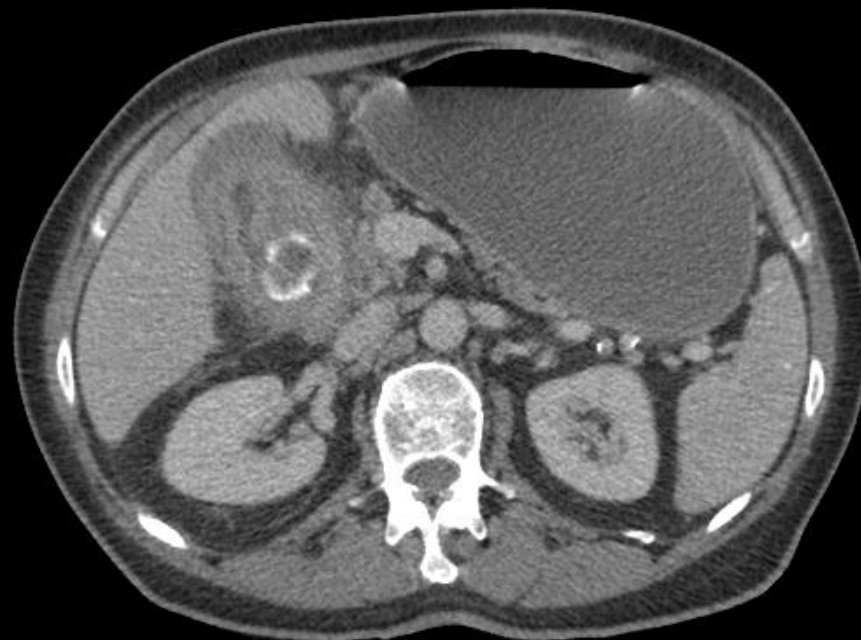
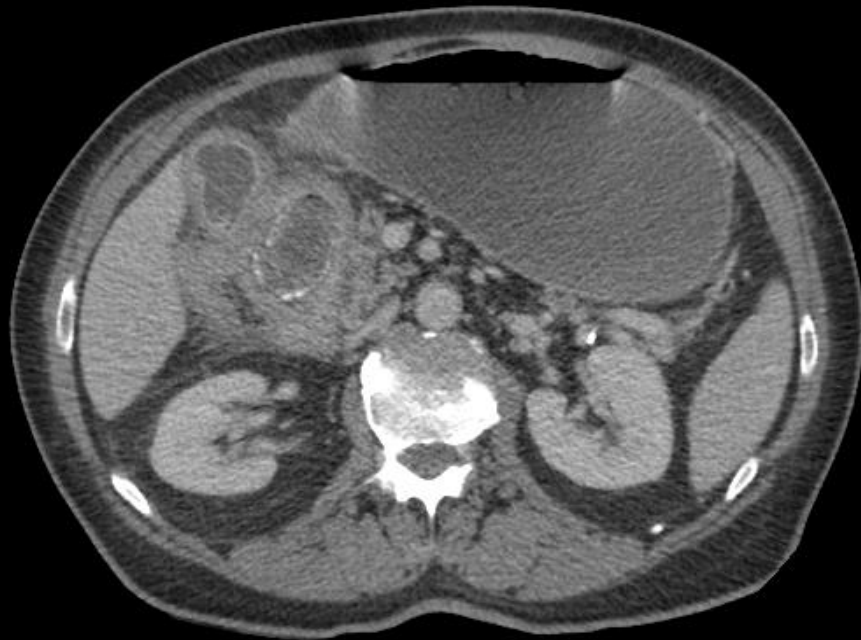Select the applicable ACR Appropriateness Criteria

Variant 4: Acute nonlocalized abdominal pain. Not otherwise specified. Initial imaging.

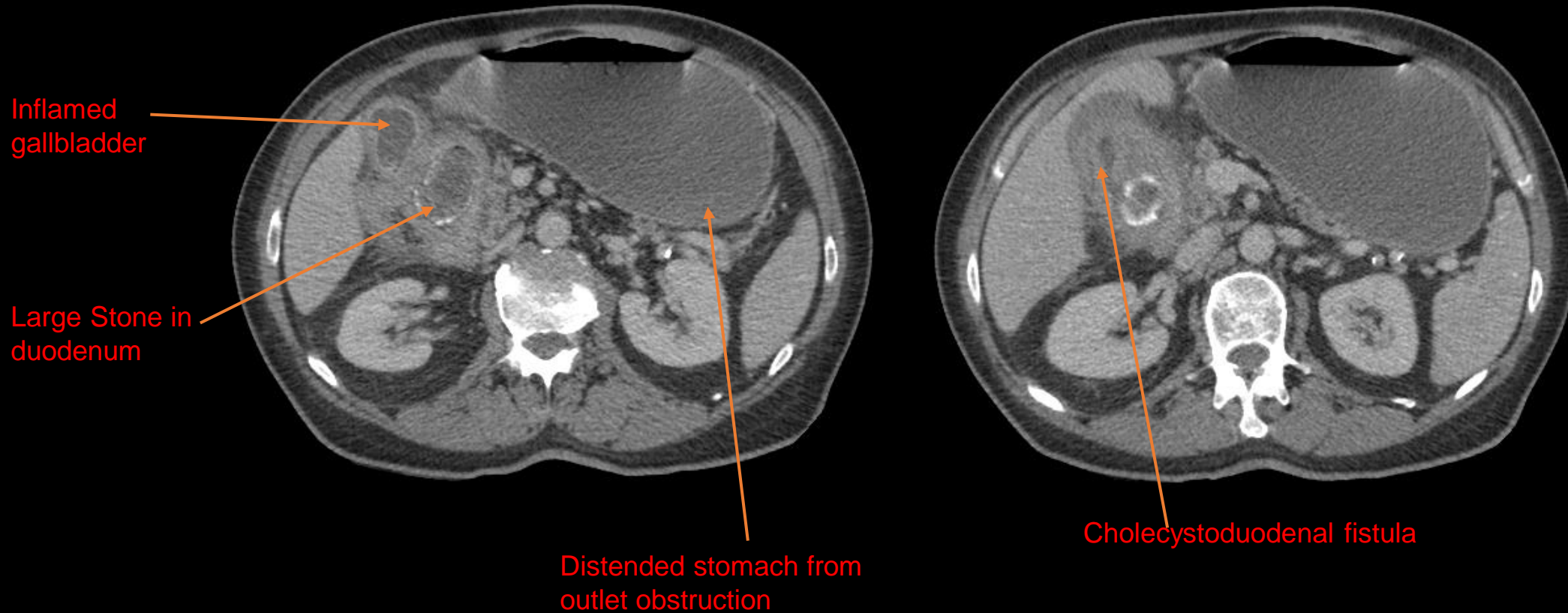
Procedure	Appropriateness Category	Relative Radiation Level
CT abdomen and pelvis with IV contrast	Usually Appropriate	☼☼☼
CT abdomen and pelvis without IV contrast	Usually Appropriate	☼☼☼
MRI abdomen and pelvis without and with IV contrast	Usually Appropriate	○
US abdomen	May Be Appropriate	○
MRI abdomen and pelvis without IV contrast	May Be Appropriate	○
CT abdomen and pelvis without and with IV contrast	May Be Appropriate	☼☼☼☼
Radiography abdomen	May Be Appropriate	☼☼
FDG-PET/CT skull base to mid-thigh	Usually Not Appropriate	☼☼☼☼
WBC scan abdomen and pelvis	Usually Not Appropriate	☼☼☼☼
Nuclear medicine scan gallbladder	Usually Not Appropriate	☼☼
Fluoroscopy upper GI series with small bowel follow-through	Usually Not Appropriate	☼☼☼
Fluoroscopy contrast enema	Usually Not Appropriate	☼☼☼

This imaging modality was ordered by the ER physician

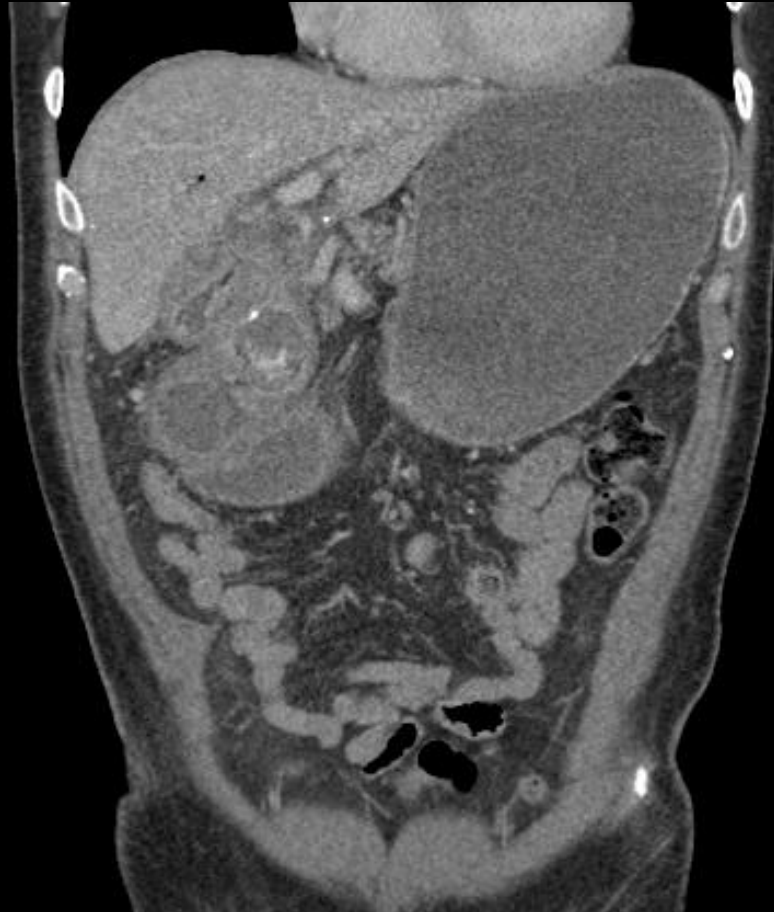
Findings (unlabeled)



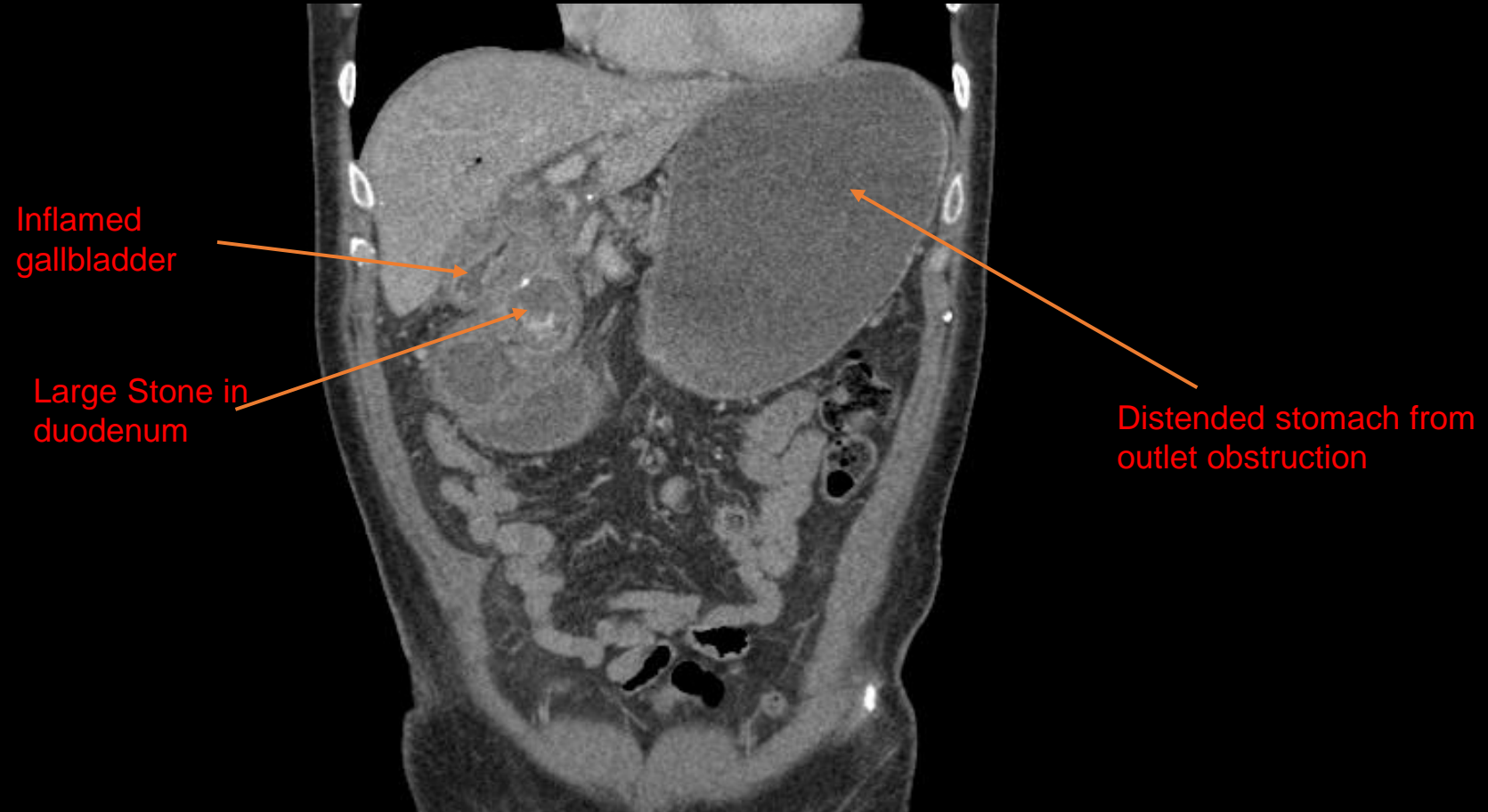Findings: (labeled)



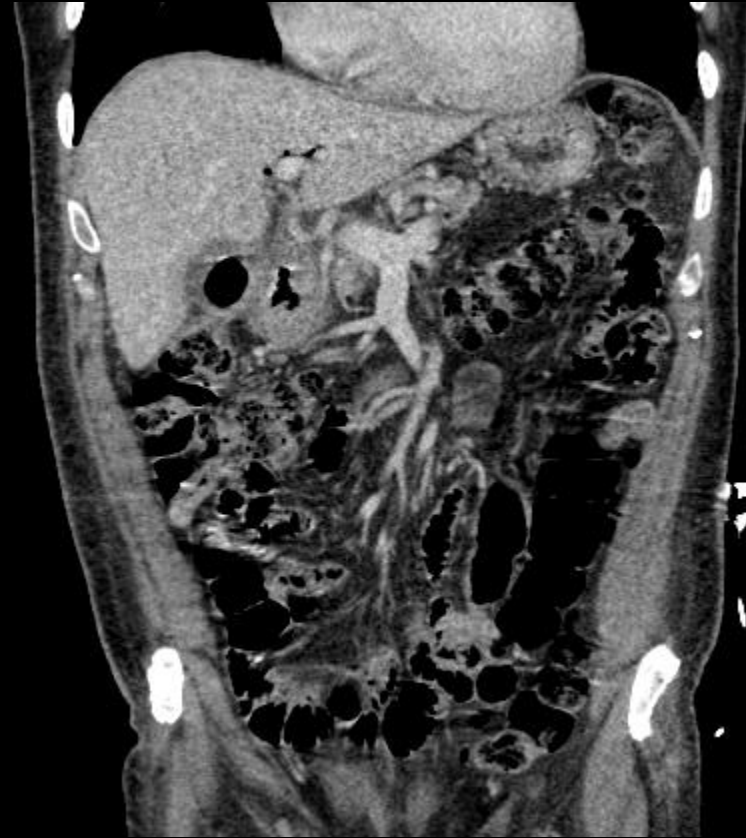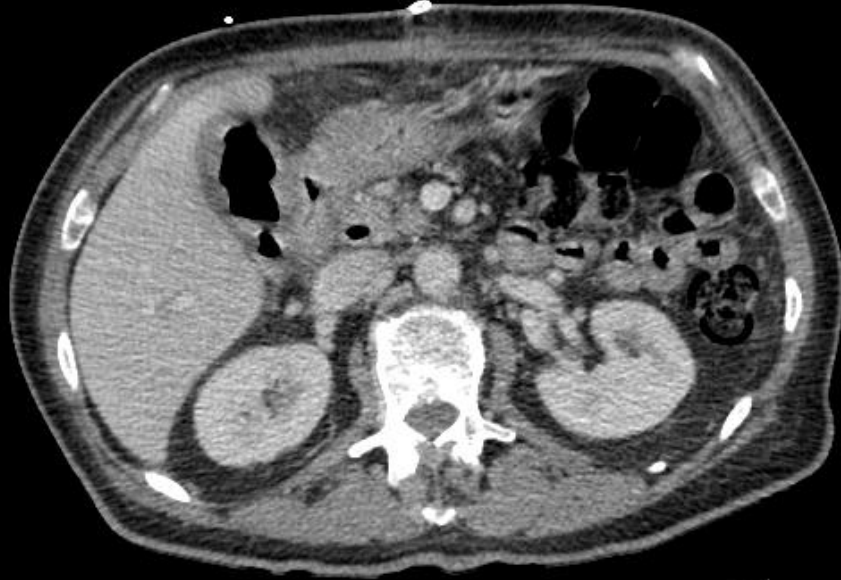Findings (unlabeled)



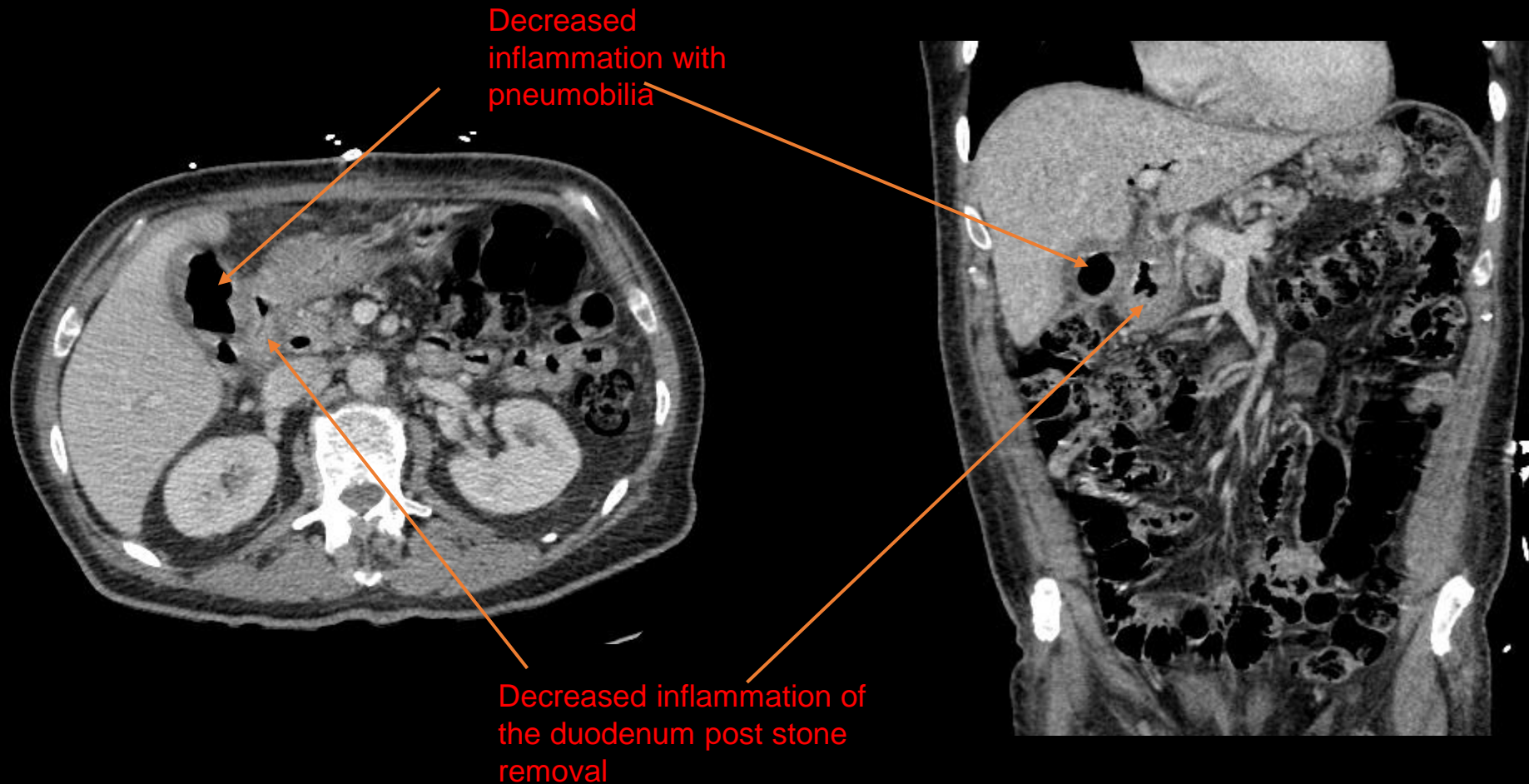
Findings: (labeled)



Postop Findings (unlabeled)



Postop Findings: (labeled)



Final Dx:

Bouverete Syndrome

Case Discussion (1-3 slides)

Management:

- Gastrostomy was performed with 5cm gallstone removal from the pyloric end of the stomach. Gastric and gallbladder lacerations were repaired with resolution of the fistula. This resulted in decompression of the stomach and proximal duodenum. Inflammation of the gallbladder and proximal duodenum was resolved as seen in the postop images

Case Discussion (1-3 slides)

- Bouverete Syndrome is a rare complication of cholelithiasis that presents with signs of gastric outlet obstruction secondary to gallstone impaction of the pylorus
- It can be considered as gallstone ileus of the proximal duodenum due to an acquired fistula between the gallbladder and duodenum (though, can involve the pylorus as in this case)
- Clinical presentation:
 - Occurs more commonly in elderly women >65 years of age
 - s/s include nausea, vomiting, and epigastric pain
 - May present along with pancreatitis

Case Discussion (1-3 slides)

- Imaging:
 - May show cholecystenteric fistula
 - May show bowel obstruction, pneumobilia & ectopic gallstone
- Treatment:
 - Mortality rate is as high as 12-33%, so early detection is important
 - Endoscopic treatment typically preferred over surgery and may involve mechanical, electrohydraulic and laser lithotripsy

References:

- Caldwell, K. M., Lee, S., Leggett, P. L., Bajwa, K. S., Mehta, S. S., & Shah, S. K. (2018). Bouveret Syndrome: Current management strategies. *Clinical and Experimental Gastroenterology, Volume 11*, 69–75. <https://doi.org/10.2147/ceg.s132069>
- Gaillard F, Saber M, El-Feky M, et al. Bouveret syndrome. Reference article, Radiopaedia.org (Accessed on 20 Nov 2022) <https://doi.org/10.53347/rID-6908>
- *ACR appropriateness criteria*®.® | American College of Radiology. (n.d.). Retrieved November 27, 2022, from <https://www.acr.org/Clinical-Resources/ACR-Appropriateness-Criteria>
- Singh, G., Merali, N., Shirol, S., Drymoussis, P., Singh, S., & Veeramootoo, D. (2020). A case report and review of the literature of Bouveret syndrome. *The Annals of The Royal College of Surgeons of England, 102*(1). <https://doi.org/10.1308/rcsann.2019.0161>
- Singh, G., Merali, N., Shirol, S., Drymoussis, P., Singh, S., & Veeramootoo, D. (2020). A case report and review of the literature of Bouveret syndrome. *The Annals of The Royal College of Surgeons of England, 102*(1). <https://doi.org/10.1308/rcsann.2019.0161>