

AMSER Case of the Month

January 2023

55-year-old woman with left upper chest wall pain and
nipple erythema

Kristian Quevada, MS4
Cooper Medical School of Rowan University

Pauline Germaine, DO
Cooper University Hospital



Patient Presentation

- **HPI:** 55 y.o. Female who presents with 1 week of upper left chest wall pain and left nipple erythema. The left nipple has been crusting and sore. She notes there are small blisters on the left nipple that have opened. Patient recalls moving heavy objects a week ago. She denies new detergent/lotion/soap, new exercise, or new bras.
- **PMH:** invasive ductal carcinoma of the upper outer quadrant of the left breast (Grade 3, ER+, PR-, HER2+), osteoporosis
- **PSH:** bilateral nipple sparing mastectomy, left sentinel and axillary lymph node dissection, bilateral subpectoral implant placement, bilateral salpingo-oophorectomy
- **Meds:** N/A
- **Allergies:** NKA
- **Vitals:** BP 128/77, Temp 98.4 F, BMI 23.54

Pertinent Labs

- **WBC:** 6.6 (normal)
- **RBC:** 4.97 (normal)
- **Hemoglobin:** 14.7 (normal)
- **MCV:** 89 (normal)
- **Platelets:** 218 (normal)
- **Calcium:** 10.4 (high)

What Imaging Should We Order?

Select the applicable ACR Appropriateness Criteria

Variant 8:

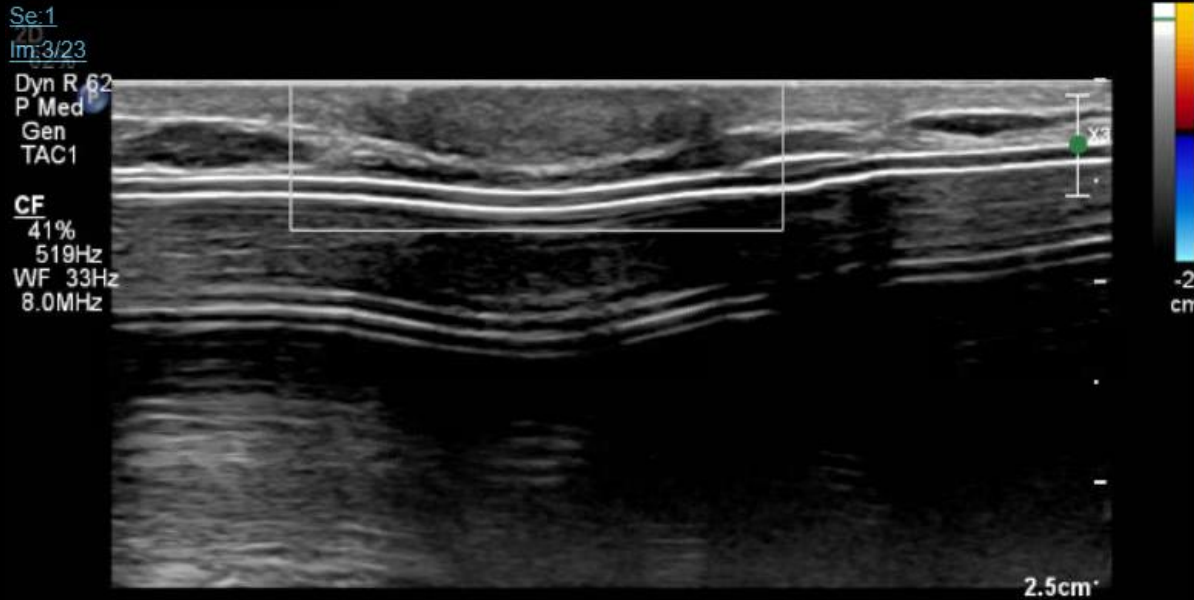
Female. Palpable lump or clinically significant pain on the side of the mastectomy with reconstruction (autologous or nonautologous). Initial imaging.

Procedure	Appropriateness Category	Relative Radiation Level
US breast	Usually Appropriate	0
Digital breast tomosynthesis diagnostic	May Be Appropriate	⊕⊕
Mammography diagnostic	May Be Appropriate	⊕⊕
MRI breast without and with IV contrast	Usually Not Appropriate	0
MRI breast without IV contrast	Usually Not Appropriate	0
Sestamibi MBI	Usually Not Appropriate	⊕⊕⊕
FDG-PET breast dedicated	Usually Not Appropriate	⊕⊕⊕⊕

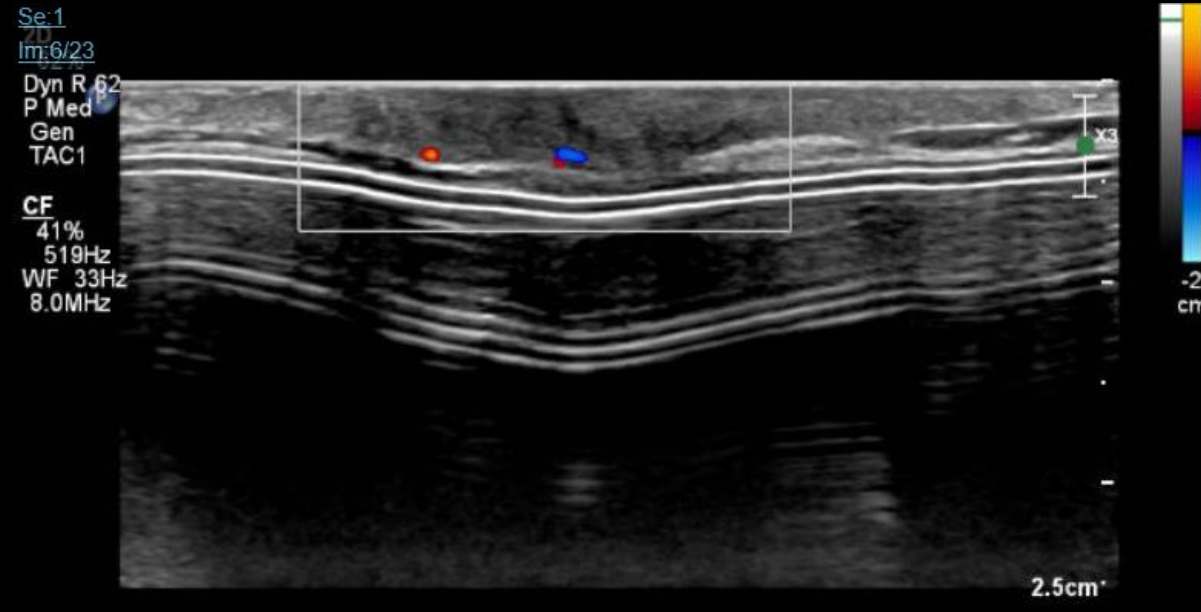
These imaging modalities were ordered by breast surgery



Findings: (unlabeled)

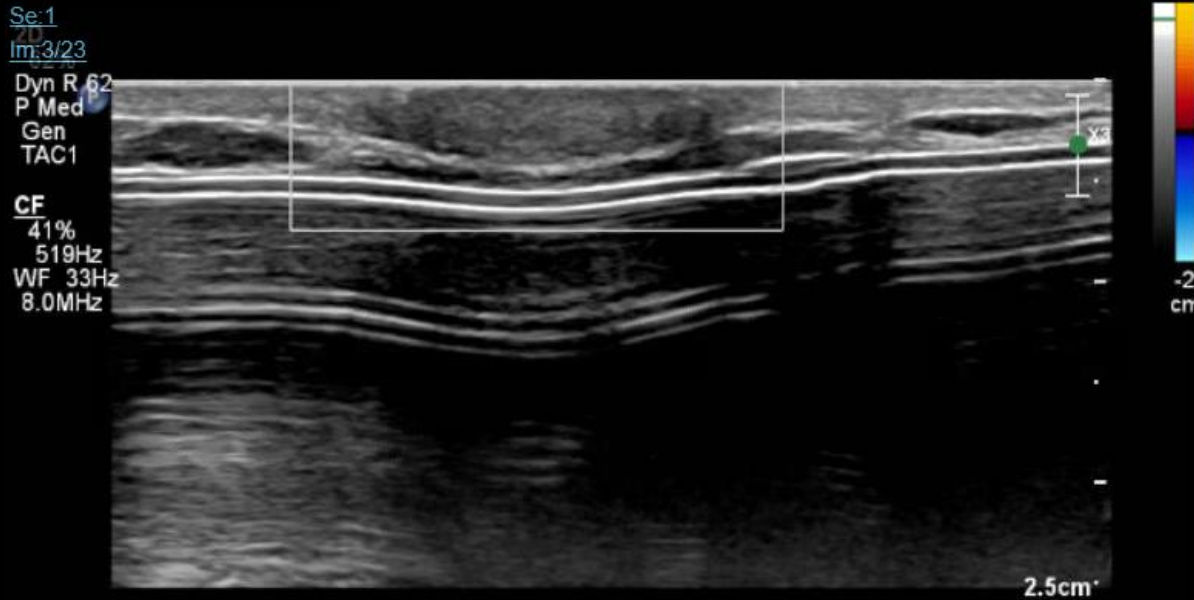


Left Nipple A Rad

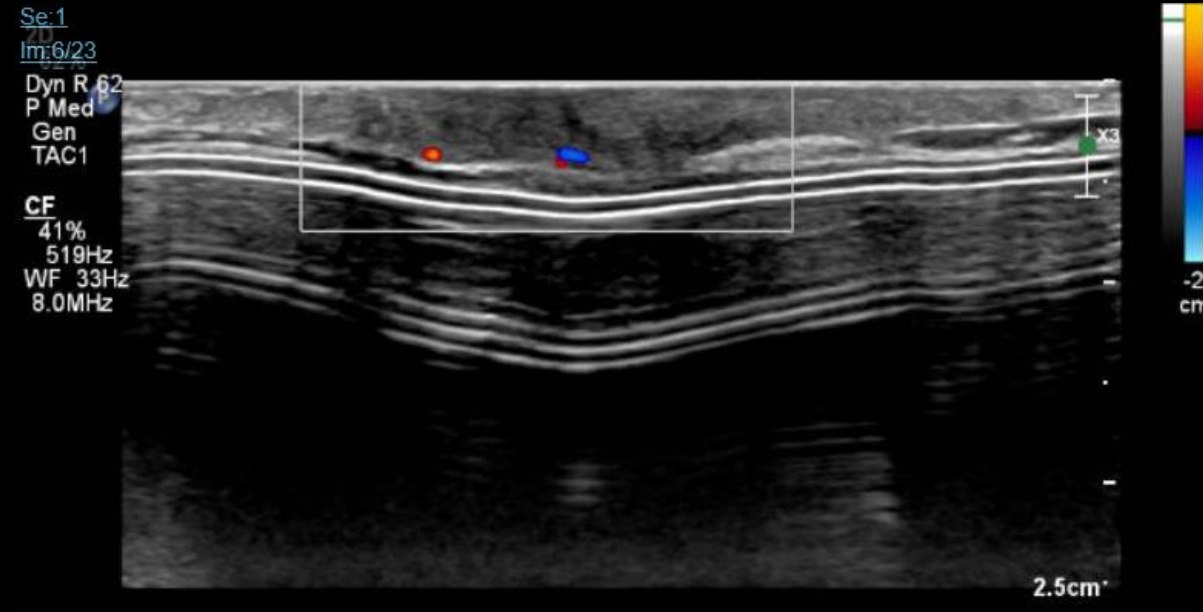


Left Nipple Rad

Findings: (labeled)



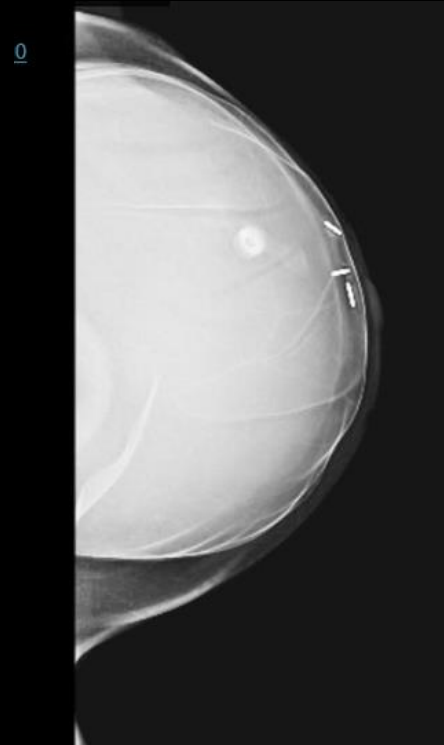
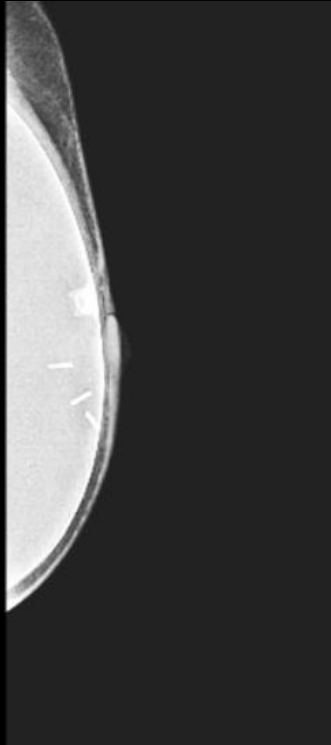
Left Nipple A Rad



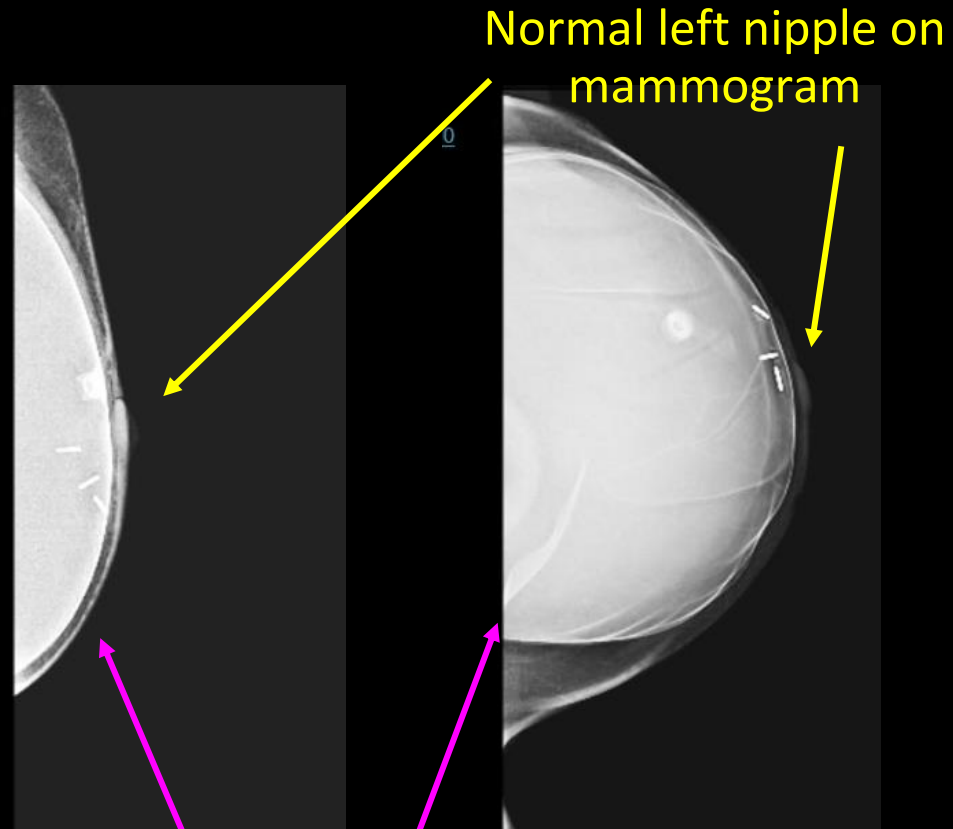
Left Nipple Rad

Normal ultrasound of the left nipple with symmetric ultrasound appearance to the right side (not shown)

Findings: (unlabeled)

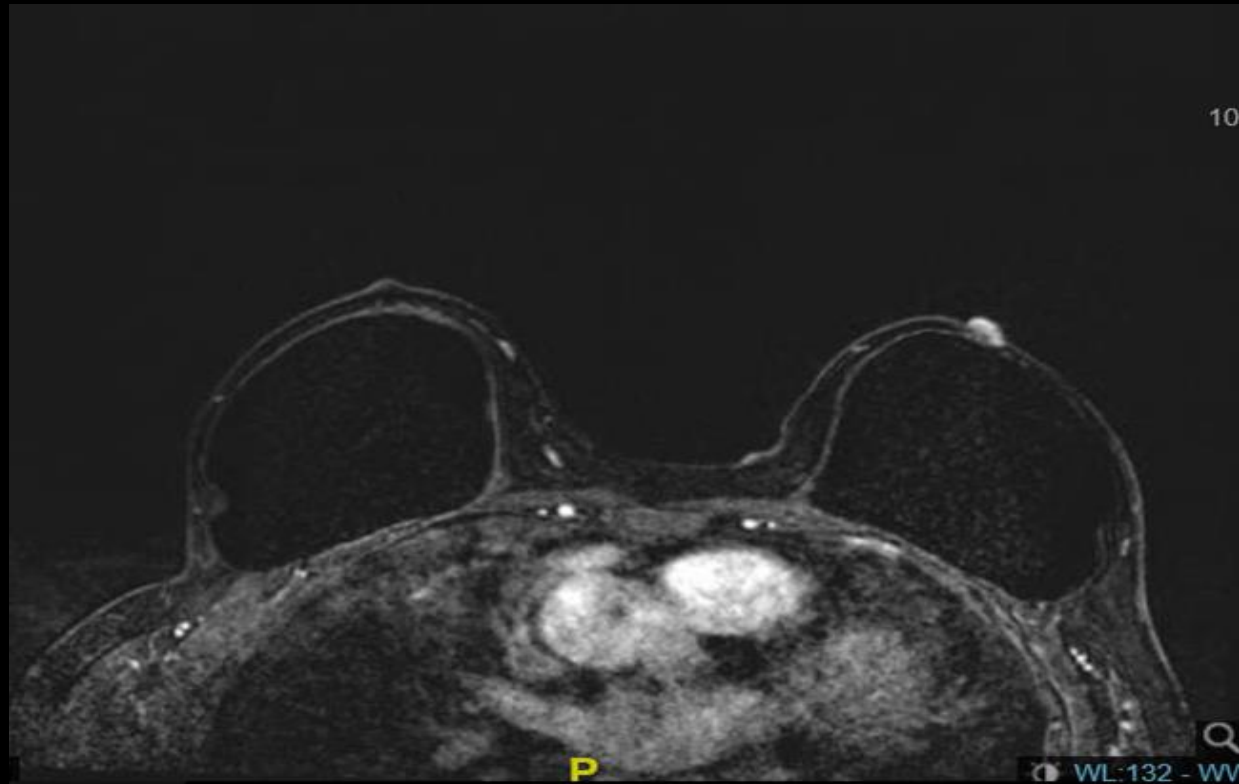

Findings: (unlabeled)



Given the patient's symptoms, further evaluation with breast MRI was recommended.

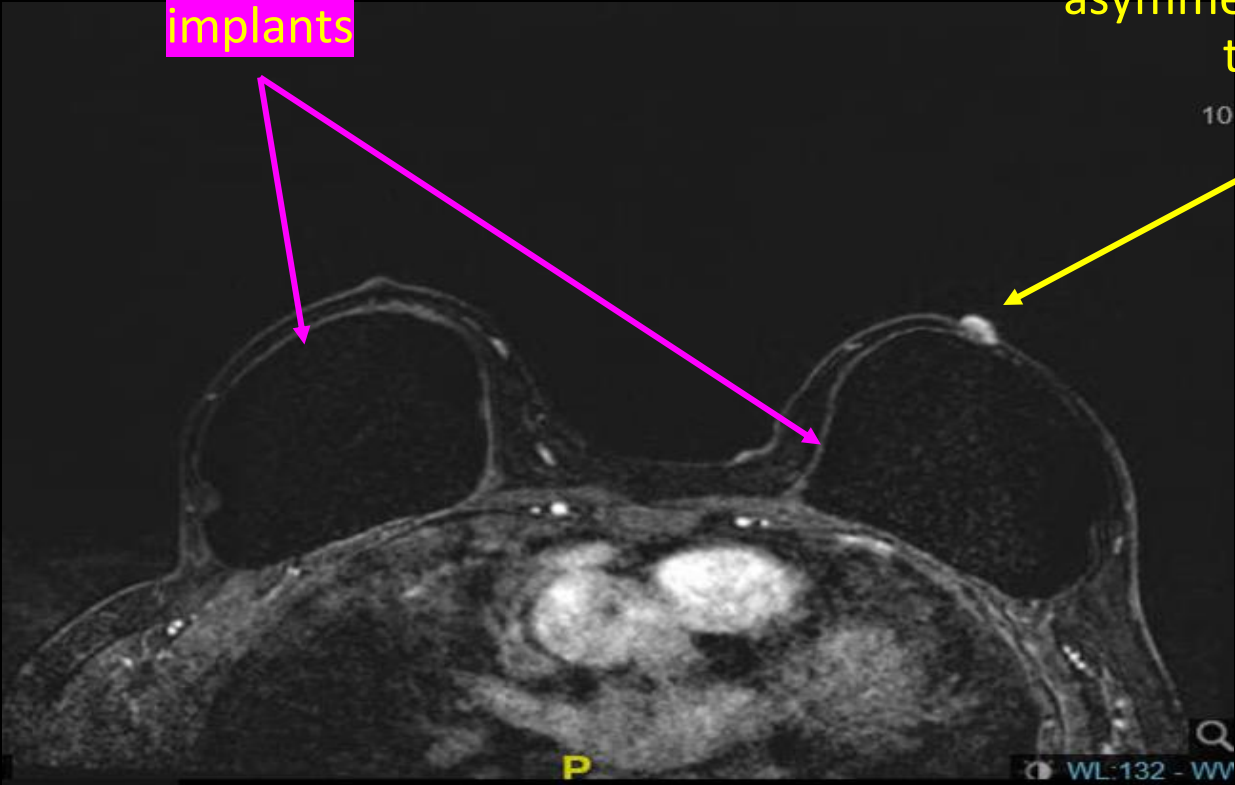
Findings: (unlabeled)



Findings: (labeled)

Bilateral breast implants

Mild enlargement and asymmetric enhancement of the left nipple



Final Dx:

Paget's Disease of the Nipple

Paget's Disease of the Nipple

- **Etiology:**
 - two theories:
 - *the Epidermotropic theory* (most widely accepted): ductal cancer cells that migrate along the basal membrane of the nipple form Paget cells.
 - *the Transformation theory*: Paget cells derive from malignant transformation of keratinocytes in the nipple.
- **Clinical Presentation:** ulcerated/crusted/scaling lesion on the nipple extending to the areola, retraction/hyperpigmentation of the nipple, pain, burning, itching
- **Differential Diagnosis:** atopic/contact dermatitis, florid papillomatosis of the nipple, pagetoid Bowen Disease, malignant melanoma, mycosis fungoides, Langerhans histiocytosis, nipple edema, ductal exocrine carcinoma

Paget's Disease of the Nipple: Diagnosis

- **Workup for a patient with PMHx breast cancer and mastectomy with new breast lump / pain:**
 - vital signs
 - physical exam
 - ultrasound / mammogram
 - Paget's Disease of the Nipple is difficult to observe under ultrasound / mammogram
- **Further workup for a patient with above history and nipple ulceration / crusting / scaling:**
 - MRI of the breast with and without contrast
 - Paget's Disease of the Nipple presents as asymmetric enhancement on MRI, most notably on subtraction imaging
 - histopathology
 - most patients with Paget's disease have underlying breast cancer, and the cells from the nipple are histologically similar to the associated invasive carcinoma

Paget's Disease of the Nipple: Treatment

- **Surgical:**
 - mastectomy with / without axillary dissection
 - gold standard
 - may follow with nipple reconstruction
 - breast conserving surgery
 - for patients without palpable mass and benign mammogram/low microvessel density
 - should be carefully considered because most underlying carcinomas are aggressive (HER2+)
- **Sentinel Lymph Node Biopsy:**
 - in all patients with invasive disease, and in patients with extensive ductal carcinoma in situ
- **Chemotherapy / hormonal therapy:**
 - adjuvant treatment depending on staging of the underlying carcinoma

References:

- Sandoval-Leon, Ana C., et al. "Paget's disease of the nipple." *Breast cancer research and treatment* 141.1 (2013): 1-12.
- Wang, Chenggang, Xiao Wang, and Rong Ma. "Diagnosis and surgical treatment of nipple adenoma." *ANZ Journal of Surgery* 85.6 (2015): 444-447.
- Samreen, Naziya, et al. "Magnetic resonance imaging in the evaluation of pathologic nipple discharge: indications and imaging findings." *The British Journal of Radiology* 94.1120 (2021): 20201013.
- Kumar, Pravin, et al. "Paget's disease of breast with an unusual presentation of involvement of overlying skin of breast: a case report." *International Surgery Journal* 7.12 (2020): 4231-4234.
- Kawase, Kazumi, et al. "Paget's disease of the breast: there is a role for breast-conserving therapy." *Annals of surgical oncology* 12.5 (2005): 391-397.