

AMSER Case of the Month

July 2023

32-year-old G12P8038 female with
uncertain pregnancy dating

Heather Cummins, MS3

University of Utah

Anne Kennedy, MBBCh

University of Utah

Jeffery D Olpin MD

University of Utah



Patient Presentation

- **HPI:** 32-year-old G12P8038 female with unknown estimated delivery date presented to establish obstetric care. Short interval between pregnancies with 6-month-old at home.
- **Gyn Hx:** Last menstrual period 03/04/2022 before previous pregnancy
- **PMHx:** Anxiety, depression, unspecified mood (affective) disorder
- **SHx:** One low-transverse C-section followed by several vaginal deliveries
- **Meds:** Lexapro 20 mg qday

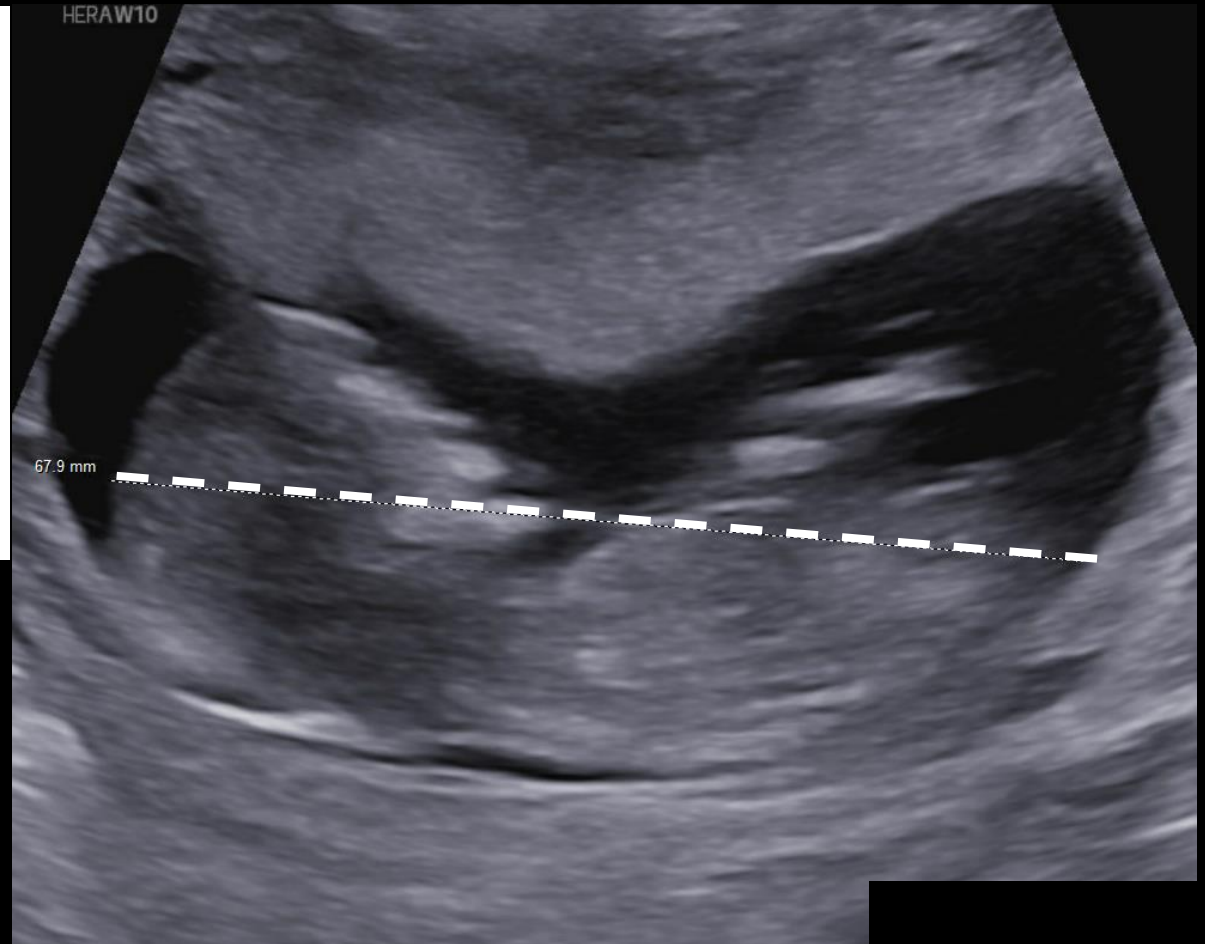
What Imaging Should We Order?

Recommendations

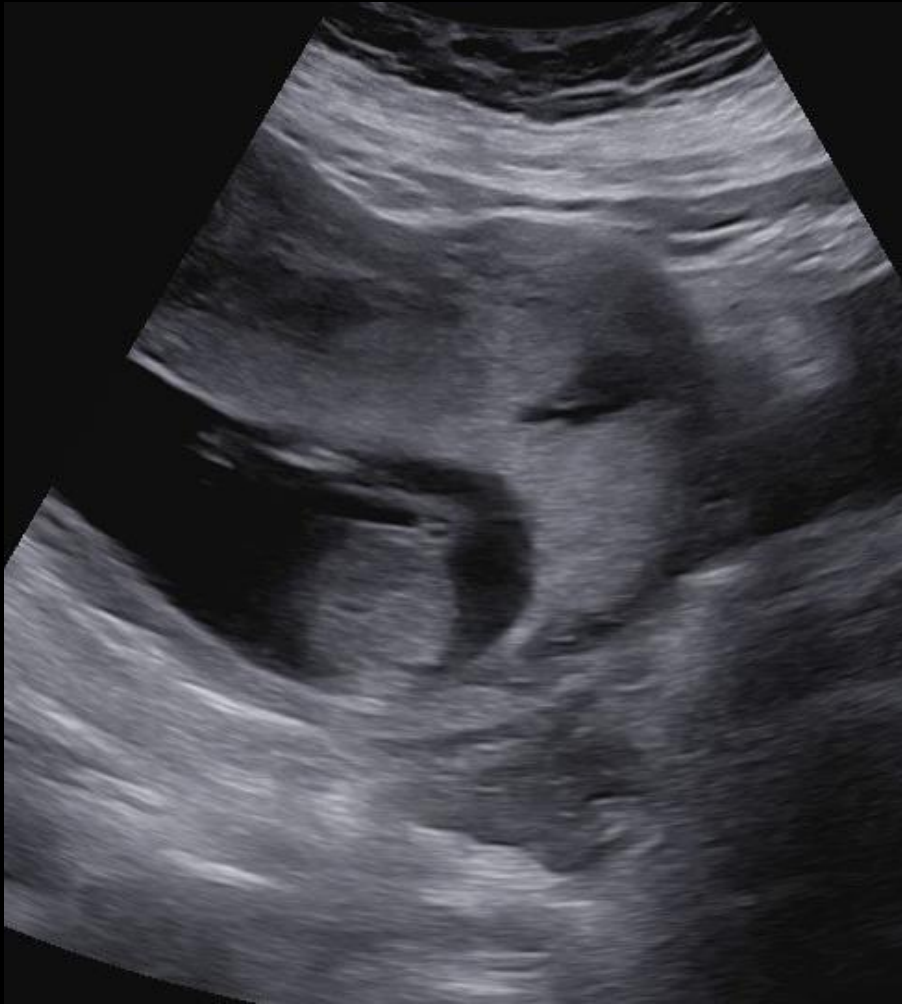The American College of Obstetricians and Gynecologists, the American Institute of Ultrasound in Medicine, and the Society for Maternal-Fetal Medicine make the following recommendations regarding the method for estimating gestational age and due date:

- Ultrasound measurement of the embryo or fetus in the first trimester (up to and including 13 6/7 weeks of gestation) is the most accurate method to establish or confirm gestational age.

Transabdominal ultrasound showed a single live intra-uterine pregnancy with crown-rump length of 68 mm indicating gestational age of 13 weeks.

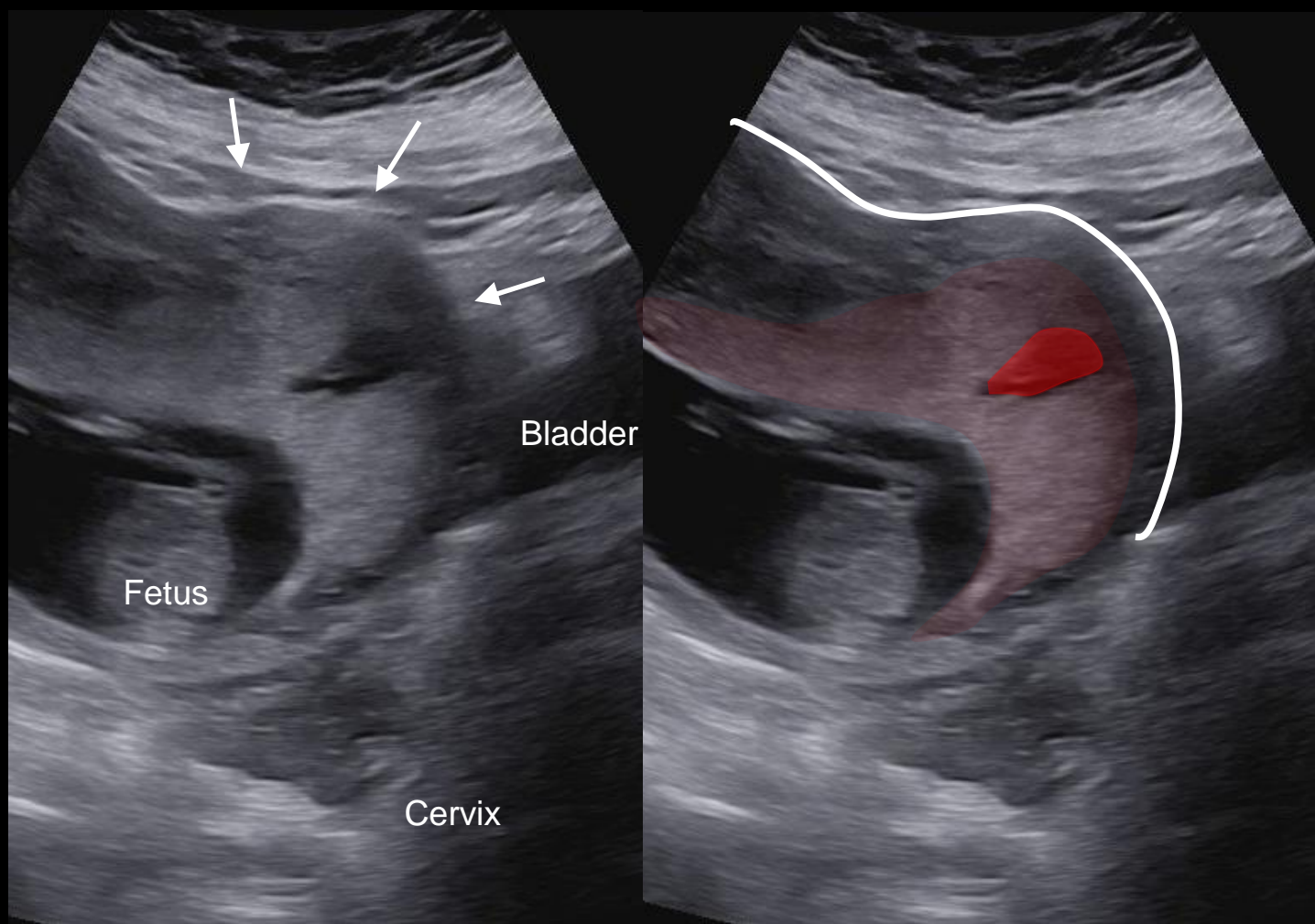


Additional Image -Unlabeled



- This is still image from a sagittal video sweep through the uterus.
- The history of one prior cesarean section was noted on the video screen.
- There are two very important findings that were not appreciated at the time of the scan. Can you identify them?

Additional Image - Labeled



- The midline sagittal image shows a prominent myometrial bulge (white line, arrows) causing distortion of the external uterine contour.
- There is a large vascular space (red) in the placenta (pink) which extends into the myometrial bulge.



On ultrasound, placental bulge has a sensitivity of 91.7% and a specificity of 76.9% for placenta accreta spectrum (PAS).¹

- The concerning findings were not appreciated, and the report simply established gestational age and recommended follow up at 18-20 weeks for routine anatomy scan.
- The report did not specifically address the patient risk factors for PAS; these included:
 - History of C-Section
 - Multiparity
 - Low anterior placental location
- Patient was lost to follow up until 28 weeks.

What Should Have Been Ordered?

Applicable ACR Appropriateness Criteria

Variant 2. High risk for placenta accreta spectrum disorder. Initial imaging

Procedure	Appropriateness Category	Relative Radiation Level
US duplex Doppler pregnant uterus	Usually Appropriate	0
US pregnant uterus transabdominal	Usually Appropriate	0
US pregnant uterus transvaginal	Usually Appropriate	0
MRI abdomen and pelvis without IV contrast	May Be Appropriate	0
MRI abdomen and pelvis without and with IV contrast	Usually Not Appropriate	0

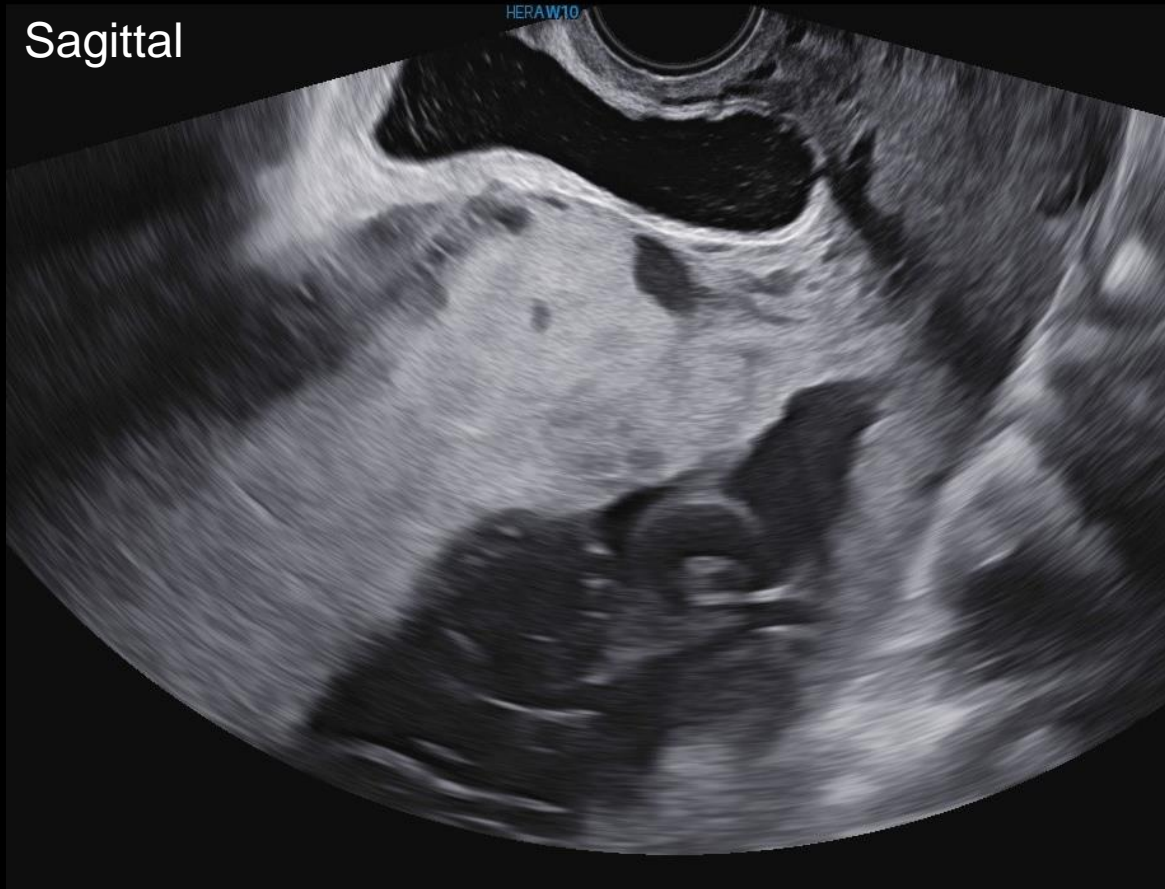
This was not ordered.

This was ordered.

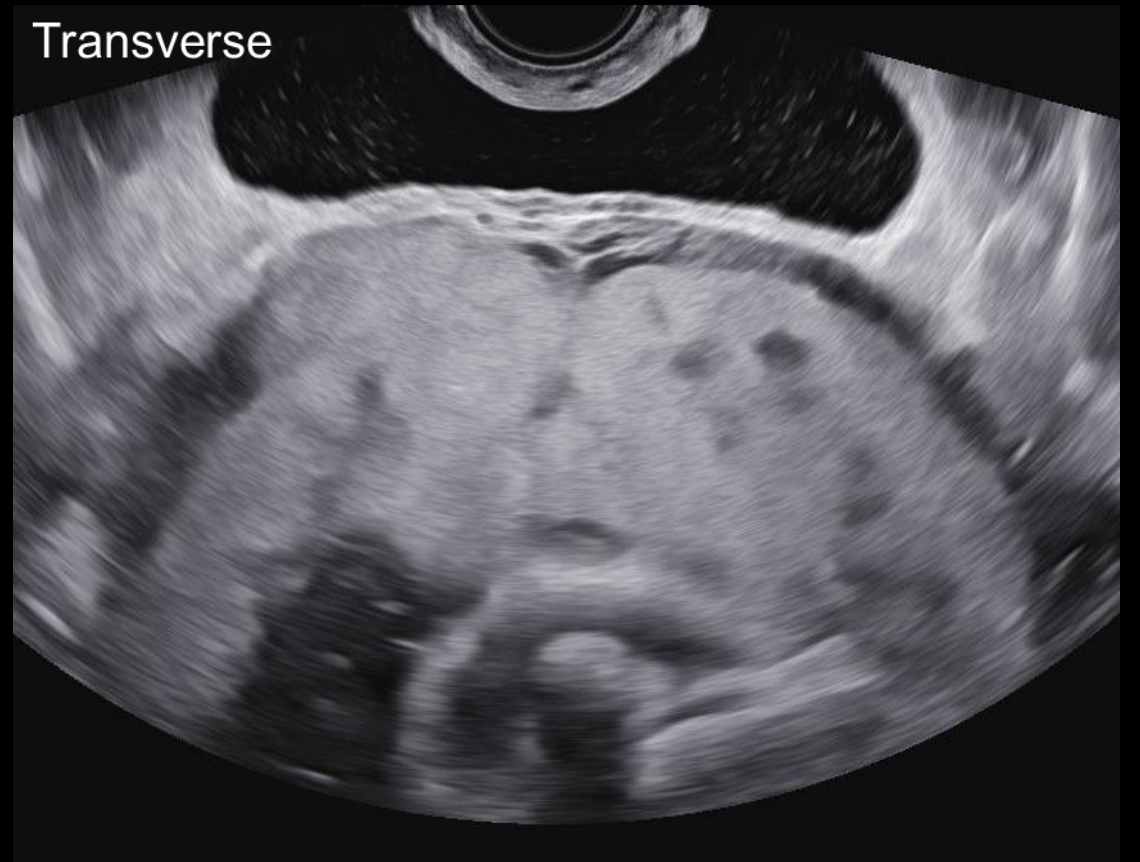This was not ordered.

28 Weeks Transvaginal Images - Unlabeled

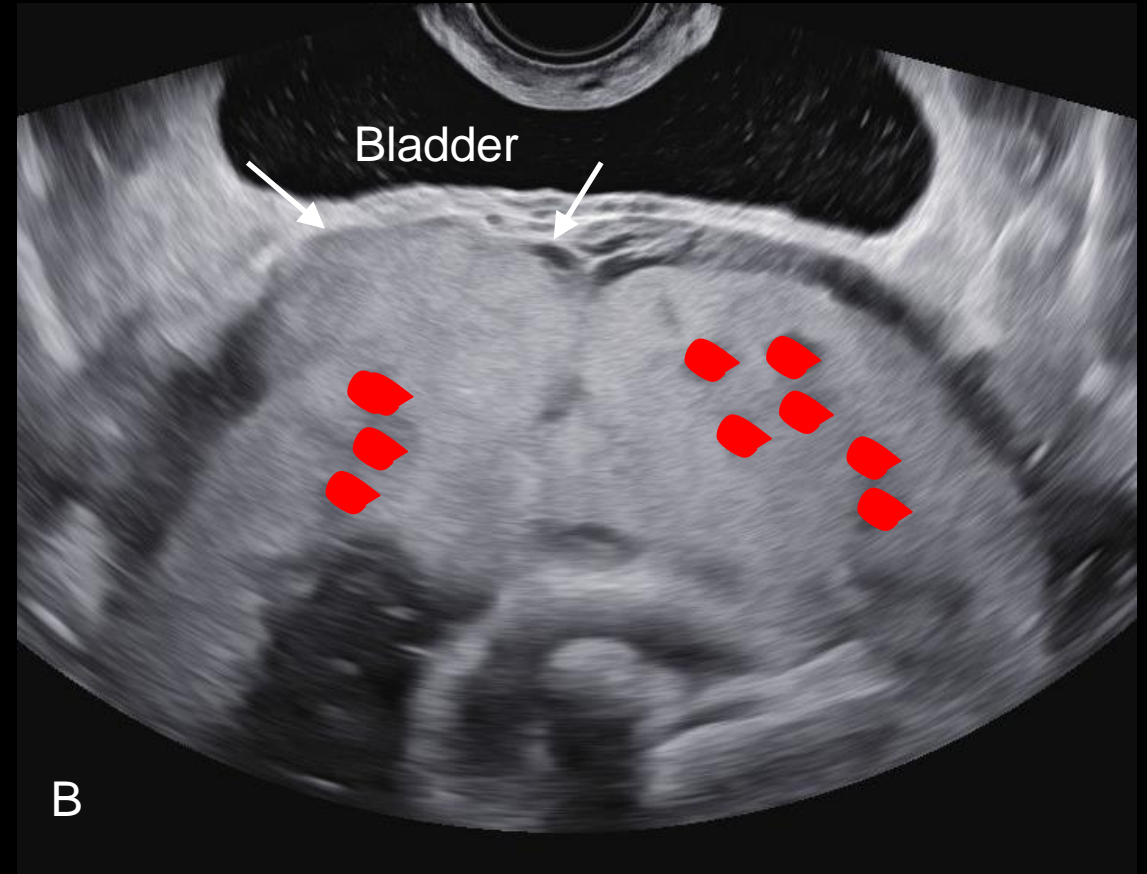
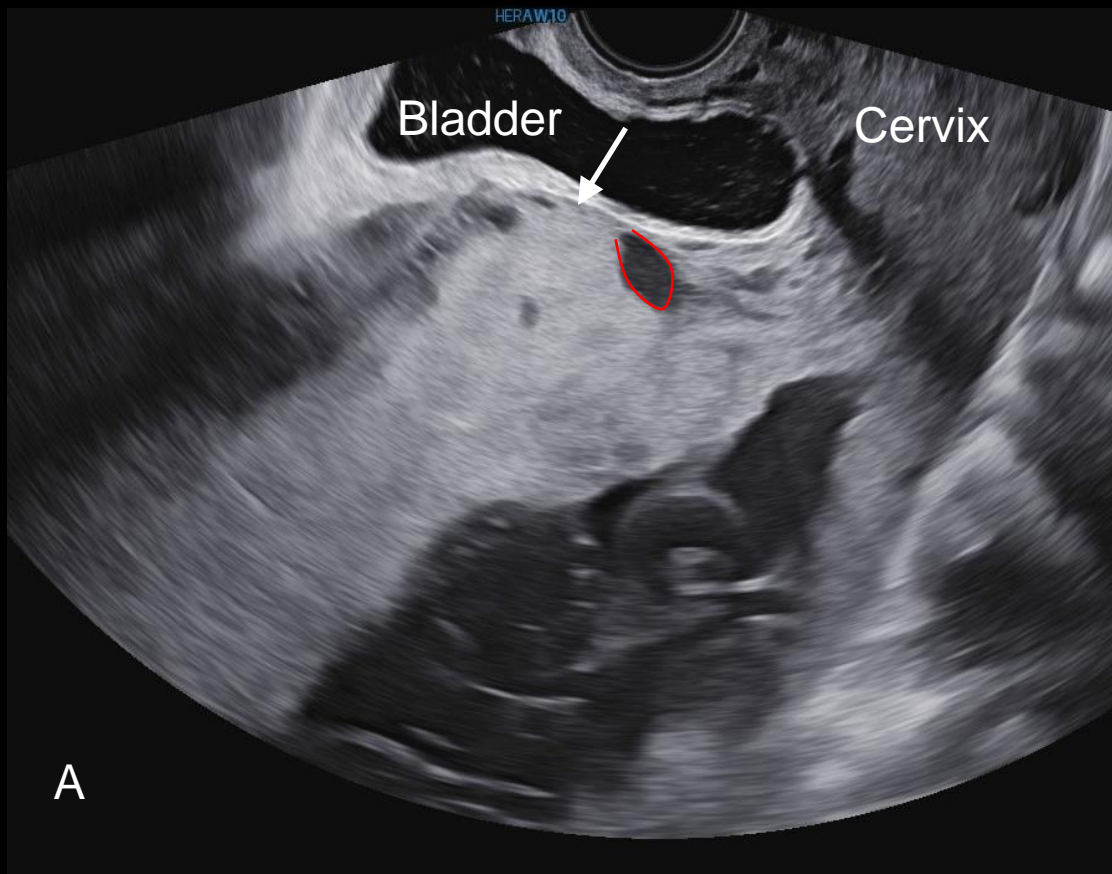
Sagittal



Transverse



28 Weeks Transvaginal Images -Labeled



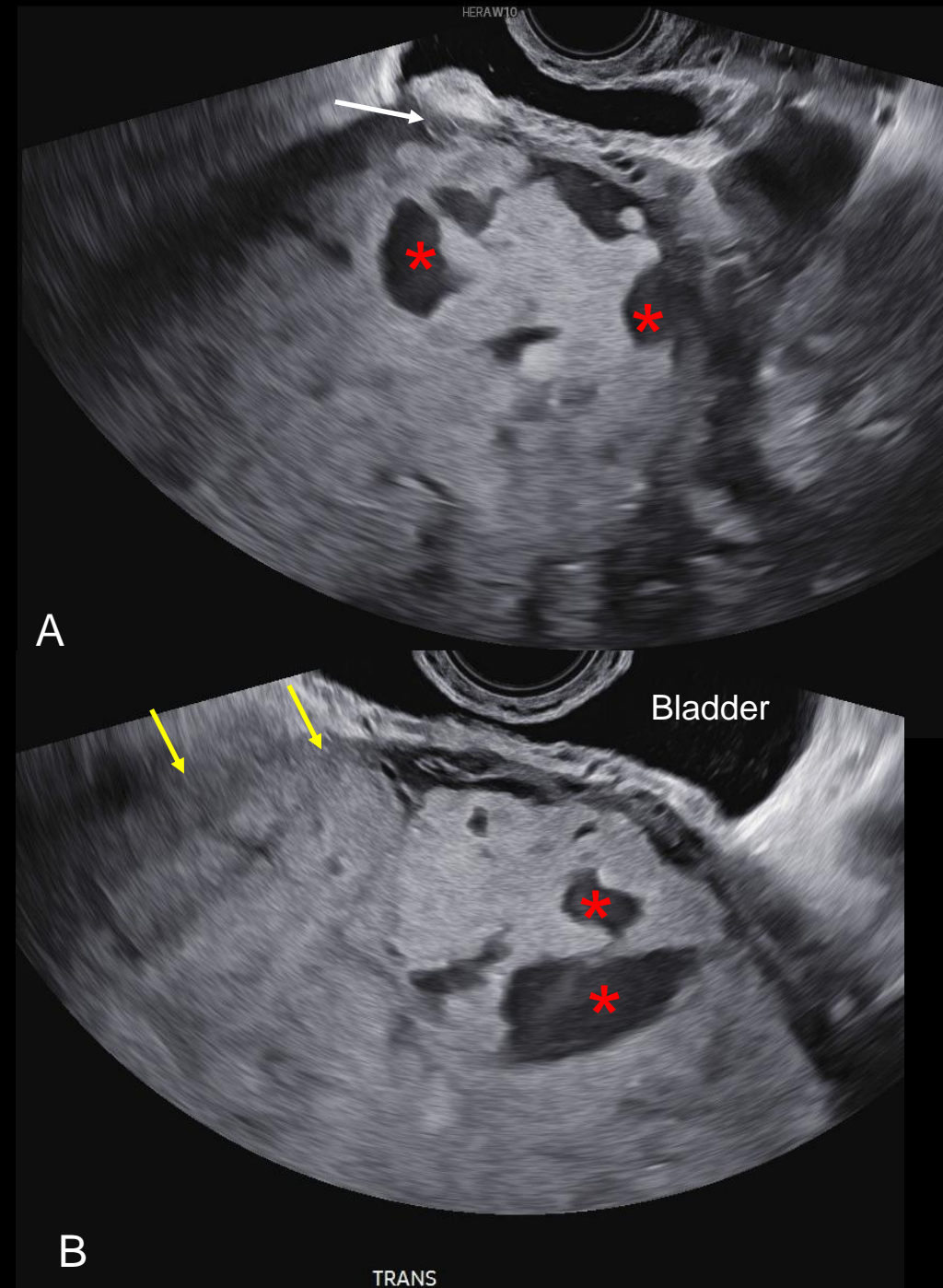
Sagittal (A) and transverse (B) transvaginal images show placenta previa with complete loss of the subplacental hypoechoic space with placenta abutting the bladder wall (arrows) and multiple areas of increased placental vascularity (red). The findings are highly concerning for placenta accreta spectrum.

Variant 3. Follow-up of placenta accreta spectrum disorder

Procedure	Appropriateness Category	Relative Radiation Level
US duplex Doppler pregnant uterus	Usually Appropriate	0
US pregnant uterus transabdominal	Usually Appropriate	0
US pregnant uterus transvaginal	Usually Appropriate	0
MRI abdomen and pelvis without IV contrast	May Be Appropriate	0
MRI abdomen and pelvis without and with IV contrast	Usually Not Appropriate	0

Follow up sagittal (A) and transverse (B) transvaginal images at 32 weeks show

- Multiple placental lacunae (asterisks)
- Loss of the clear zone (yellow arrow)
- Myometrial thinning (white arrow)



Final Dx:

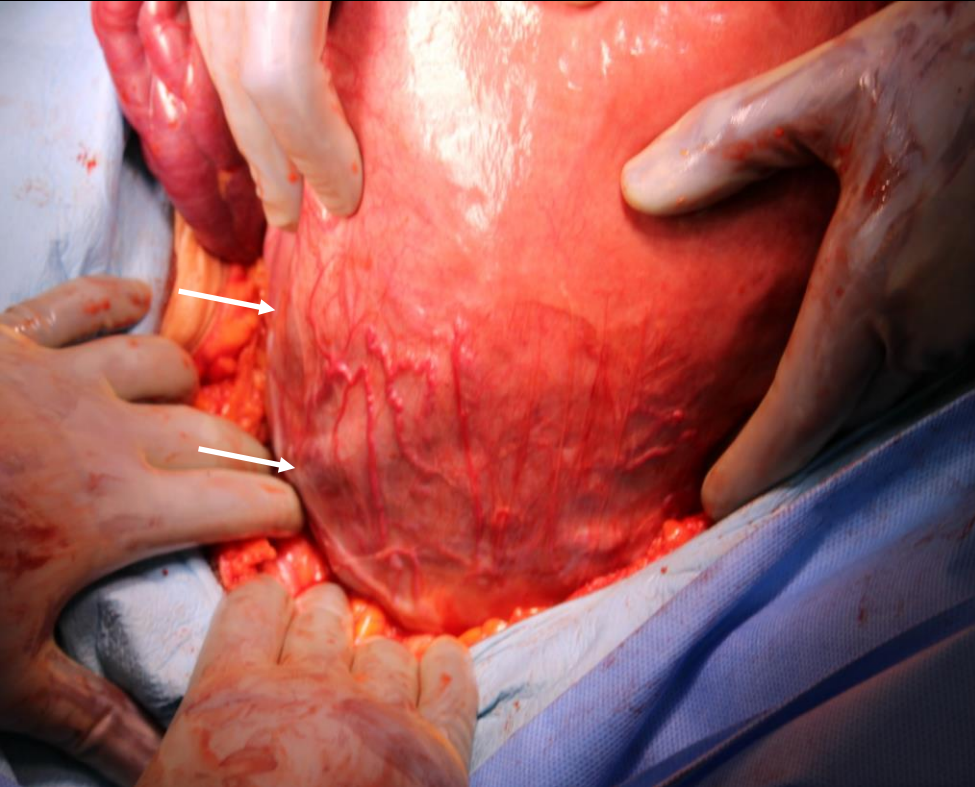
Placenta Accreta Spectrum

Diagnosis delayed by failure to recognize early findings

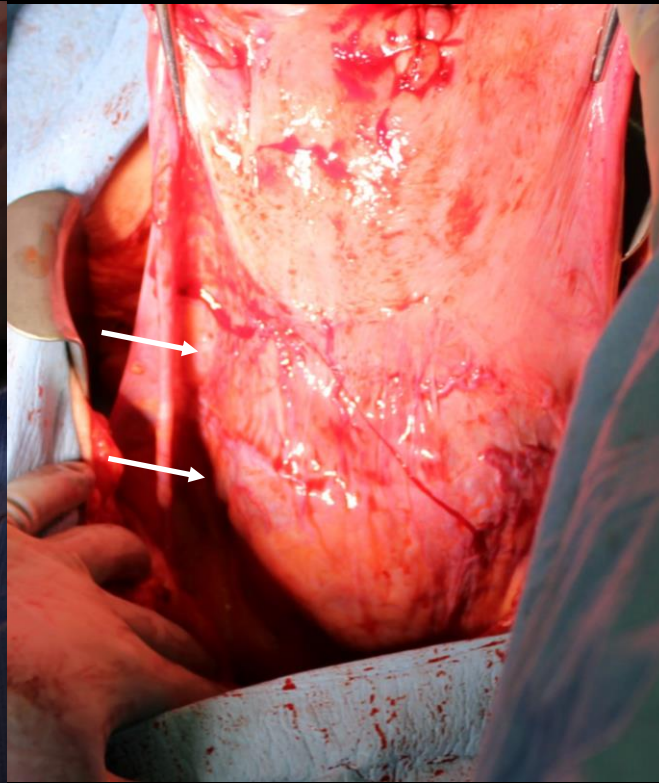
Outcome

- Patient underwent Cesarean section followed by total abdominal hysterectomy with bilateral salpingectomy.
- Placenta was found to be adherent through the uterine serosa.
 - Final grade: 3b
- Estimated blood loss: 1200 mL
- Patient and infant were discharged on post-operative day #4 with no complications.

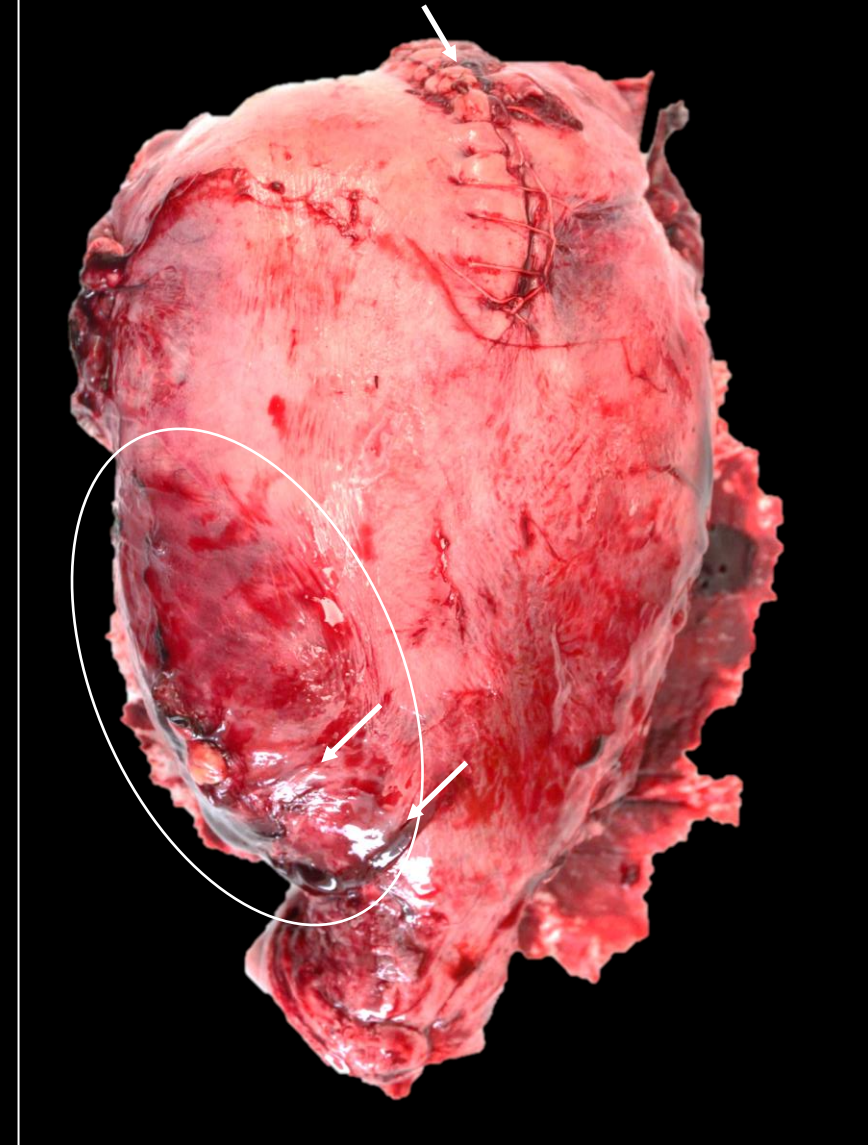Prior to delivery of the infant



Post delivery of infant



Hysterotomy for delivery of infant



Op note:

The bladder was adherent to the anterior wall of the uterus. Placenta appeared to be involving the myometrium to the level of the uterine serosa, particularly on the right, in the lower uterine segment which was notably hypervascular (arrows).

Hysterectomy specimen shows myometrial bulge and deflated vessels to right of midline (white oval).

Case Discussion

- Etiology of PAS

- Defects in the endometrial-myometrial interface allowing for deep placental anchoring and trophoblast infiltration
- Risk with placenta previa and increasing number of Cesarean deliveries²
 - 1 cesarean birth= 3%
 - 2 cesarean births= 11%
 - 3 cesarean births= 40%

- Epidemiology

- 0.17% of births in 2019 (0.003% in 1950's)³

Case Discussion

- **Clinical Presentation**

- Ideally, PAS is found via ultrasound while the patient is asymptomatic.
- Otherwise, the first manifestation is often profuse, life-threatening hemorrhage at the time of delivery and attempted placental separation.

- **Diagnosis**

- Ultrasound
- High index of suspicion
- Negative imaging does not exclude PAS in high-risk setting



ACOG recommends that patients with risk factors for PAS should be evaluated by healthcare providers with experience and expertise in diagnosis of placenta accreta by ultrasound.

Case Discussion

- **Management**

- If previsible: Discussion of pregnancy termination vs. expectant management
- Ultrasound examinations at 18-20, 28-30, and 32-34 weeks in asymptomatic patients
- Delivery at 34 0/7-35 6/7 weeks via scheduled cesarean delivery with hysterectomy
- Conservative management with uterine preservation has a failure rate of 7-44% depending on the severity of placenta accreta spectrum²
 - Trial currently enrolling

- **Cesarean scar ectopic pregnancy is a precursor**

- SMFM recommends termination

Summary

- Patients with a history of multiparity, prior C-section, and placenta previa are at higher risk of PAS.
- ACR Appropriateness Criteria recommends transabdominal ultrasound, transvaginal ultrasound, and Doppler ultrasound for screening patients at high risk of PAS.
- Patients at risk of PAS should be evaluated by healthcare professionals with experience and expertise in diagnosing PAS.
- Cesarean Scar Pregnancy (CSP) is a precursor for PAS and screening for CSP at 5-7 weeks should be recommended.

References:

1. Thiravit S, Ma K, Goldman I, et al. Role of Ultrasound and MRI in Diagnosis of Severe Placenta Accreta Spectrum Disorder: An Intraindividual Assessment With Emphasis on Placental Bulge. *Am J Roentgenol*. 2021;217(6):1377-1388. doi:10.2214/AJR.21.25581
2. Placenta accreta spectrum. Obstetric Care Consensus No. 7. American College of Obstetricians and Gynecologists. *Obstet Gynecol* 2018;132:e259–75.
3. Silver R. Placenta accreta spectrum: Clinical features, diagnosis, and potential consequences. UpToDate. Published online October 14, 2022. https://www.uptodate.com/contents/placenta-accreta-spectrum-clinical-features-diagnosis-and-potential-consequences?search=placenta%20accreta%20spectrum&source=search_result&selectedTitle=1~62&usage_type=default&display_rank=1
4. American College of Radiology ACR Appropriateness Criteria Placenta Accreta Spectrum Disorder <https://acsearch.acr.org/docs/3102403/Narrative/>