

AMSER Case of the Month

September 2023

28-year-old male presenting with pain in right index and middle fingers

Pace Woods, MD

Virginia Commonwealth University School of Medicine

Jaruwit Ty Rergyamdee, MD

Virginia Commonwealth University School of Medicine

Wali Danish, MD

Virginia Commonwealth University School of Medicine

Patient Presentation

- **HPI:** A previously healthy 28-year-old, right-hand-dominant male presents to orthopedic clinic for 6 weeks of severe pain in his right index and middle finger. The patient smokes, works as a welder, and acknowledges hitting his palm against things frequently at work. He attempted to rest the hand with temporary relief, but symptoms return when he attempts to work with the hand. He also notes that the index and middle finger will occasionally become pale for up to an hour. He received imaging studies at an outside hospital and was placed on a 12-day Medrol taper without relief. Patient is also taking Amlodipine 5 mg daily and Gabapentin 100 mg twice daily without relief.

Patient Presentation cont.

- **Past Medical/Surgical Hx:** Acid reflux, thumb arthroscopy, previous shoulder surgery (unclear of exact procedure)
- **Social Hx:** Smokes 0.5 packs per day, drinks 7 standard alcoholic drinks per week, no drug usage
- **Daily Medications:** Amlodipine 5 mg, amphetamine-dextroamphetamine 25 mg, Dexilant 60 mg, Escitalopram 10 mg, Gabapentin 100 mg
- **Vitals:** Stable, unremarkable

Patient Presentation cont.

- **Physical Exam:** Well-developed, well-nourished. Does not appear to be in significant distress.
- **Right upper extremity:** Splinter hemorrhages noted to the right index and middle fingernails. All fingers are pink but with 3-4 second capillary refill in the middle and index fingers as opposed to his thumb and little fingers which are ~2 seconds. The index and middle finger are hypersensitive to palpation. Able to make a good fist. Strength testing deferred due to discomfort. Strong palpable radial artery pulse and a palpable pulsatile mass overlying the right hypothenar eminence.

Pertinent Labs/Findings

- **Labs:** Complete blood cell count is unremarkable. Prothrombin time, INR, aPTT, antithrombin activity, protein C/S activity, and Factor 8/9 assays are all unremarkable. Cardiolipin antibody testing returned negative. ANA, homocysteine, rheumatoid factor, methylmalonic factor and CRP are all negative or within normal limits.
- **Outside imaging studies:** X-ray of right hand from 2 weeks prior was unremarkable. See following slides for further studies.

What Initial Imaging Should We Order?

Select the applicable ACR Appropriateness Criteria

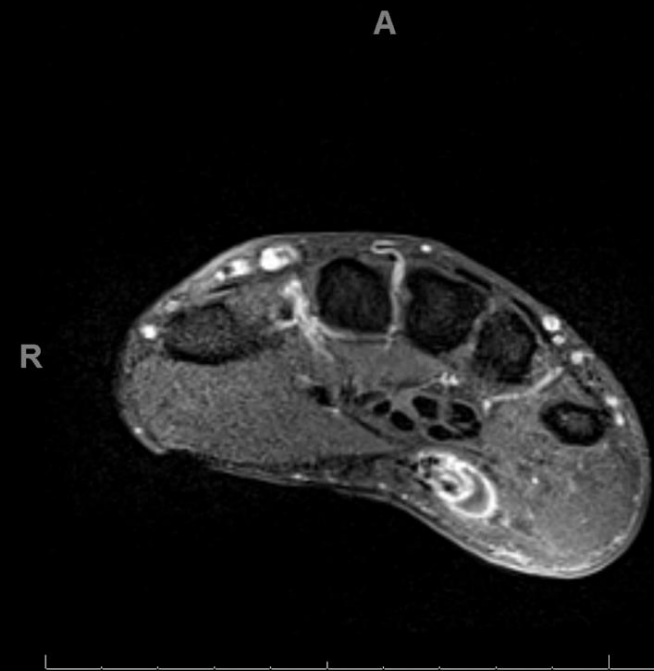
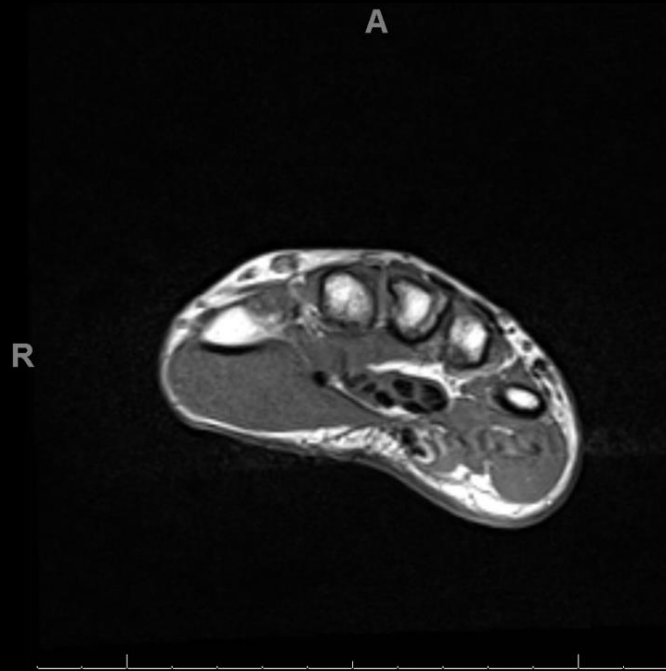
Variant 9:

Chronic wrist pain. Palpable mass or suspected occult ganglion cyst. Radiographs normal or nonspecific. Next study.

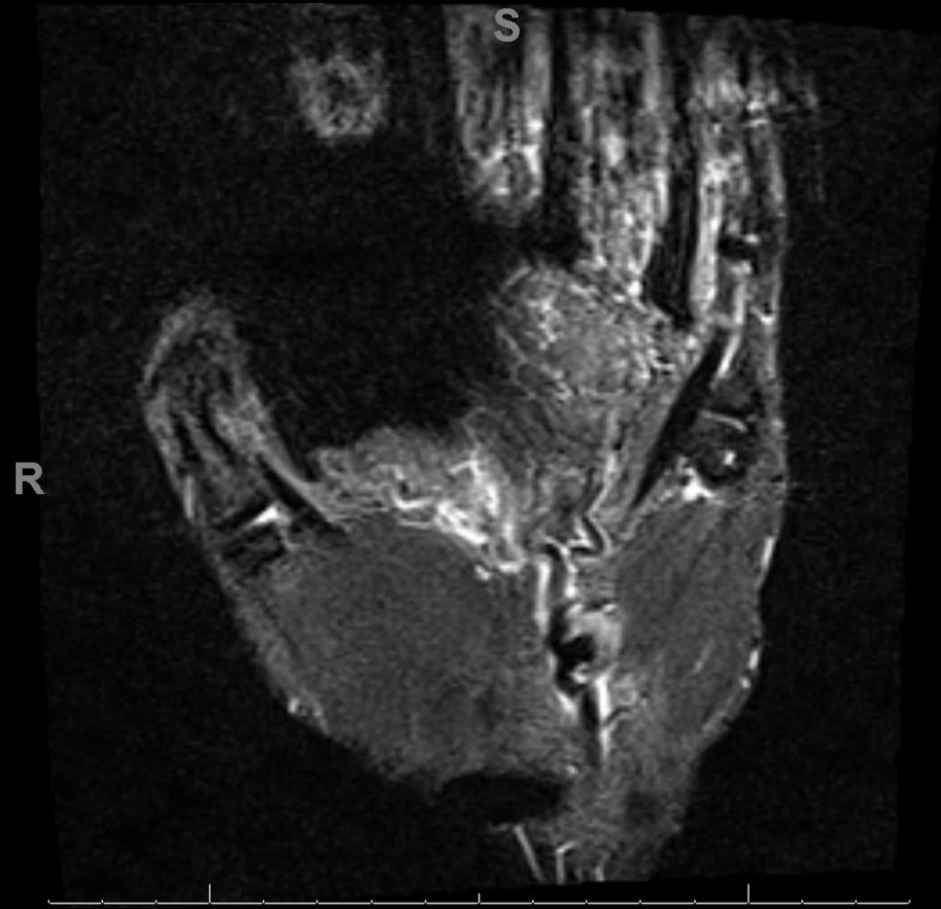
Procedure	Appropriateness Category	Relative Radiation Level
MRI wrist without IV contrast	Usually Appropriate	0
MRI wrist without and with IV contrast	Usually Appropriate	0
US wrist	Usually Appropriate	0
MR arthrography wrist	Usually Not Appropriate	0
CT wrist without IV contrast	Usually Not Appropriate	☼
CT wrist with IV contrast	Usually Not Appropriate	☼
CT wrist without and with IV contrast	Usually Not Appropriate	☼
CT arthrography wrist	Usually Not Appropriate	☼
Radiographic arthrography wrist	Usually Not Appropriate	☼
Bone scan wrist	Usually Not Appropriate	☼☼☼

This imaging modality was ordered by the outside radiologist

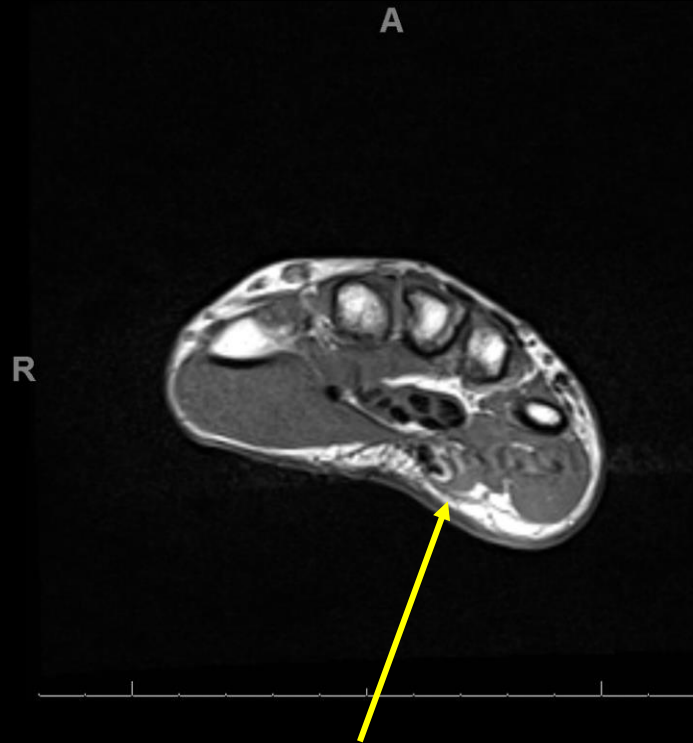
Findings (unlabeled)



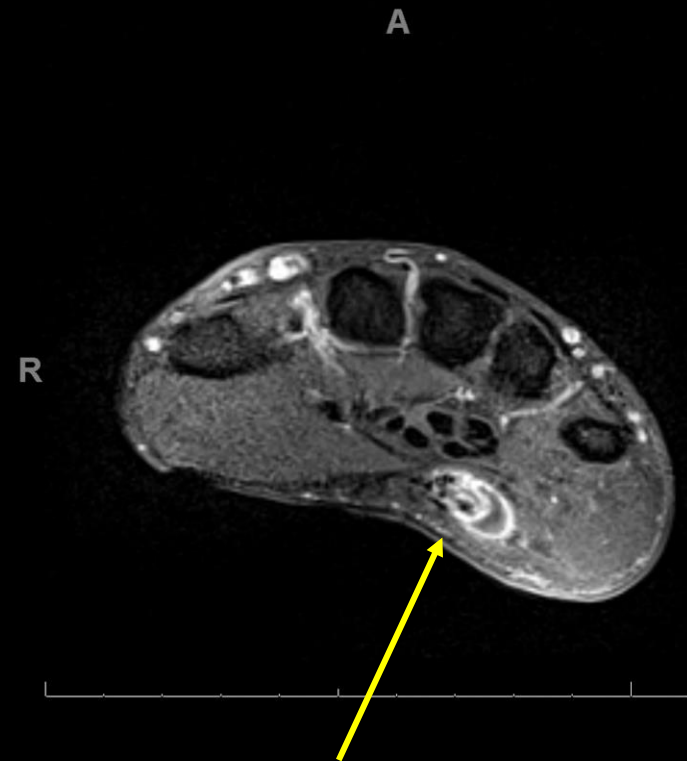
Findings (unlabeled)



Findings (labeled)

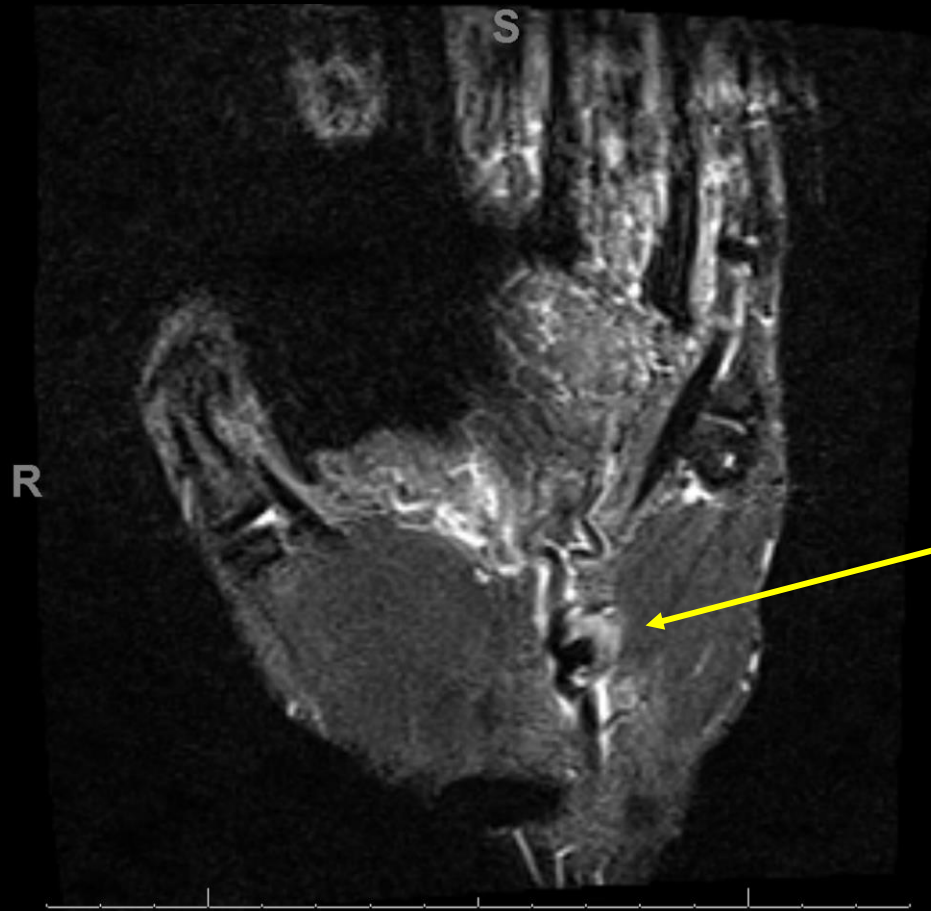


Axial T1 pre-contrast image showing a 1.1 x 0.9 x 1.8 cm heterogenous mass in Guyon's canal medial to the ulnar artery



Axial T1 post-contrast image utilizing fat saturation showing peripheral enhancement

Findings (labeled)

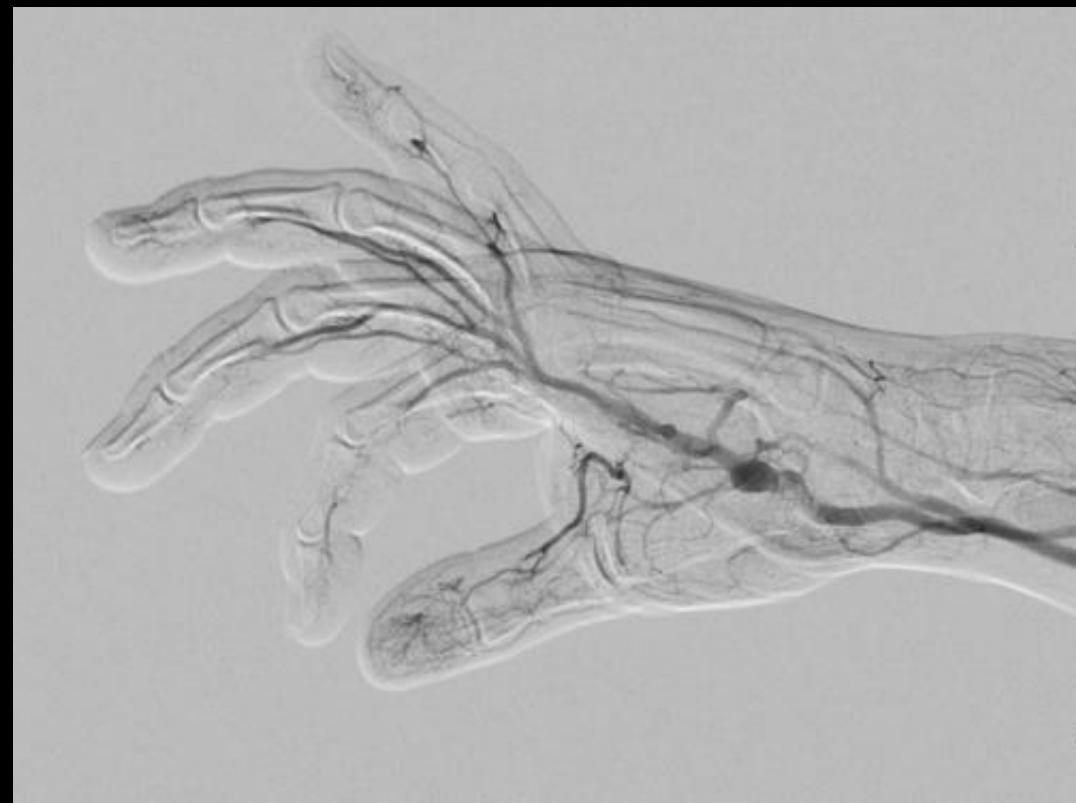
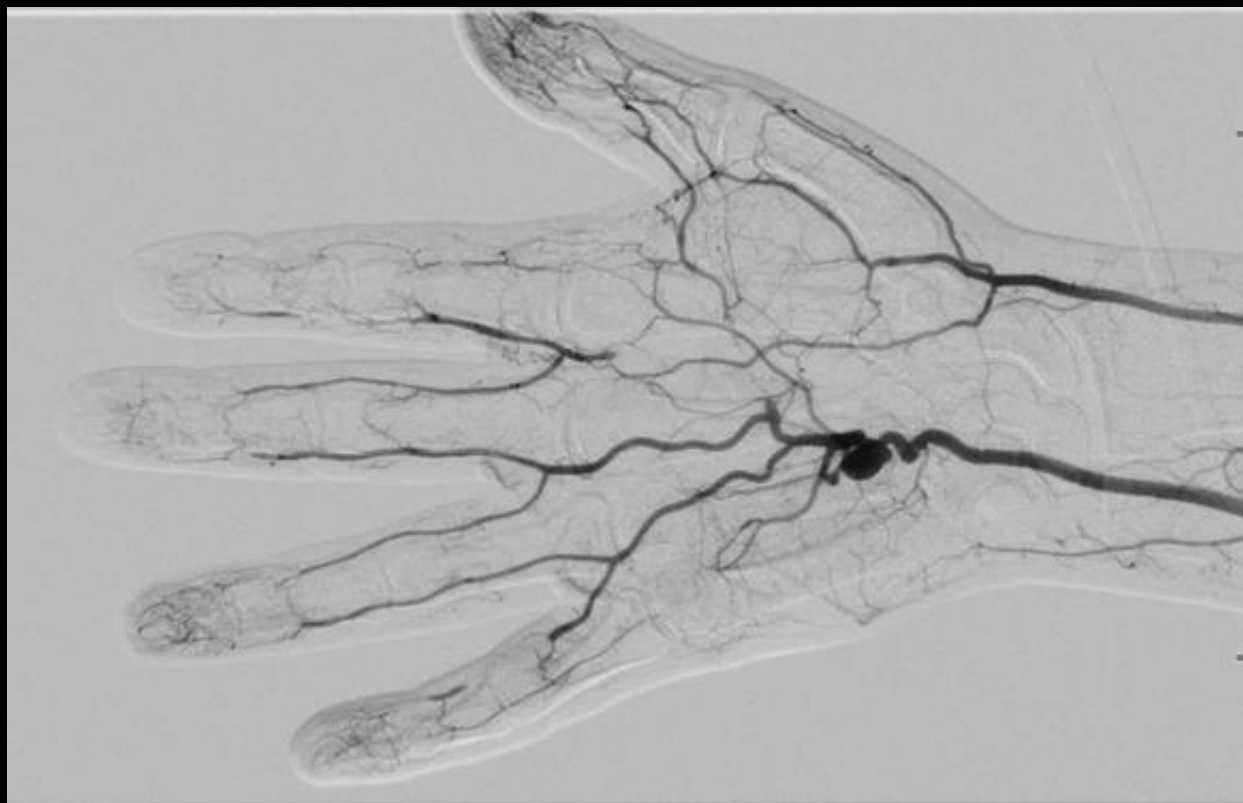
Coronal STIR image showing outpouching of the ulnar artery extending into the lesion

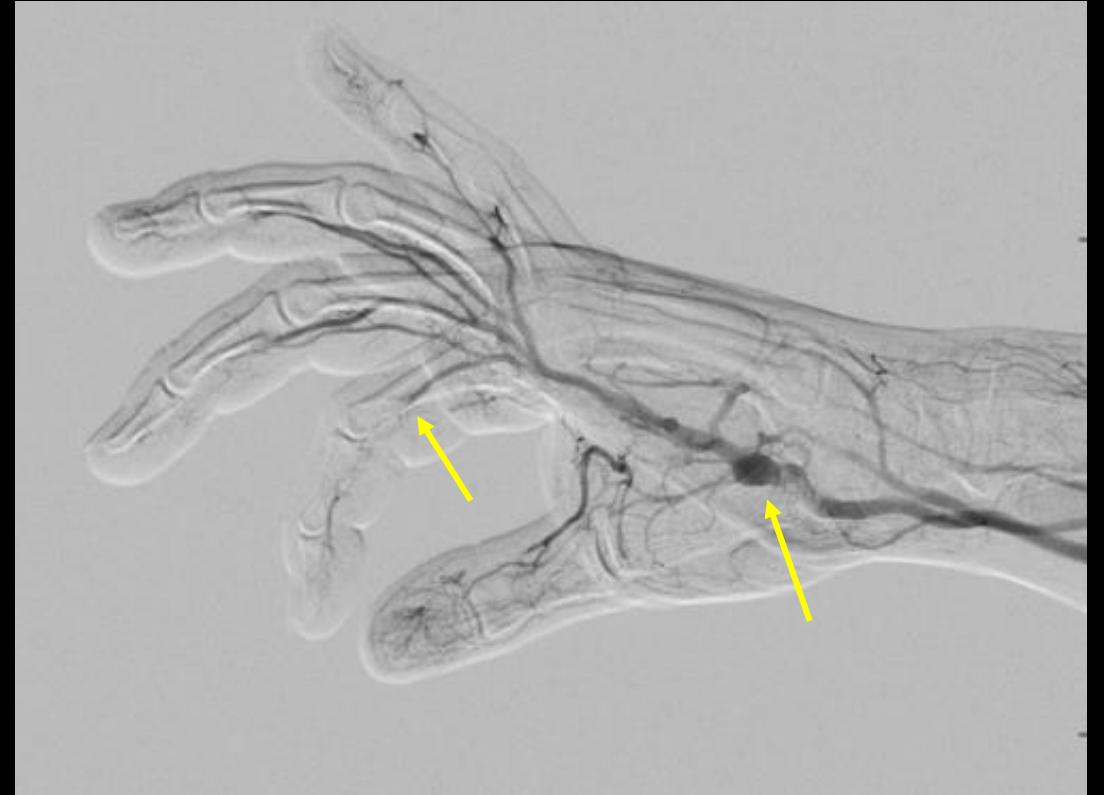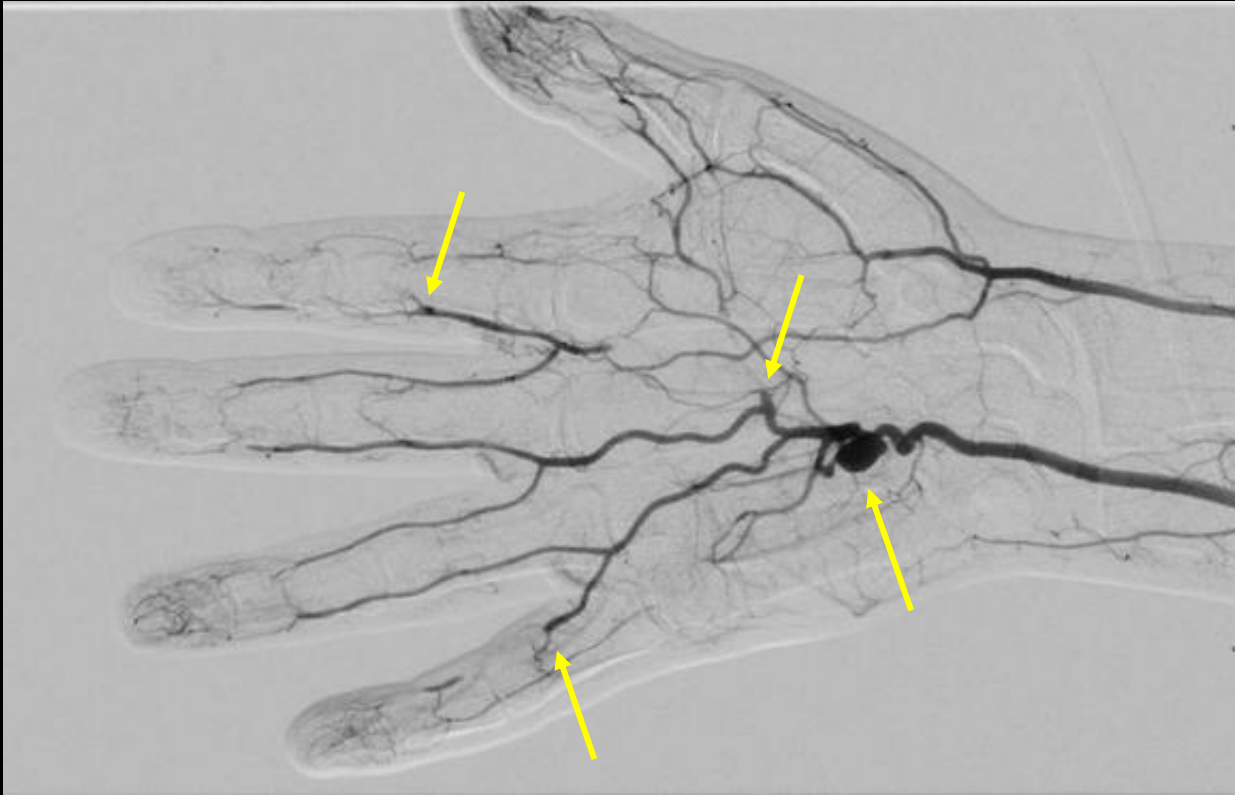
Findings and Follow Up Imaging

- Images from the outside hospital were reviewed, with MRI findings concerning for a non-enhancing mass noted in the region of the hypothenar eminence., which was favored to represent an aneurysm/pseudoaneurysm.
- The patient was scheduled for follow up arteriogram of his right upper extremity for further evaluation. He was told to stop smoking, had his amlodipine switched to nifedipine, and was recommended aspirin and clopidogrel.

Findings (unlabeled)



Findings (labeled)



Right upper extremity angiography. Ulnar artery appears as dominant supply to the digits. There is a 1.1 cm aneurysm arising from the ulnar artery at the level of the metacarpal base. Superficial palmar arch and multiple digital arteries demonstrating short segment occlusions.

Findings/Follow Up

- Arteriogram of the right upper extremity showing an aneurysm of the ulnar artery. Also demonstrating distal segmental occlusion of the digits, likely responsible for patient's pain and pallor to his index and middle finger.
- The patient was scheduled for a follow up appointment with orthopedics and possible surgical planning. He did not show up to his appointment and there are no further records of his decisions for treatment.

Final Dx:

Hypothenar Hammer Syndrome resulting in Ulnar
Artery Aneurysm

Case Discussion

Definition: The term “hypothenar hammer syndrome” was first described by Conn et al in 1970. The syndrome is caused by repeated blunt trauma to the hypothenar region of the hand. This eventually causes ulnar artery damage, which may lead to aneurysm and/or emboli formation.

Epidemiology: Most common in men around 40 years of age involving the dominant hand. Seen in those whose occupations involve tool usage which places repetitive pressure through hammer. Especially seen in workers using vibration-based tools, where one study found incidence of those utilizing such tools to be as high as 7%.

Case Discussion

Clinical Features: Physical exam may consist of: tenderness overlying the hypothenar region, pulsatile mass if aneurysm is present, episodic blanching or pallor to the 2nd, 3rd, 4th or 5th digits. Pulp wasting or splinter hemorrhages are sometimes present in the digits, and severe cases may lead to ulceration or gangrene.

Diagnosis: The standard test for diagnosis is through upper extremity angiography. This allows the physician to locate the occlusion, evaluate the ulnar artery for malformation/damage, and look for distal digital artery emboli.

Radiographic Features: Irregular appearance of the distal ulnar artery, aneurysm formation, occlusion of the ulnar artery overlying the hook of hamate, occlusion of distal digital arteries in an ulnar artery distribution.

Case Discussion

Differential Diagnosis: Differential for digital ischemia include vasculitis, arterial emboli from cardiac sources, atherosclerosis with secondary thrombosis and thoracic outlet syndrome. Unilateral findings help distinguish this syndrome from other causes of digital ischemia such as Raynaud's disease/phenomenon or thromboangiitis obliterans.

Treatment: Conservation options include: smoking cessation, avoidance of further trauma (occupation change), wear padded gloves, calcium channel blockers for vasospasm, antiplatelets or anticoagulation. In acute and severe cases, surgical options include: arterial ligation (with intact radial/palmar arch), resection of ulnar artery/aneurysm with anastomosis, resection with vascular reconstruction utilizing graft.

References:

1. Ablett CT, Hackett LA. Hypothenar hammer syndrome: case reports and brief review. *Clin Med Res*. 2008 May;6(1):3-8. doi: 10.3121/cm.2008.775. PMID: 18591371; PMCID: PMC2442026.
2. Coffman JD. Vasospastic diseases. In: Young JR, Graor RA, Olin JW, Bartholomew JR, eds. *Peripheral vascular diseases*. St. Louis, MO: Mosby-Year Book; 1991. 361–377.
3. 5. Conn J Jr, Bergan JJ, Bell JL. Hand ischemia: hypothenar hammer syndrome. *Proc Inst Med Chic* 1970;28:83.
4. Kaji H, Honma H, Usui M, Yasuno Y, Saito K. Hypothenar hammer syndrome in workers occupationally exposed to vibrating tools. *J Hand Surg [Br]* 1993;18:761–766.
5. Pineda CJ, Weisman MH, Bookstein JJ, Saltzstein SL. Hypothenar hammer syndrome. Form of reversible Raynaud's phenomenon. *Am J Med* 1985;79:561–570.
6. Vayssairat M, Debure C, Cormier JM, Bruneval P, Laurian C, Juillet Y. Hypothenar hammer syndrome: seventeen cases with long-term follow-up. *J Vasc Surg* 1987;5:838–843.