AMSER Case of the Month

December 2025

51-year-old Woman with Post-Transplant Lymphoproliferative Disorder (PTLD) – Diffuse Large B-Cell Lymphoma Subtype

Deepti Verma, MS3
Penn State College of Medicine
Janelle Welkie, MD
Penn State Health Milton Hershey Medical Center, Department of Radiology
Matthew Capodarco, MD
Penn State Health Milton Hershey Medical Center, Department of Radiology

PennState College of Medicine

AMSER

Patient Presentation

History of Present Illness: 51-year-old woman with history of autoimmune hepatitis, status post orthotopic liver transplantation in April 1990 at age 16; maintained on tacrolimus for over 30 years; prednisone discontinued in 2022; no episodes of transplant rejection.

August 2024: Developed acute onset of severe, constant left-sided abdominal pain without nausea, vomiting, diarrhea, or constipation; no fevers, night sweats, weight loss, early satiety, GI bleeding, or constitutional symptoms.

Past Medical History: Autoimmune hepatitis → liver transplant; tacrolimus for >30 years, steroids until 2022; no transplant rejection; March 2023 tacrolimus level 9.6 ng/mL; Hx of ulcerative colitis; no prior malignancies.

Physical exam: ECOG 0, KPS 90; well-appearing, abdomen soft and non-distended, no tenderness, no hepatosplenomegaly, no palpable masses; Cardiopulmonary exam unremarkable; No lymphadenopathy in neck, axillae, or groin.

AMSER

What Imaging Should We Order? (6,7)

AMSER

Select the applicable ACR Appropriateness Criteria

Variant 1: **Suspected small-bowel obstruction. Acute presentation. Initial imaging.**

Procedure	Appropriateness Category	Relative Radiation Level
CT abdomen and pelvis with IV contrast	Usually Appropriate	☢☢☢
CT abdomen and pelvis without IV contrast	May Be Appropriate	☢☢☢
MRI abdomen and pelvis without and with IV contrast	May Be Appropriate	O
Radiography abdomen and pelvis	May Be Appropriate (Disagreement)	☢☢☢
Fluoroscopy small bowel follow-through	May Be Appropriate	☢☢☢
MRI abdomen and pelvis without IV contrast	May Be Appropriate	O
CT abdomen and pelvis without and with IV contrast	Usually Not Appropriate	☢☢☢☢
CT enteroclysis	Usually Not Appropriate	☢☢☢☢
CT enterography	Usually Not Appropriate	☢☢☢☢
MR enterography	Usually Not Appropriate	O
US abdomen and pelvis	Usually Not Appropriate	O
Fluoroscopy small bowel enteroclysis	Usually Not Appropriate	☢☢☢
MR enteroclysis	Usually Not Appropriate	O

Variant 2: **Suspected intermittent or low-grade small-bowel obstruction. Indolent presentation.**

Procedure	Appropriateness Category	Relative Radiation Level
CT abdomen and pelvis with IV contrast	Usually Appropriate	☢☢☢
CT enterography	Usually Appropriate	☢☢☢☢
CT enteroclysis	May Be Appropriate	☢☢☢☢
MR enterography	May Be Appropriate	O
CT abdomen and pelvis without IV contrast	May Be Appropriate	☢☢☢
Fluoroscopy small bowel enteroclysis	May Be Appropriate	☢☢☢
Fluoroscopy small bowel follow-through	May Be Appropriate	☢☢☢
MRI abdomen and pelvis without and with IV contrast	May Be Appropriate	O
MR enteroclysis	May Be Appropriate	O
MRI abdomen and pelvis without IV contrast	May Be Appropriate	O
CT abdomen and pelvis without and with IV contrast	Usually Not Appropriate	☢☢☢☢
Radiography abdomen and pelvis	Usually Not Appropriate	☢☢☢
US abdomen and pelvis	Usually Not Appropriate	O

This imaging modality was ordered by the physician

Findings (unlabeled)

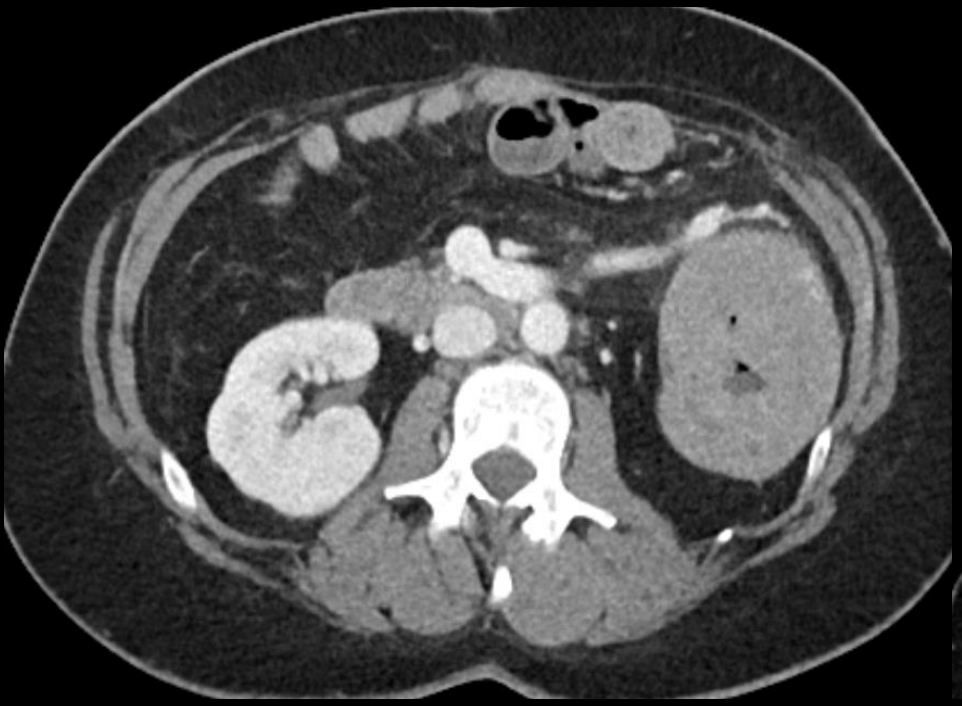

Findings: (labeled)

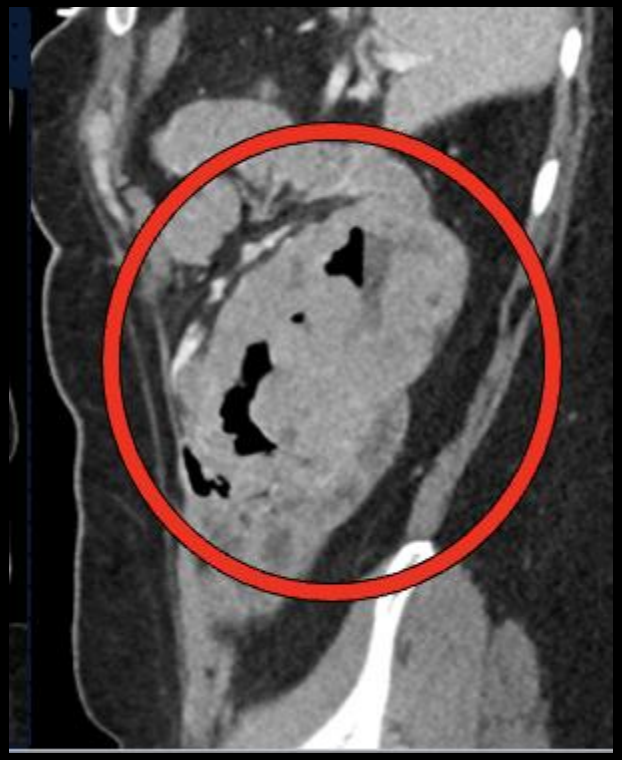

Initial Imaging Modality: Contrast-enhanced **CT abdomen and pelvis — axial, coronal, and sagittal views** demonstrate:

- Segmental length (12cm) of circumferential jejunal wall thickening (about 22 mm) and aneurysmal bowel dilation
- No bowel obstruction, no pneumatosis or pneumoperitoneum; no free fluid

Biopsy Findings

Patient underwent endoscopic small bowel biopsies with histopathology and confirmatory flow cytometry

Biopsy Findings:

- Monomorphic PTLD, **Diffuse Large B-Cell Lymphoma (DLBCL) type**.
- EBV-encoded RNA **(EBER)** positive by in-situ hybridization.

Immunophenotype: CD20+, CD79a+, Ki-67 >80%.

- **Staging:** Ann Arbor Stage IIE (nodal + contiguous extranodal disease).

Final Dx:

Post-transplant lymphoproliferative disorder (PTLD) – Diffuse large B-cell lymphoma subtype.

AMSER

Case Discussion – PTLD Overview

Summary of the Condition (1,2)

- Spectrum of lymphoid proliferations after solid organ/hematopoietic stem cell transplant due to impaired immune surveillance
- WHO categories: nondestructive, polymorphic, monomorphic (e.g., DLBCL), cHL-type.
- EBV-positive disease is common early; EBV-negative PTLD occurs later and biologically resembles de-novo lymphoma.

Common Clinical Features

- Systemic: fevers, night sweats, weight loss; cytopenias.
- Extranodal predilection: GI tract (pain, bleeding, obstruction), CNS (neuro deficits), allograft involvement; nodal disease also seen.
- Physical: lymphadenopathy, organomegaly; may be asymptomatic and discovered on imaging.

Imaging findings

- Wall thickening or eccentric mass, may ulcerate, hypoenhance, FDG avid
    - Can present with intussusception
    - <u>Usually doesn't obstruct (same as lymphoma)</u>

AMSER

Case Discussion – PTLD Overview

Initial Differential Diagnoses (1,2)

- Infectious lymphadenitis (EBV/CMV/HHV-6, mycobacterial/fungal).
- Inflammatory bowel disease or ischemia when GI-predominant; post-op changes.
- De-novo lymphomas (DLBCL, MALT), leukemic/lymphoproliferative disorders, drug-related pseudolymphoma.

Epidemiology (3,4,5)

- Overall incidence ~1–5% after solid organ transplant (higher with intestinal, lung, heart; lower with kidney).
- Bimodal timing: early (≤1 yr; often EBV+), late (years–decades; more EBV–).
- Risk increases with intensity/duration of immunosuppression (calcineurin inhibitors), T-cell–depleting agents, EBV-seronegative recipient, pediatric age.

Case Discussion - Management

Reduction of immunosuppression – First-line step in PTLD management to restore host T-cell–mediated immune control; tacrolimus dose reduced while maintaining graft function. (8,9)

Lead-in therapy – Short course of prednisone + vincristine to reduce tumor bulk and mitigate risk of rapid tumor lysis before full-dose chemoimmunotherapy.

Definitive systemic therapy – R-CHOP × 6 cycles (rituximab, cyclophosphamide, doxorubicin, vincristine, prednisone); completed 12/26/2024. Standard for monomorphic PTLD of aggressive B-cell phenotype.

Complications – Neutropenic fever (managed with empiric IV antibiotics); port-related bloodstream infection → port removal Jan 2025.

Response assessment – End-of-treatment FDG-PET/CT: complete metabolic response confirmed by biopsy showing no viable tumor. (10,11)

Modality	Complete Response	Partial Response	Stable Disease	Progressive Disease
CT	Lymph nodes ≤ 1,5 cm in Ldi Complete disappearance of radiologic evidence of disease	Single lesion: ↓ ≥ 50% in PPD Multiple lesions: ↓ ≥ 50% in SPD of up to six lymph nodes or extranodal sites	↓ ≤ 50% in SPD of up to six lymph nodes or extranodal sites (no criteria for progressive disease are met)	1) New lymphadenopathy or ↑; single node must be abnormal with: a) Ldi > 1.5 cm and b) PPD ≥ 50% and c) Ldi or Sdi ↑ 0.5 cm if ≤ 2.0 cm and ↑ 1.0 cm if > 2.0 cm 2) ↑ splenic volume: a) with prior splenomegaly: ↑ > 50% of its prior ↑ beyond baseline b) without prior splenomegaly: ↑ > 2.0 cm c) New or recurrent splenomegaly 3) New or larger nonmeasured lesions 4) Recurrent previously resolved lesions 5) New extranodal lesion > 1.0 cm in any axis (new lesions < 1.0 cm in any axis are included if attributable to lymphoma) 6) A new node > 1.5 cm in any axis
FDG PET-CT	Scores 1, 2 ,3 in nodal or extranodal sites with or without a residual mass	Scores 4 or 5 with ↓ uptake compared with baseline and residual mass(es)	Scores 4 or 5 with no obvious change in FDG uptake	Scores 4 or 5 in any lesion with ↑ uptake from baseline and/or New FDG-avid foci

Ldi = longest transverse diameter; **Sdi** = shortest transverse diameter; **PPD** = product of perpendicular diameters; **SPD** = sum of the product of the perpendicular diameters of multiple lesions; ↑ = increase; ↓ = decrease

Cheson BD, Fisher RI, Barrington SF, et al. Recommendations for initial evaluation, staging, and response assessment of Hodgkin and non-Hodgkin lymphoma: The Lugano classification. J Clin Oncol. 2014;32(27):3059-3068. doi:10.1200/JCO.2013.54.8800

Small Bowel Imaging: A Pattern Approach

Wall thickening (≥3 mm with adequate distention) is a useful clue for narrowing the differential diagnosis for small bowel disease

- **Target** (mucosal & serosal hyperenhancement, submucosal edema) = BENIGN
  - Inflammation
  - Infection

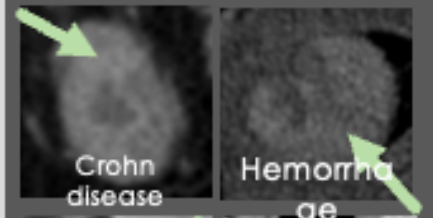

- **Homogenous** ("white")
  - Hemorrhage
  - Acute inflammatory bowel disease
  - Shock bowel

- **Hypoenhancement** ("gray")
  - Ischemia
  - Tumor

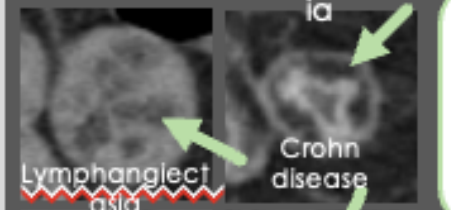

- **Fat**
  - Inflammatory bowel disease
  - Metabolic syndrome
  - Lymphangiectasia, celiac sprue, chemotherapy

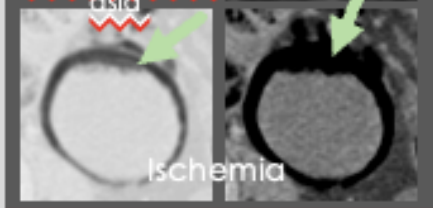

- **Gas** (pneumatosis intestinalis)
  - Ischemia
  - Benign pneumatosis

- **Length of Involvement**
  - Focal (<5 cm): neoplasm, endometriosis, diverticulitis
  - Segmental (5-30 cm): ischemia, infection, hemorrhage, radiation, Crohn disease, lymphoma, angioedema
  - Diffuse (>30 cm): infection, edema, vasculitis, graft versus host disease (GVHD)

- **Degree of Thickening**
  - Mild (3-4 mm): low protein state, infection, arterial ischemia
  - Moderate (5-9 mm): venous ischemia, Crohn disease, hemorrhage, angioedema, vasculitis
  - Marked (≥10 mm): neoplasm, Crohn disease, vasculitis, hemorrhage

- **Symmetry of Thickening**
  - Asymmetric: Crohn disease, tuberculosis (TB)
  - Symmetric: lymphoma

- **Segment of Involvement**
  - Adenocarcinoma: duodenum, jejunum
  - Lymphoma: ileum
  - Carcinoid: ileum

Lymphoma: segmental

Crohn disease: marked

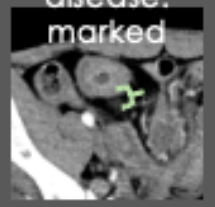

Crohn disease: asymmetric

Carcinoid: ileal

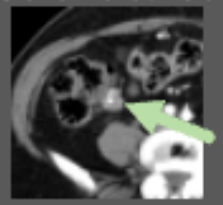

References:

1. **Dierickx D, Habermann TM.** Post-Transplantation Lymphoproliferative Disorders in Adults. *N Engl J Med.* 2018;378(6):549-562. doi:10.1056/NEJMra1702693.
2. **Evens AM, Roy R, Sterrenberg D, Moll MZ, Chadburn A, Gordon LI.** Post-transplantation lymphoproliferative disorders: diagnosis, prognosis, and current approaches to therapy. *Curr Oncol Rep.* 2010;12(6):383-394. doi:10.1007/s11912-010-0132-1.
3. Chang KJ, Marin D, Kim DH, *et al.* ACR Appropriateness Criteria® Suspected Small-Bowel Obstruction. *Journal of the American College of Radiology.* 2020;17(5S):S305-S314. doi:10.1016/j.jacr.2020.01.025.
4. **WHO Classification of Tumours. Haematolymphoid Tumours.** 5th ed. Lyon: IARC; 2024.
5. **Caillard S, Lamy FX, Quelen C,** *et al.* Epidemiology of posttransplant lymphoproliferative disorders in adult kidney and kidney-pancreas recipients: report of the French registry and analysis of subgroups of lymphomas. *Am J Transplant.* 2012;12(3):682-693. doi:10.1111/j.1600-6143.2011.03896.x.
6. **Opelz G, Döhler B.** Lymphomas after solid organ transplantation: a collaborative transplant study report. *Am J Transplant.* 2004;4(2):222-230. doi:10.1046/j.1600-6143.2003.00325.x.
7. **Swerdlow SH, Campo E,** *et al.* WHO Classification of Tumours of Haematopoietic and Lymphoid Tissues. Revised 4th ed. Lyon: IARC; 2017.
8. **Trappe RU,** *et al.* Response to Rituximab Induction Is a Predictive Marker in B-Cell PTLD and Allows Successful Stratification Into Rituximab or R-CHOP Consolidation: International Prospective Phase II Trial. *J Clin Oncol.* 2017;35(5):536-543. doi:10.1200/JCO.2016.69.3564.
9. **Choquet S, Leblond V, Herbrecht R,** *et al.* Efficacy and safety of rituximab in B-cell post-transplantation lymphoproliferative disorders: results of a prospective multicenter phase 2 study. *Blood.* 2006;107(8):3053-3057. doi:10.1182/blood-2005-01-0377.
10. **Cheson BD,** *et al.* Recommendations for initial evaluation, staging, and response assessment of Hodgkin and non-Hodgkin lymphoma: **the Lugano classification**. *J Clin Oncol.* 2014;32(27):3059-3068. doi:10.1200/JCO.2013.54.8800.
11. **Shetty AS, Bhattacharya A, Konstantinoff K,** *et al.* Fundamentals of Small Bowel Imaging: What Radiology Residents Should Know. *RadioGraphics.* 2023;43(2):e220094. doi:10.1148/rg.220094.
12. **Camacho JC, Moreno CC, Harri PA, Aguirre DA, Torres WE, Mittal PK.** Posttransplantation lymphoproliferative disease: proposed imaging classification. *RadioGraphics.* 2014;34(7):2025-2038. doi:10.1148/rg.347130130.

AMSER