

AMSER Case of the Month

November 2025

19 year old female with LUQ pain



Alexa Peters OMS-IV, LECOM
Dr. Matthew Hartman MD, Radiology
Dr. Akash Patel DO, R1
Allegheny Health Network



Patient Presentation

- 19 year old female presents to the ED for left upper quadrant abdominal pain. Denies any other associated symptoms.
- Patient has no pertinent past medical history, past surgical history, or medications
- Vital signs are WNL
- CBC, CMP, lipase, and D-dimer are WNL
- Urine pregnancy test is negative
- UA is positive for leukocyte esterase and rare bacteria

What Imaging Should We Order?

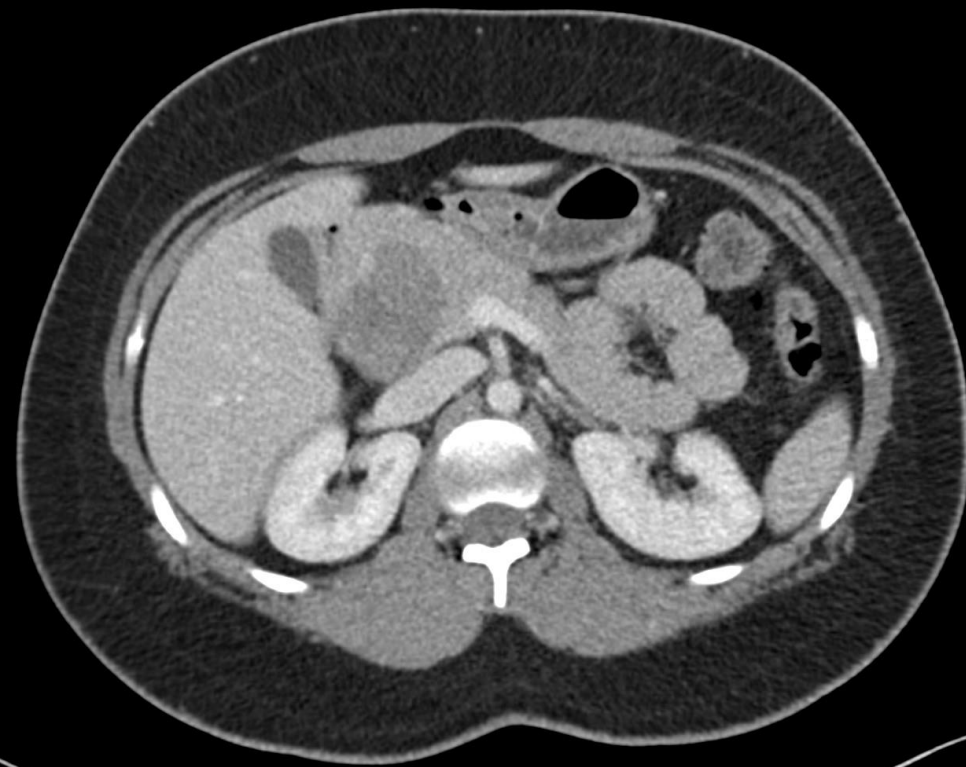
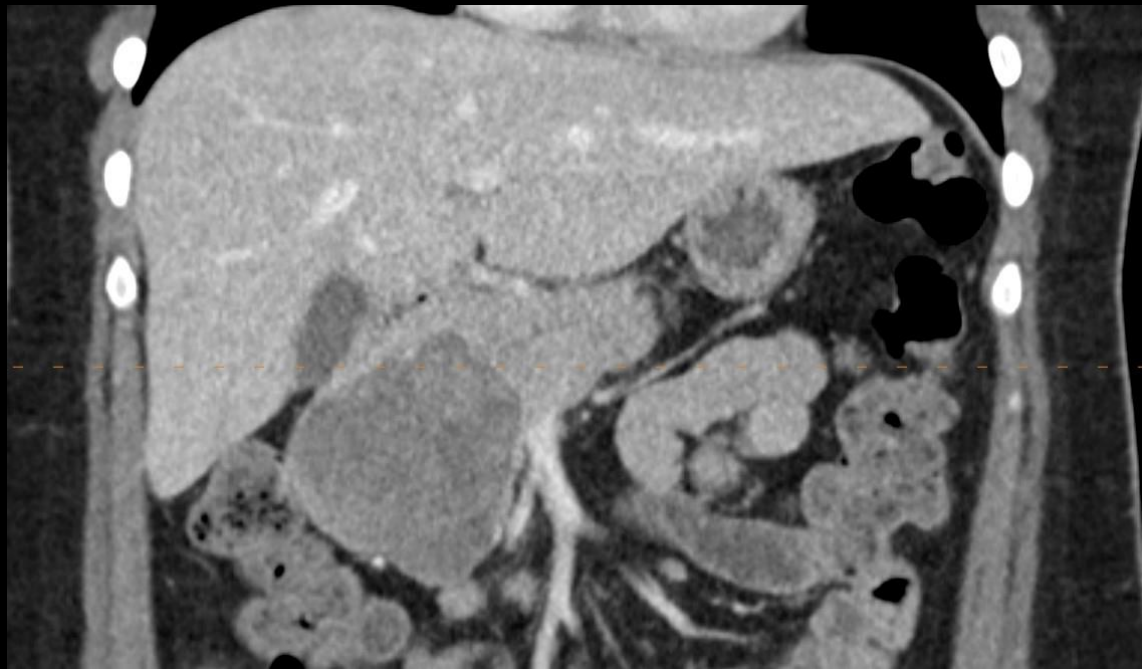
Select the applicable ACR Appropriateness Criteria

Procedure	Appropriateness Category	Relative Radiation Level
CT abdomen and pelvis with IV contrast	Usually Appropriate	⊗⊗⊗
CT abdomen and pelvis without IV contrast	May Be Appropriate	⊗⊗⊗
MRI abdomen and pelvis without and with IV contrast	May Be Appropriate	0
Radiography abdomen and pelvis	May Be Appropriate (Disagreement)	⊗⊗⊗
Fluoroscopy small bowel follow-through	May Be Appropriate	⊗⊗⊗
MRI abdomen and pelvis without IV contrast	May Be Appropriate	0
CT abdomen and pelvis without and with IV contrast	Usually Not Appropriate	⊗⊗⊗⊗
CT enteroclysis	Usually Not Appropriate	⊗⊗⊗⊗
CT enterography	Usually Not Appropriate	⊗⊗⊗⊗
MR enterography	Usually Not Appropriate	0
US abdomen and pelvis	Usually Not Appropriate	0
Fluoroscopy small bowel enteroclysis	Usually Not Appropriate	⊗⊗⊗
MR enteroclysis	Usually Not Appropriate	0

This imaging modality was ordered by the ER physician

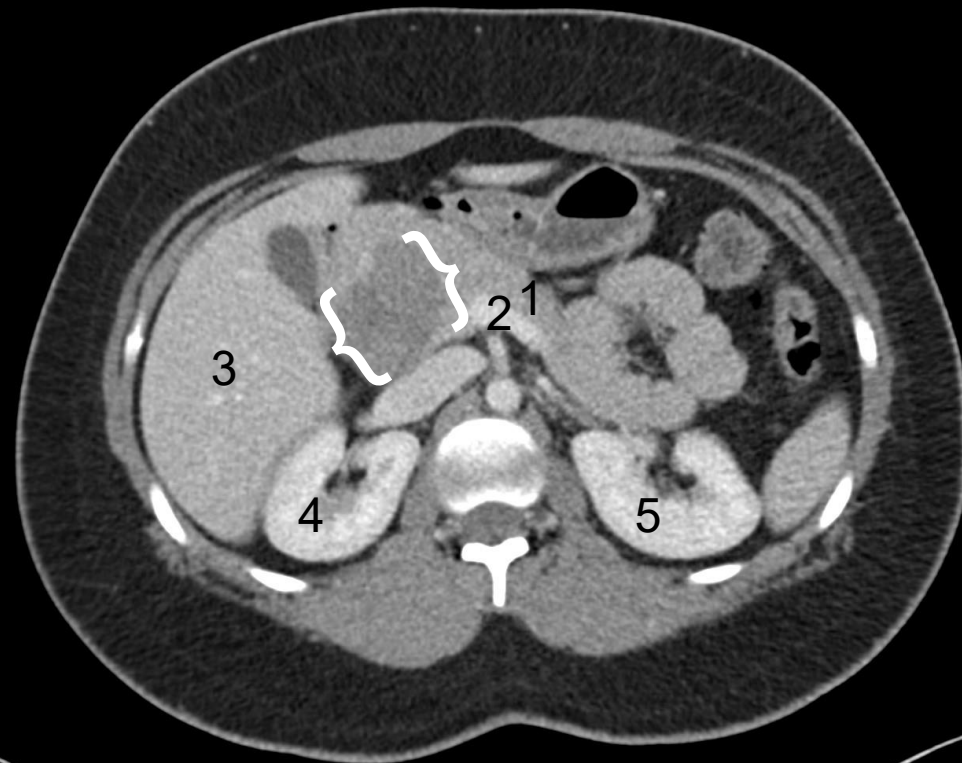
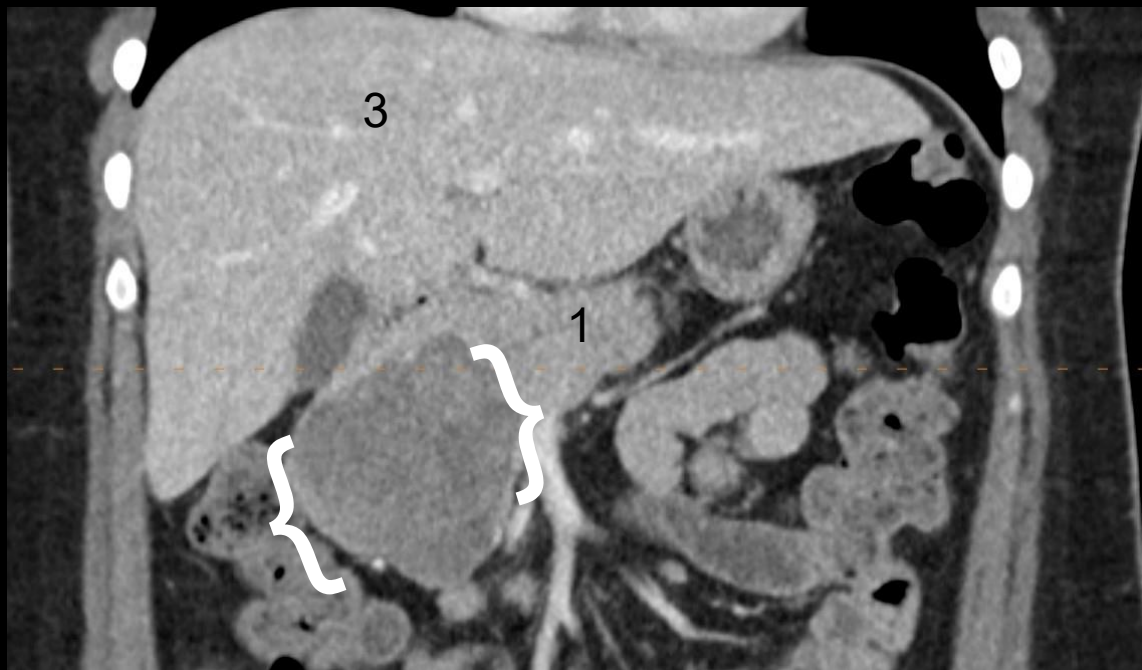


Findings (unlabeled)



Findings: (labeled)

- 1. Body of Pancreas
- 2. Splenic Vein
- 3. Liver
- 4. Right Kidney
- 5. Left Kidney
- { } Large mass in area of pancreatic head



Case Discussion

- Patient was found to have a solid mass in the pancreatic head with no ductal dilation.
- Cytology of the cyst was found to have a CEA of >0.2 ng/mL (N: > 5 ng/mL) and amylase of 910 U/L (N: <250 U/L).
- Differential diagnoses: Solid pseudopapillary neoplasm, pancreatic neuroendocrine tumor, pancreatic adenocarcinoma,

Final Dx:

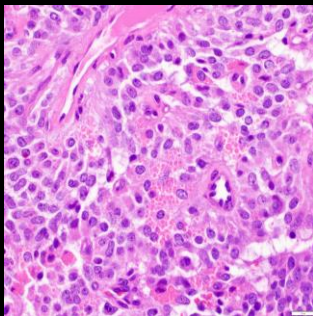
Solid Pseudopapillary Neoplasm

Case Discussion

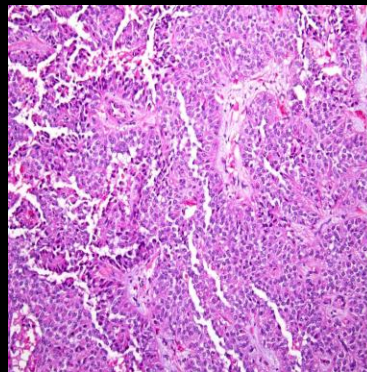
- Solitary pseudopapillary neoplasms are rare and occur primarily in young females.⁵
- It has low malignant potential.⁵
- Patients are commonly asymptomatic or minimally symptomatic.⁵
- The mass contains solid and cystic components³ and usually does not have associated ductal dilation, unlike adenocarcinoma
- The cyst fluid will have low CEA and amylase.³
- The exact etiology is unknown but it is thought to arise from pluripotent cells of the genital ridges adhering to the pancreas during fetal development.⁴
- The majority of SPN's include the mutation CTNNB1, which leads to nuclear accumulation of β -catenin. They also have been known to demonstrate absence of pancreatic markers and inclusion of sex hormone receptors.⁴

Case Discussion

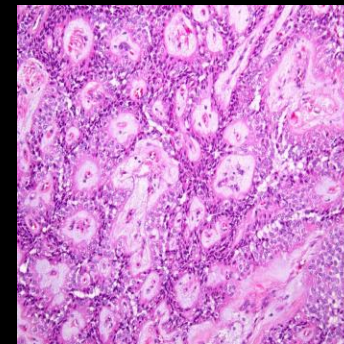
- Pathologic features:
 - The mass will have a mix of solid and pseudopapillary areas. This is caused by the tumor cells detaching from blood vessels and forming fibrovascular stalks.³
 - The tumor cells will also have intracytoplasmic hyaline globules and perinuclear vacuoles with eosinophilic cytoplasm.³



Intracytoplasmic
eosinophilic hyaline
globules³



Solid pseudopapillary neoplasm³



Case Discussion

- Radiologic features:
 - Typically seen in the body or tail of the pancreas.⁴
 - On CT, they have a central cystic component with peripheral solid components, as well as thick encapsulation which may be partially calcified. It will also enhance similarly to the pancreas with contrast, which differentiates it from other pancreatic masses.⁴
 - MRI is the preferred imaging modality and will show a heterogenous mass with a thin hypointense capsule.⁴

Case Discussion

- Patient was scheduled for a robotic Whipple for removal of the mass.
- Surgical resection is the preferred treatment of SPN's.¹
- If the mass is unresectable, ablation, gamma-knife treatments, embolization, chemotherapy, or radiotherapy can be options.⁴
- Since the mass can contain sex hormone receptors, tamoxifen can be used if the mass is unresectable, but evidence of its effects are limited and are further being studied.⁴

References:

1. Coelho, J. C. U., da Costa, M. A. R., Ramos, E. J. B., Torres, A. R., Savio, M. C., & Claus, C. M. P. (2018). *Surgical management of solid pseudopapillary tumor of the pancreas*. JSLS : Journal of the Society of Laparoendoscopic Surgeons. <https://pmc.ncbi.nlm.nih.gov/articles/PMC6365096/>
2. John. (2025, April 17). *ACR appropriateness criteria® suspected small-bowel obstruction*. Surgical Focus. <https://emorysurgicalfocus.com/2025/04/17/acr-appropriateness-criteria-suspected-small-bowel-obstruction/>
3. Navale, P., Savari, O., Tomashefski, J. F., & Vyas, M. (2022, March 4). *Solid pseudopapillary neoplasm*. Pathology Outlines - Solid pseudopapillary neoplasm. <https://www.pathologyoutlines.com/topic/pancreassolidpseudo.html>
4. Paluri, R. K. (2024, January 10). *Solid pseudopapillary epithelial neoplasm (spen) of the pancreas*. StatPearls [Internet]. <https://www.ncbi.nlm.nih.gov/books/NBK544335/>
5. Shuja, A., & Alkimawi, K. A. (2014, May). *Solid pseudopapillary tumor: A rare neoplasm of the pancreas*. Gastroenterology report. <https://pmc.ncbi.nlm.nih.gov/articles/PMC4020125/>