

AMSER Case of the Month

November 2025

30 y/o female with history of bilateral ovarian cysts
presents with pelvic pain

John Wang, MS4

Emory University School of Medicine

Sean Doyle, MD, PhD (R2)

Emory University School of Medicine, Department Of Radiology and Imaging Science

Kiran Maddu, MBBS

Emory University School of Medicine, Department Of Radiology and Imaging Science

Patient Presentation

- **HPI:** 30 y/o female presents with 3 days of acute onset, progressively worsening pelvic pain with nausea and vomiting. Her pain was not relieved by over-the-counter pain medications. Prior pelvic ultrasound was notable for a left adnexal mass and a complex, enlarging right adnexal mass.
- **PMHx:** Bilateral ovarian cysts seen on US 3 months prior. Right: 5.6 x 4 x 3.9 cm. Left: 5 x 3 x 4.3 cm.
- **PSHx:** Finger surgery
- **Meds:** Spironolactone 50 mg BID
- **Allergy:** Guaifenesin, dairy
- **Gyn:** GOP0
- **FHx:** Factor V Leiden mutation (?homo/heterozygous) (mother), PE (mother), DVTs (mother and sister)
- **Social Hx:** Currently drinks alcohol; no tobacco or drug use
- **Vitals:** Temp 37 C (98.6 F), BP 119/88, HR 83 bpm, RR 17, SpO2 99%
- **PE:** Right adnexal fullness to palpation. Mild tenderness to palpation in right lower quadrant/right adnexal region.

Pertinent Labs

- **CBC:** ↑WBC 12.5
- **CMP:** ↑Anion gap 13
- **β-hCG:** Negative
- **Lipase:** Normal

What Imaging Should We Order?

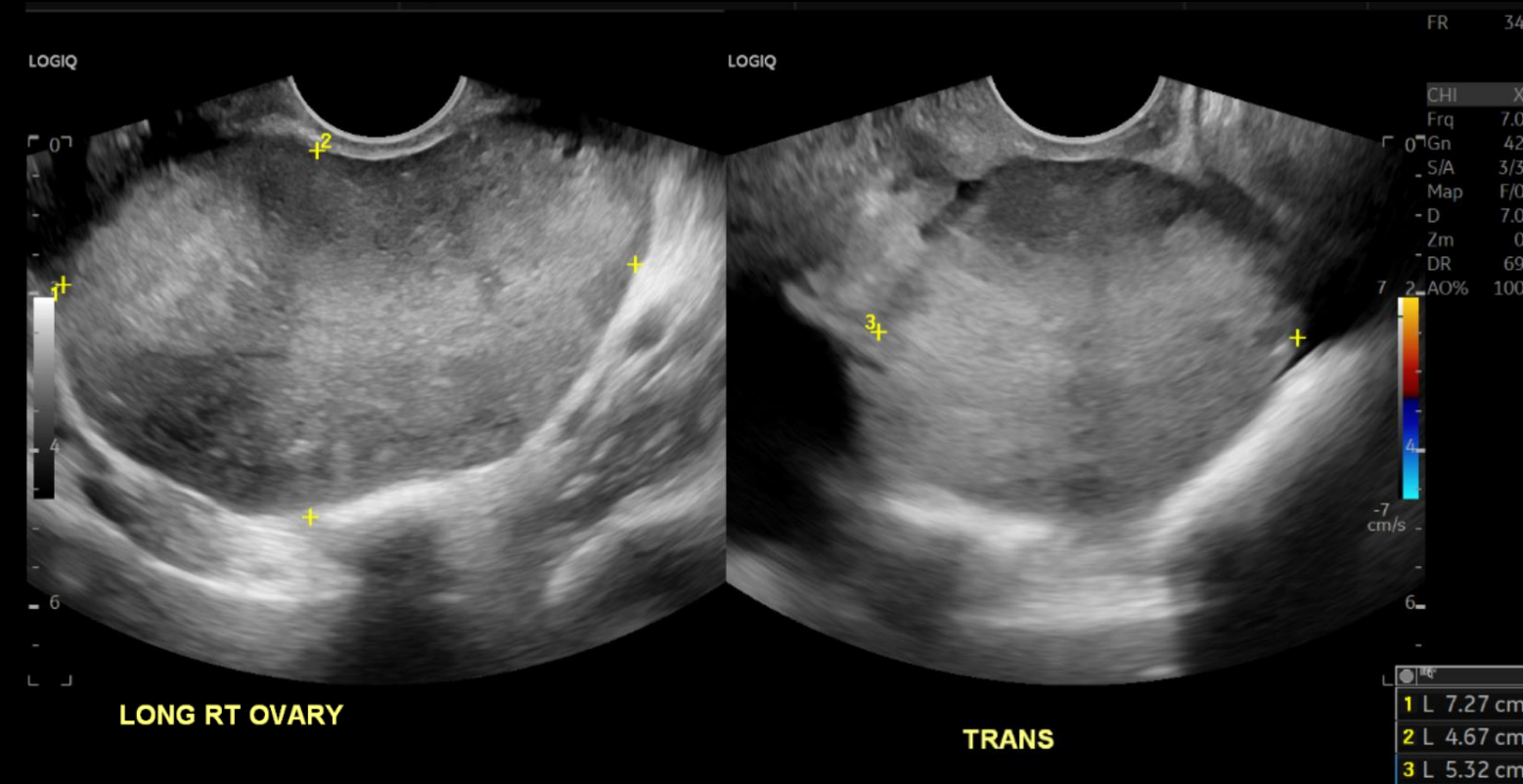
ACR Appropriateness Criteria

Variant 2: Acute pelvic pain in the reproductive age group. Gynecological etiology suspected, β -hCG negative (either serum or urine). Initial imaging.

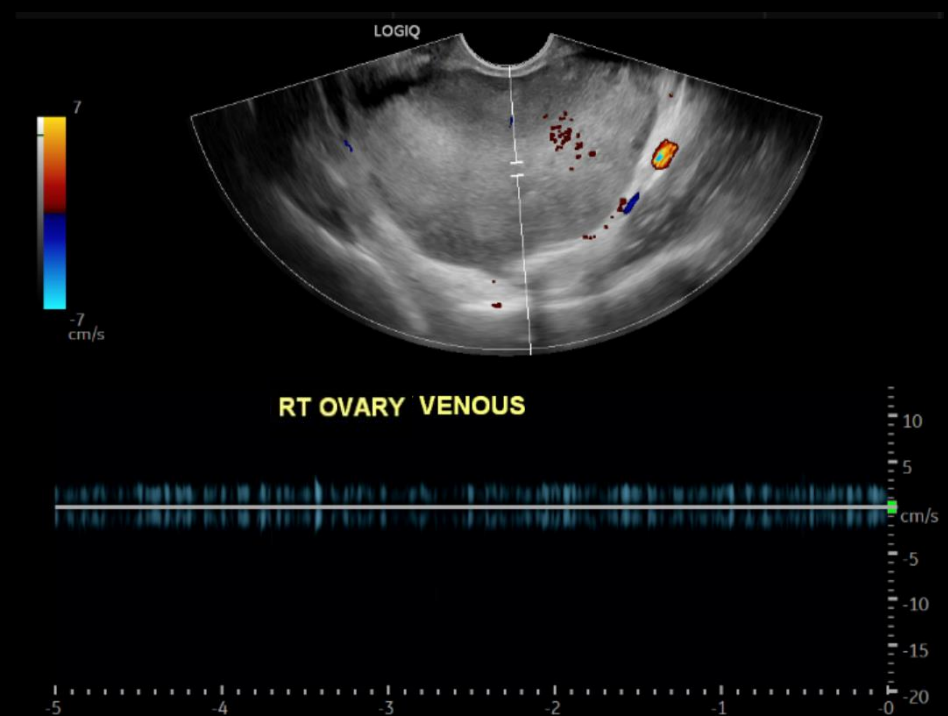
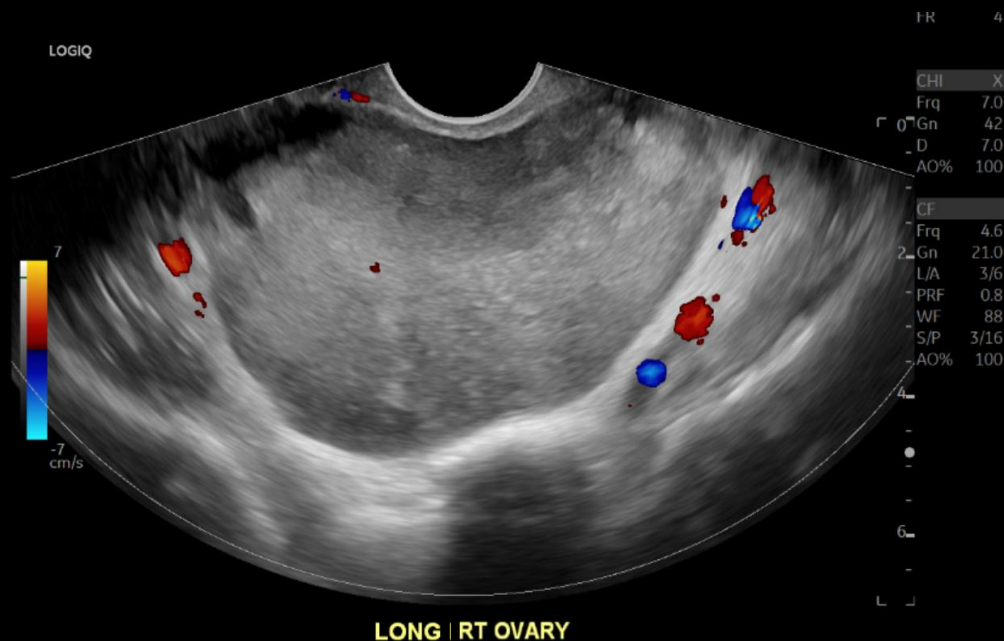
Procedure	Appropriateness Category	Relative Radiation Level
US duplex Doppler pelvis	Usually Appropriate	0
US pelvis transabdominal	Usually Appropriate	0
US pelvis transvaginal	Usually Appropriate	0
MRI pelvis without and with IV contrast	May Be Appropriate	0
MRI pelvis without IV contrast	May Be Appropriate	0
CT abdomen and pelvis with IV contrast	May Be Appropriate	⊕⊕⊕
MRI abdomen and pelvis without and with IV contrast	Usually Not Appropriate	0
MRI abdomen and pelvis without IV contrast	Usually Not Appropriate	0
CT abdomen and pelvis without IV contrast	Usually Not Appropriate	⊕⊕⊕
CT pelvis with IV contrast	Usually Not Appropriate	⊕⊕⊕
CT pelvis without IV contrast	Usually Not Appropriate	⊕⊕⊕
CT abdomen and pelvis without and with IV contrast	Usually Not Appropriate	⊕⊕⊕⊕
CT pelvis without and with IV contrast	Usually Not Appropriate	⊕⊕⊕⊕

These imaging modalities were ordered by the ER provider

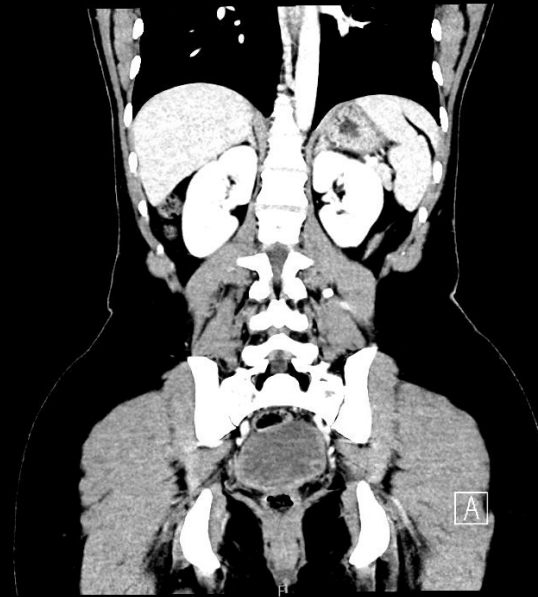
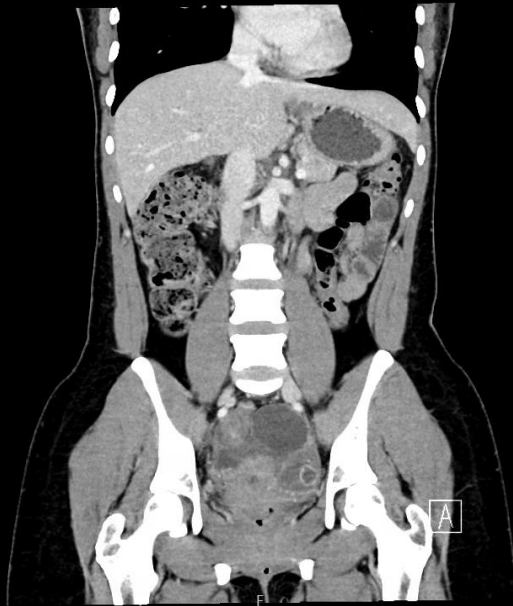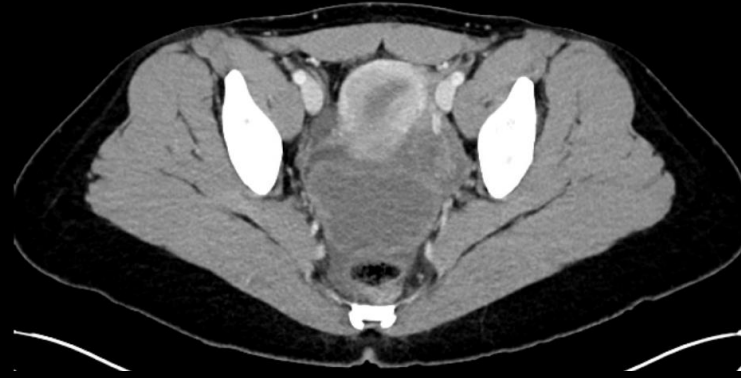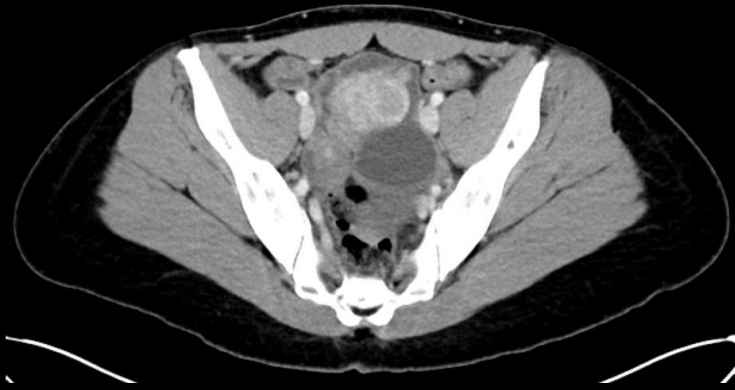Findings (unlabeled) - TVUS



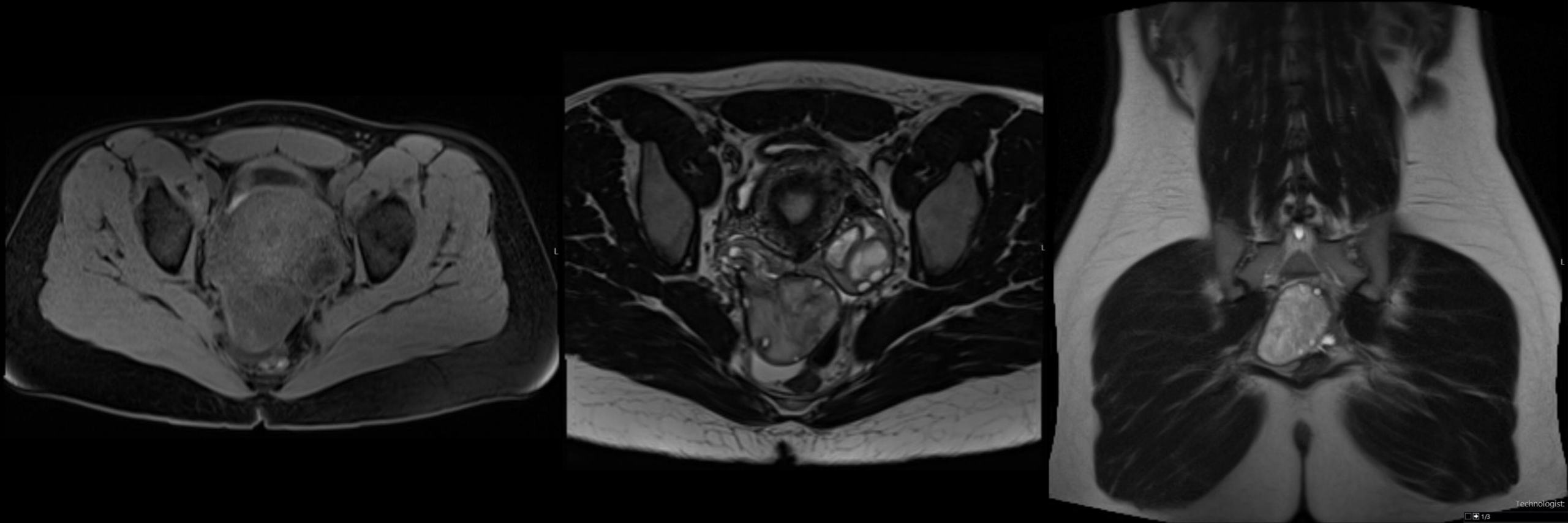
Findings (unlabeled) - TVUS w/ Doppler



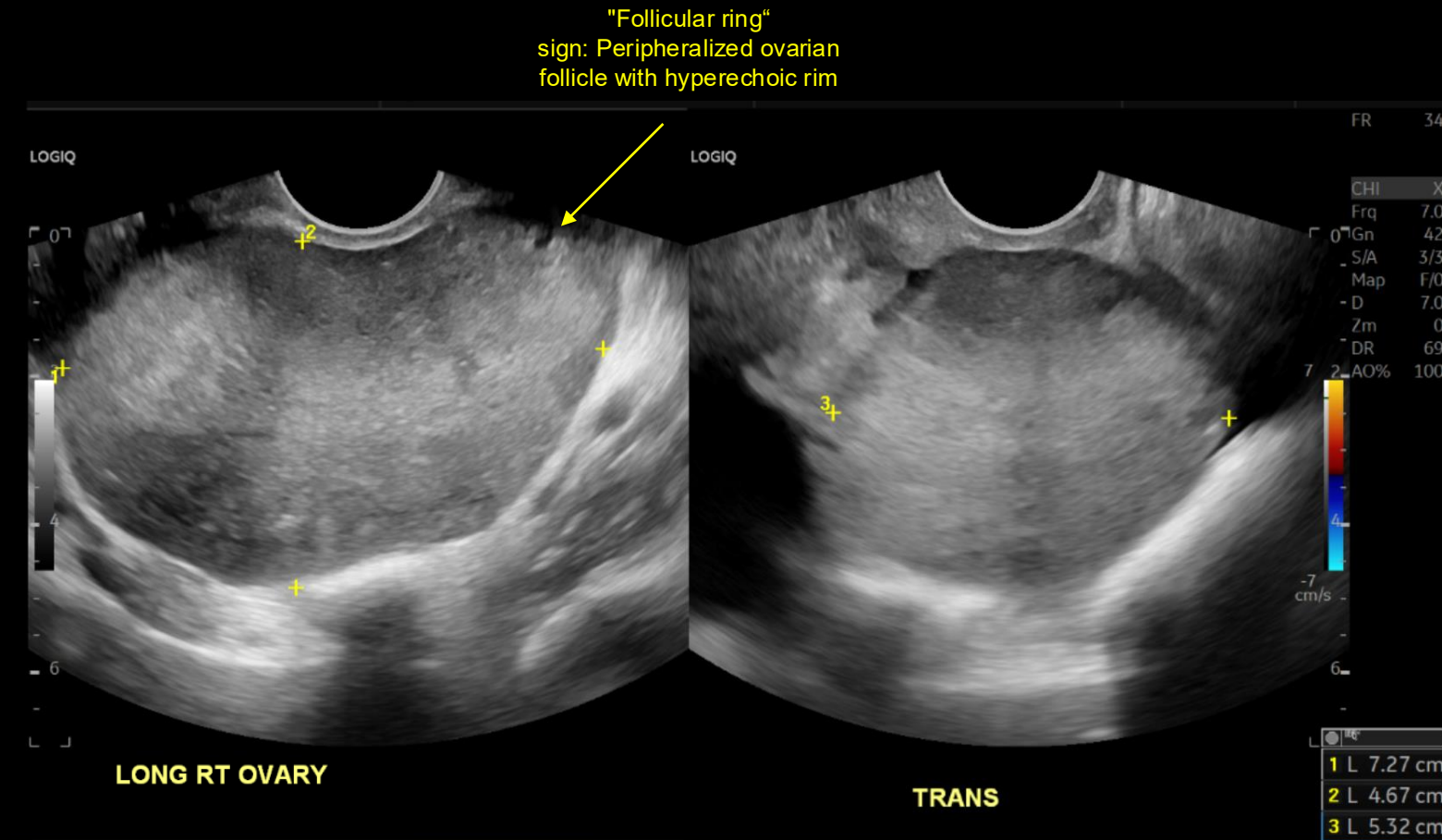
Findings (unlabeled) - CT



Findings (unlabeled) - MRI

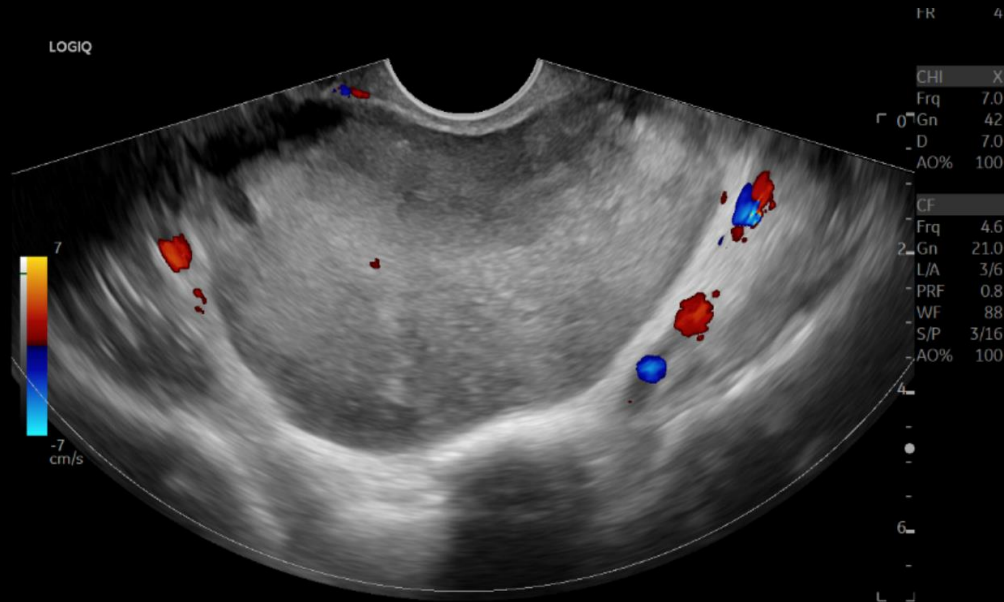


Findings (labeled) - TVUS



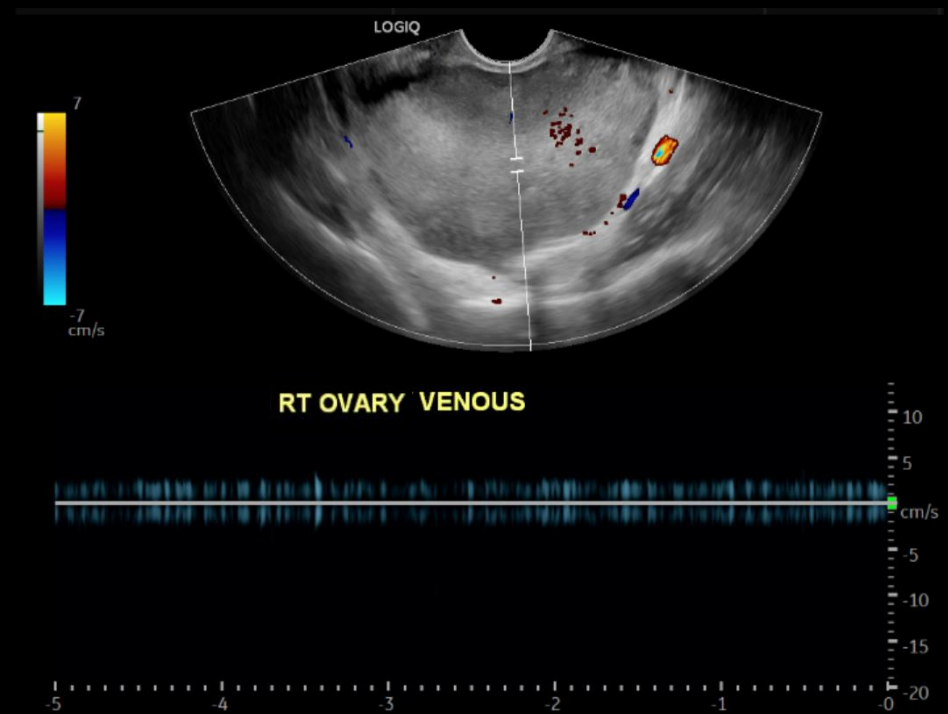
Enlarged, mixed echogenicity right ovary (indicated by calipers) measuring up to 7.3 cm; central regions of hyperechogenicity are favored to reflect hemorrhage

Findings (labeled) - TVUS w/ Doppler



LONG RT OVARY

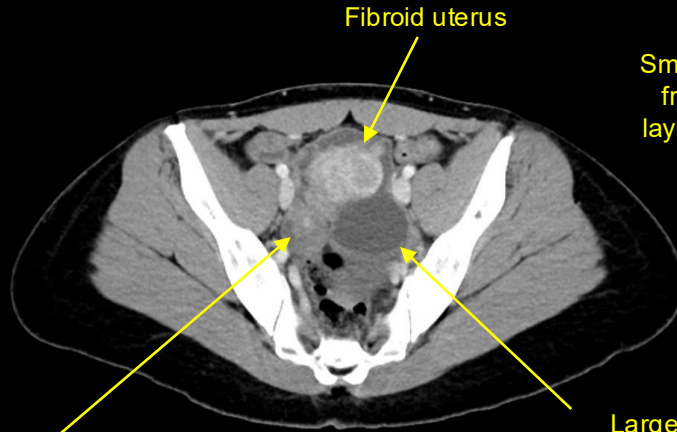
Enlarged right ovary demonstrates diffusely decreased vascular flow on color Doppler



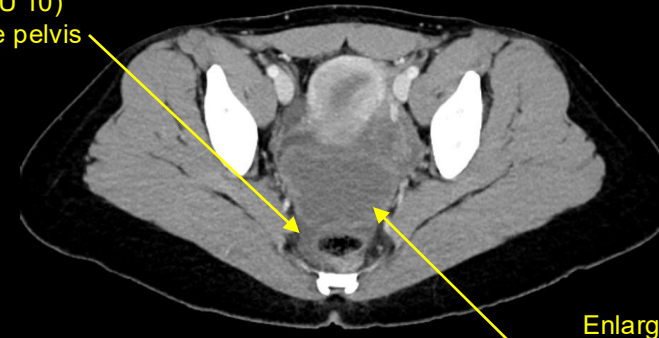
Decreased/abnormal right ovarian venous waveform; no definite right ovarian arterial waveform was detected (not shown)

Findings (labeled) - CT

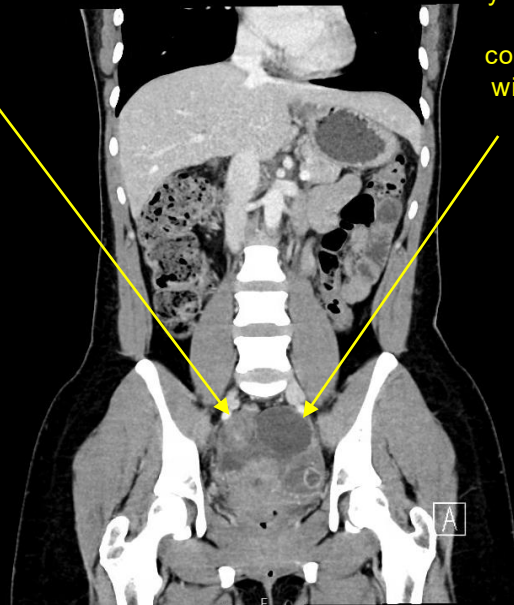
Axial



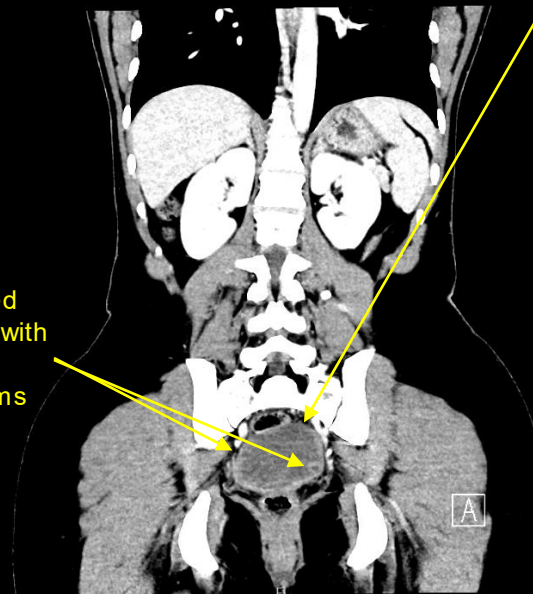
Axial



Coronal

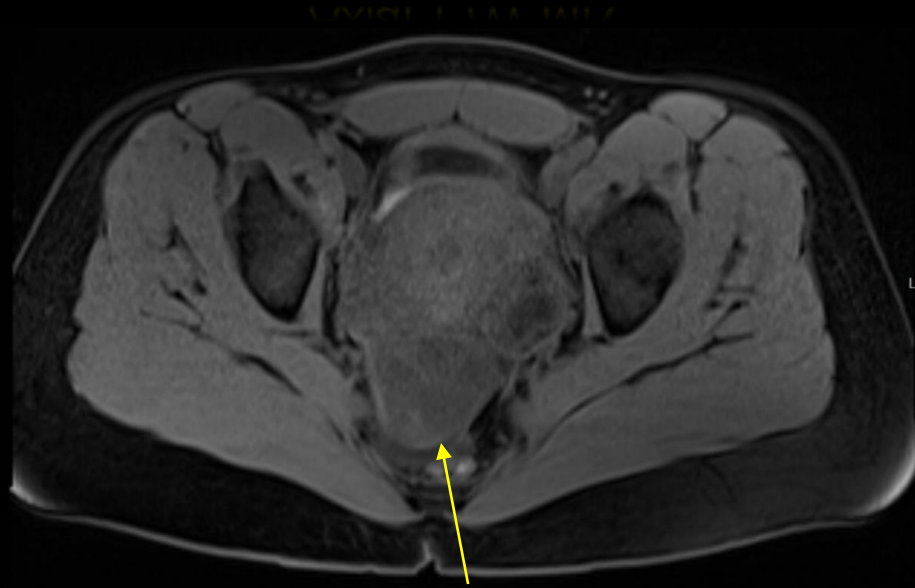


Coronal



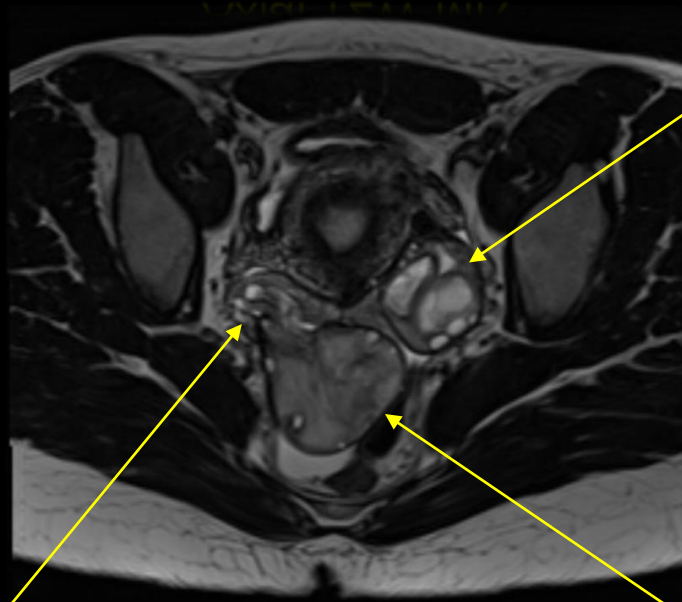
Findings (labeled) - MRI

Axial T1W MR



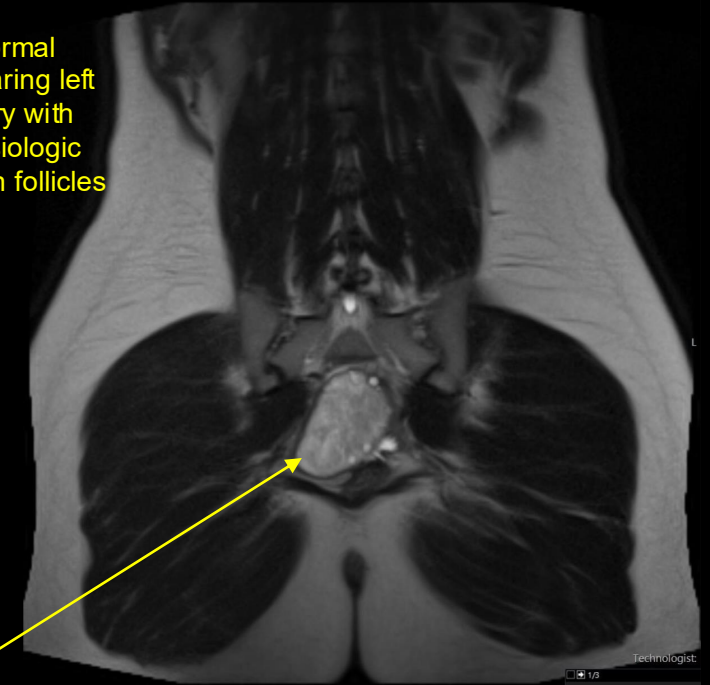
Posteriorly located, heterogeneously intense right ovary, with faint areas of hyperintensity suggesting hemorrhage

Axial T2W MR



"Whirlpool" sign:
Characteristic tortuous, whirled tubular structure in the right adnexa

Coronal T2W MR



Normal appearing left ovary with physiologic ovarian follicles

Enlarged, heterogeneously edematous, posteriorly located right ovary with peripheralized right ovarian follicles

Final Dx:

Adnexal Torsion (Right)

Case Discussion: Pathophysiology

- **Cause:** Twisting of ovary around its supporting (infundibulopelvic and utero-ovarian) ligaments
 - Initially causes venous congestion, eventually results in reduction in arterial flow
 - Commonly involves both the ovary and its fallopian tube (67% of cases)¹
 - Uncommonly, isolated ovarian torsion can occur
- **Risk factors:**
 - Large ovarian mass (> 5 cm)²
 - Commonly due to serous cysts and mature cystic teratomas³
 - Pregnancy
 - Ovarian induction (enlargement due to multiple follicular cysts)

Case Discussion: Imaging Findings

- **Ultrasound:** Imaging modality of choice for torsion
 - Enlarged ovary with hypoechoic heterogeneous center representing edema (79%) of cases⁴
 - Areas of increased echogenicity may indicate hemorrhagic infarction
 - Reduced venous \pm arterial flow on Doppler (though torsion can appear as normal vascularity – should not give false assurance)
 - Noncontinuous flow pattern – a type of venous flow abnormality can be present in 100% of cases⁵
 - "Whirlpool sign" (twisting of vessels with or without flow) or target sign
 - "Follicular ring" sign
 - Hyperechoic, thickened rings around antral follicles in ovary seen in early torsion⁶

Case Discussion: Imaging Findings

- **CT:** Not first-line for suspected torsion
 - Large pelvic mass (most common)¹
 - May also have a benign mass/cyst acting as a lead point
 - Twisted pedicle creating whirlpool
 - Surrounding fat stranding, free fluid, or hemoperitoneum
- **MRI:** not first-line for suspected torsion but can be used to clarify uncertain cases
 - Increased T1 signal intensity can indicate hemorrhage
 - Increased T2 signal intensity can indicate edema
 - Absence of enhancement is an indicator for ischemia, necrosis, nonviability
 - Twisted pedicle seen as heterogeneous structure with increased T2 signal intensity¹
- Our patient had MRI performed a few days prior to presentation for characterization of ovarian cysts, which later showed evidence of torsion

Case Discussion: Management

- **Treatment:** Urgent laparoscopic exploration to prevent ovary necrosis
 - Intraoperative assessment of ovarian viability after detorsion determines if excision is necessary
 - Successful detorsion associated with high likelihood of future normal follicular development⁷
 - Salpingo-oophorectomy is recommended for severe necrosis, postmenopausal women or suspected malignancy¹
- Our patient underwent laparoscopic right ovarian detorsion, but due to lack of color return after detorsion a right salpingo-oophorectomy was required.

References

1. Taufiq Dawood, M., Naik, M., Bharwani, N., Sudderuddin, S. A., Rockall, A. G., & Stewart, V. R. (2021). Adnexal torsion: Review of radiologic appearances. *Radiographics*, 41(2), 609–624. <https://doi.org/10.1148/rg.2021200118>
2. Houry, D., & Abbott, J. T. (2001). Ovarian torsion: A fifteen-year review. *Annals of Emergency Medicine*, 38(2), 156–159. <https://doi.org/10.1067/mem.2001.114303>
3. Varras, M., Tsikini, A., Polyzos, D., Samara, C.h, Hadjopoulos, G., & Akrivis, C.h (2004). Uterine adnexal torsion: pathologic and gray-scale ultrasonographic findings. *Clinical and experimental obstetrics & gynecology*, 31(1), 34–38.
4. Moro, F., Bolomini, G., Sibal, M., Vijayaraghavan, S. B., Venkatesh, P., Nardelli, F., Pasciuto, T., Mascilini, F., Pozzati, F., Leone, F. P. G., Josefsson, H., Epstein, E., Guerriero, S., Scambia, G., Valentin, L., & Testa, A. C. (2020). Imaging in gynecological disease (20): clinical and ultrasound characteristics of adnexal torsion. *Ultrasound in obstetrics & gynecology : the official journal of the International Society of Ultrasound in Obstetrics and Gynecology*, 56(6), 934–943. <https://doi.org/10.1002/uog.21981>
5. Nizar, K., Deutsch, M., Filmer, S., Weizman, B., Beloosesky, R., & Weiner, Z. (2009). Doppler studies of the ovarian venous blood flow in the diagnosis of adnexal torsion. *Journal of clinical ultrasound : JCU*, 37(8), 436–439. <https://doi.org/10.1002/jcu.20621>
6. Sibal M. (2012). Follicular ring sign: a simple sonographic sign for early diagnosis of ovarian torsion. *Journal of ultrasound in medicine : official journal of the American Institute of Ultrasound in Medicine*, 31(11), 1803–1809. <https://doi.org/10.7863/jum.2012.31.11.1803>
7. Oelsner, G., Cohen, S. B., Soriano, D., Admon, D., Mashiach, S., & Carp, H. (2003). Minimal surgery for the twisted ischaemic adnexa can preserve ovarian function. *Human reproduction (Oxford, England)*, 18(12), 2599–2602. <https://doi.org/10.1093/humrep/deg498>