

AMSER Case of the Month

April 2026

The Ring of Deception

Kolya Isterabadi, M2

Matthew Kruse, M.D.

Department of Radiology
Creighton University School of Medicine

Patient Presentation

- **HPI:** 65-year-old male drives himself to the emergency department after 12-15 ft. fall from ladder resulting in injury to right lower ribs.

- **PMH:**
 - Surgical hx – laparoscopic appendectomy, lung RU lobectomy
 - COPD, Essential HTN

- **Physical Exam:**
 - Appearance: frail and chronically ill, dry mucous membranes
 - Tender to palpation with mild deformity at anterior right lower ribs
 - Negative for: frank jaundice, RUQ abdominal pain

Pertinent Labs

- Ethanol – 73 mg/dL (≥ 10)
- Hypokalemia – 3.5 mmol/L (3.7 – 5.1)
- Hypocalcemia – 7.7 mg/dL (8.5 – 10.5)
- Mild Thrombocytopenia – 113 k/uL (140 – 440)
- CBC, Alk. Phos., Total Bilirubin, Serum Albumin – Normal
- Lipids – Stable compared to historical baseline

What Imaging Should We Order?

Major blunt chest trauma in adult: ACR Appropriateness Criteria

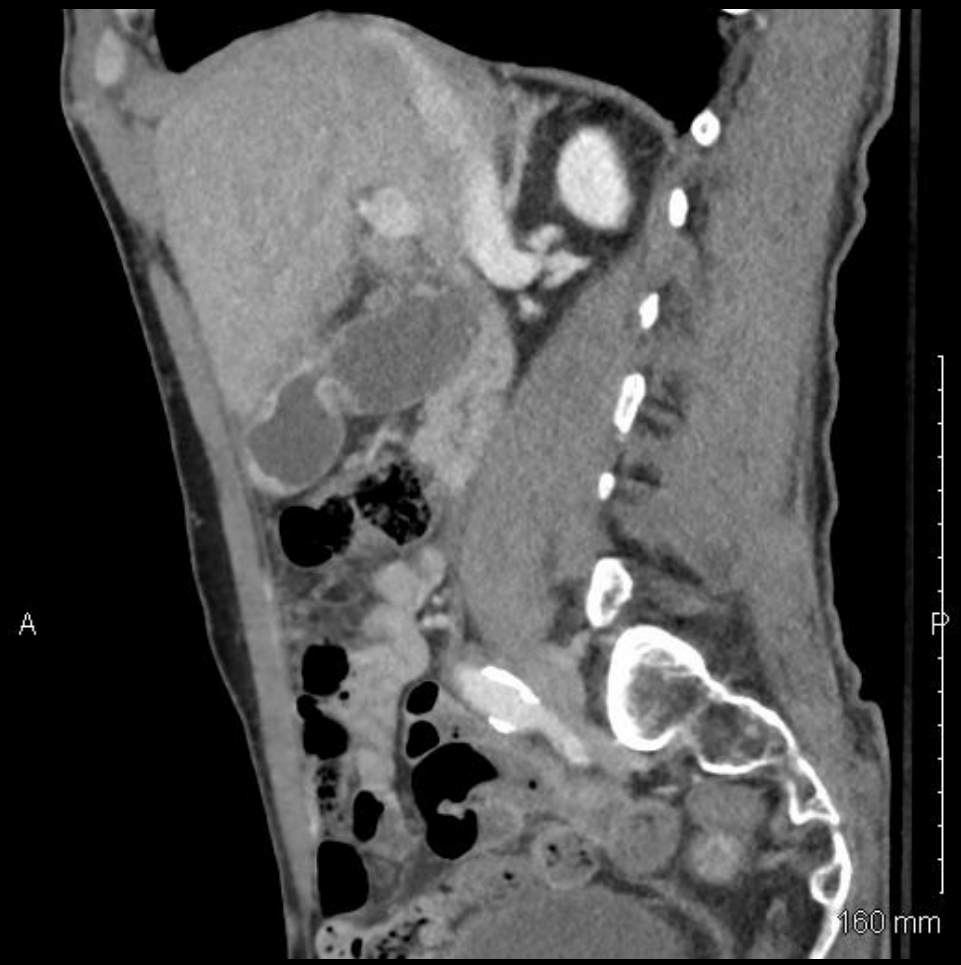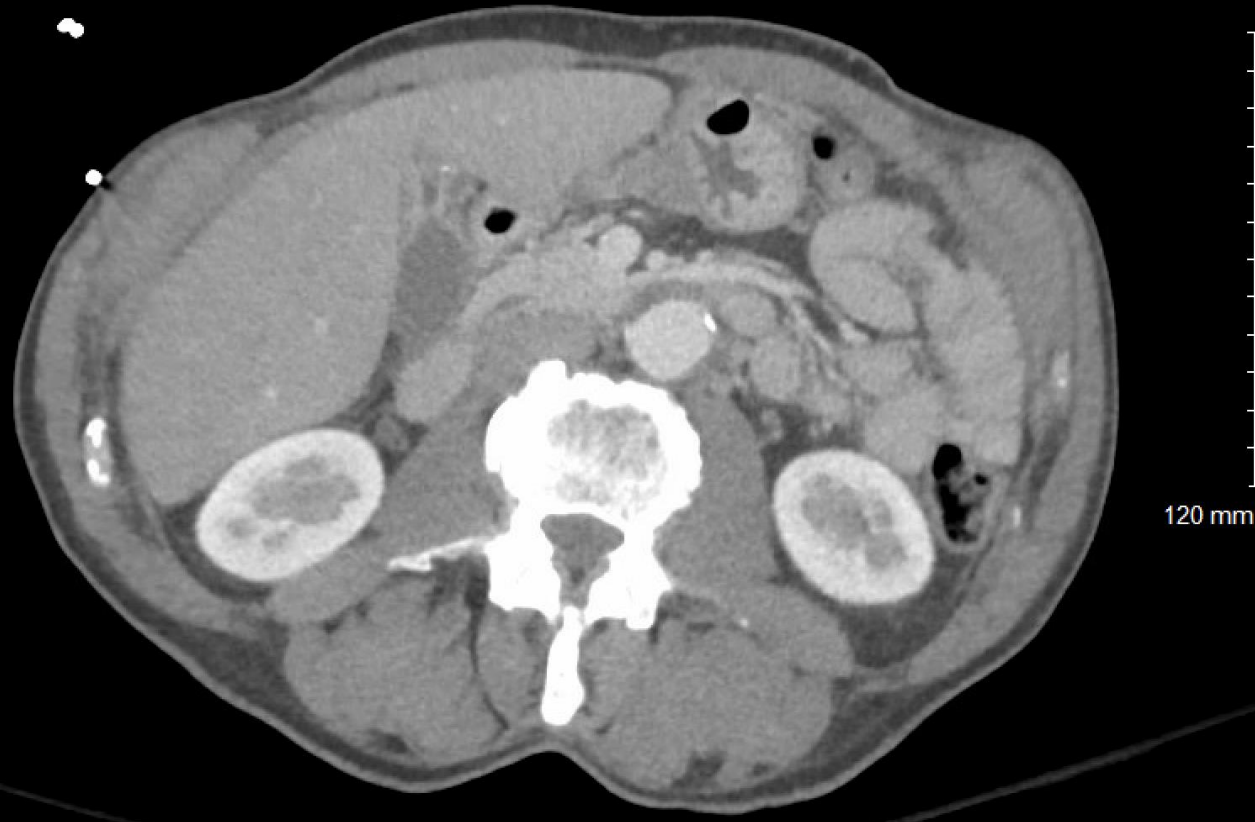Variant: 7 Adult. Major blunt trauma. Hemodynamically stable. Suspected chest trauma. Initial imaging.

Procedure	Appropriateness Category	Relative Radiation Level
Radiography trauma series	Usually Appropriate	☼☼☼
CT chest with IV contrast	Usually Appropriate	☼☼☼
CTA chest with IV contrast	Usually Appropriate	☼☼☼
CT whole body with IV contrast	Usually Appropriate	☼☼☼☼
CT whole body without IV contrast	May Be Appropriate	☼☼☼☼
US chest	Usually Not Appropriate	0

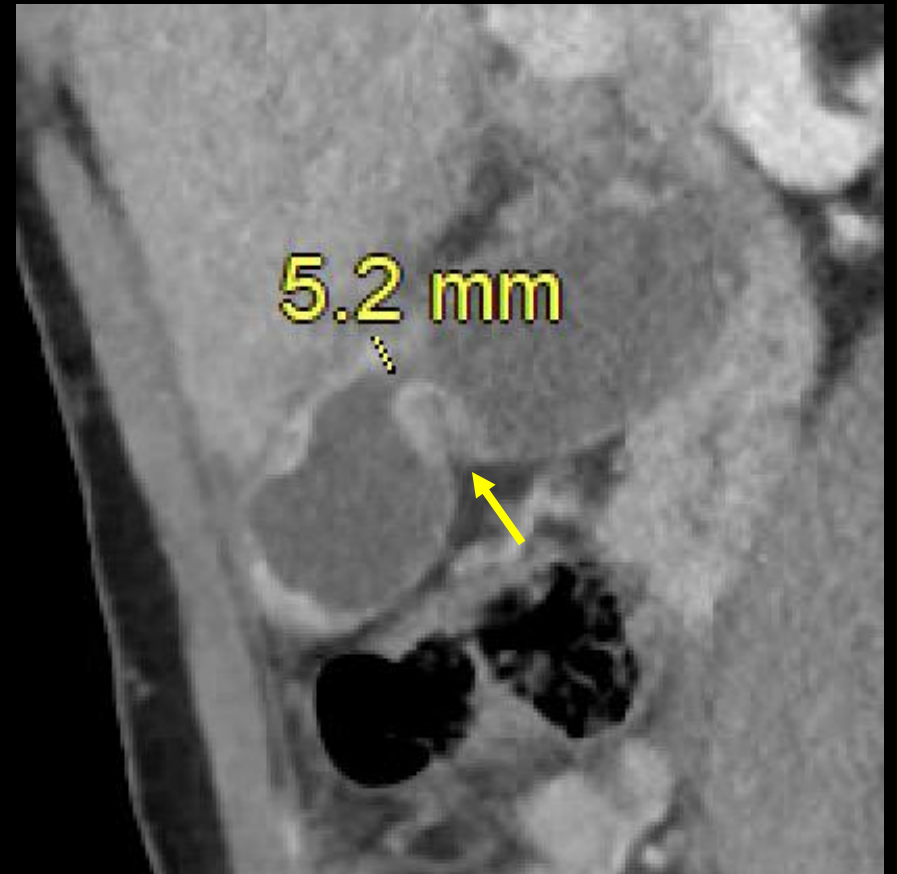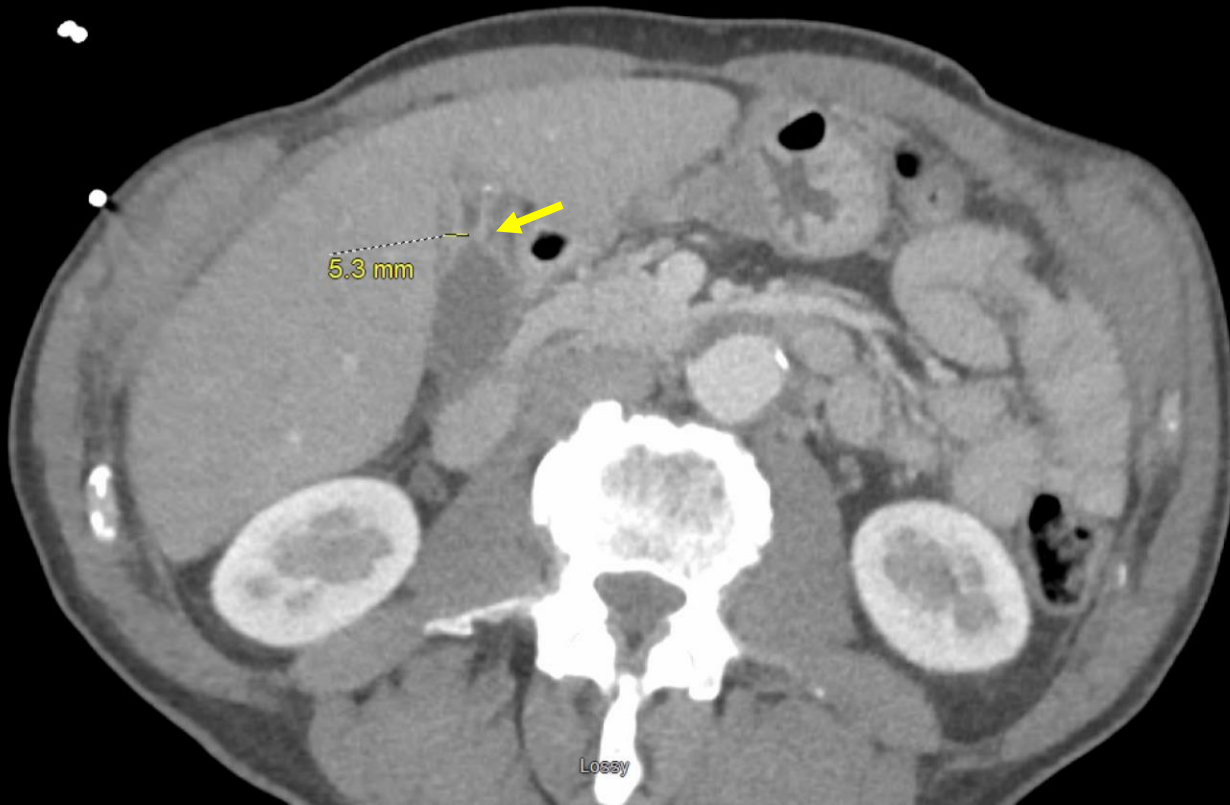
→ As expected, Chest CT showed right anterolateral rib fractures of ribs 5, 6, 7

→ CT Abdomen Pelvis was more complex...

CT Abdomen Pelvis w/ Contrast; Findings



CT Abdomen Pelvis w/ Contrast; Findings (Labeled)



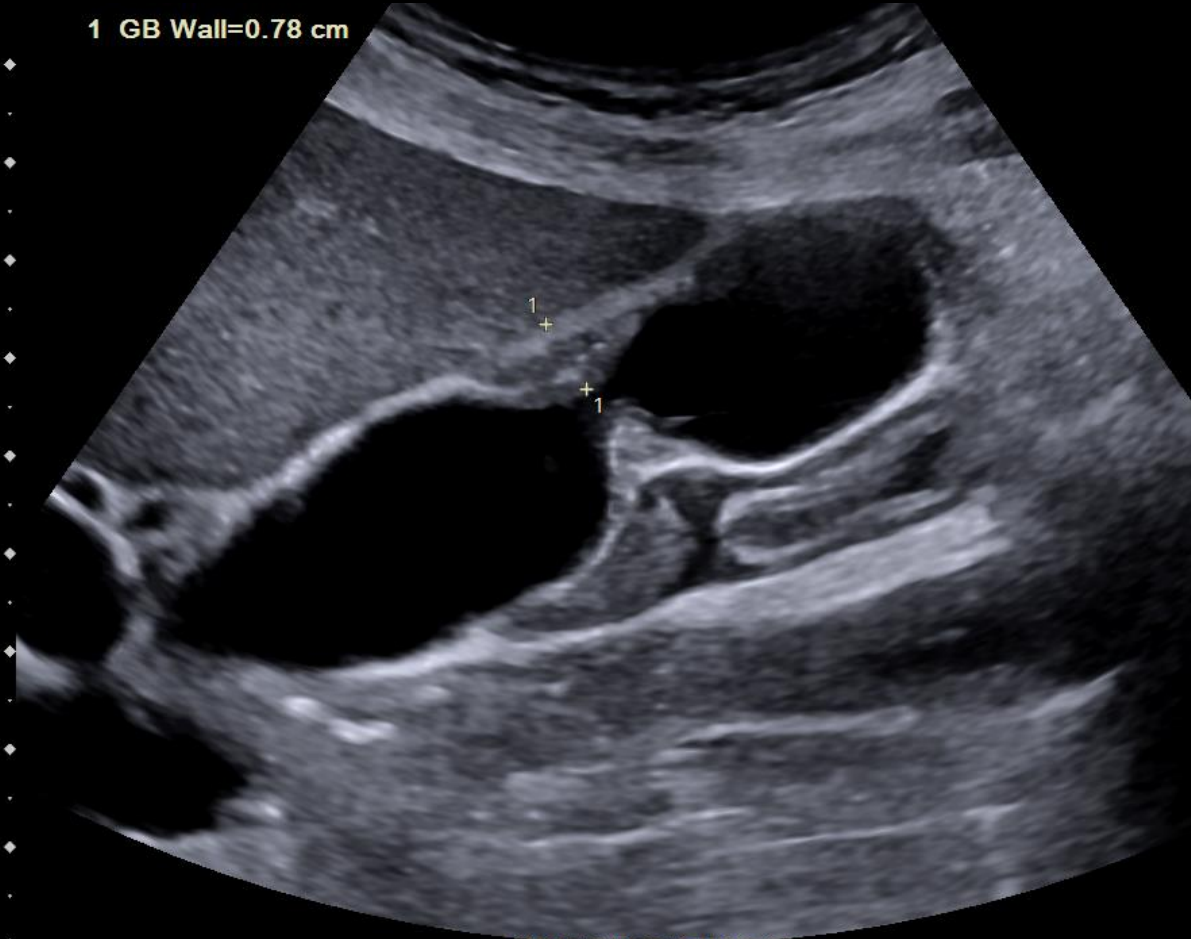
- Annular gallbladder wall thickening with enhancement
- Mid-gallbladder stricture (→)

What next?

- Given the concern for potential gallbladder adenocarcinoma, follow up imaging was obtained:
 - 1) Ultrasound (non-contrast)
 - 2) MRCP

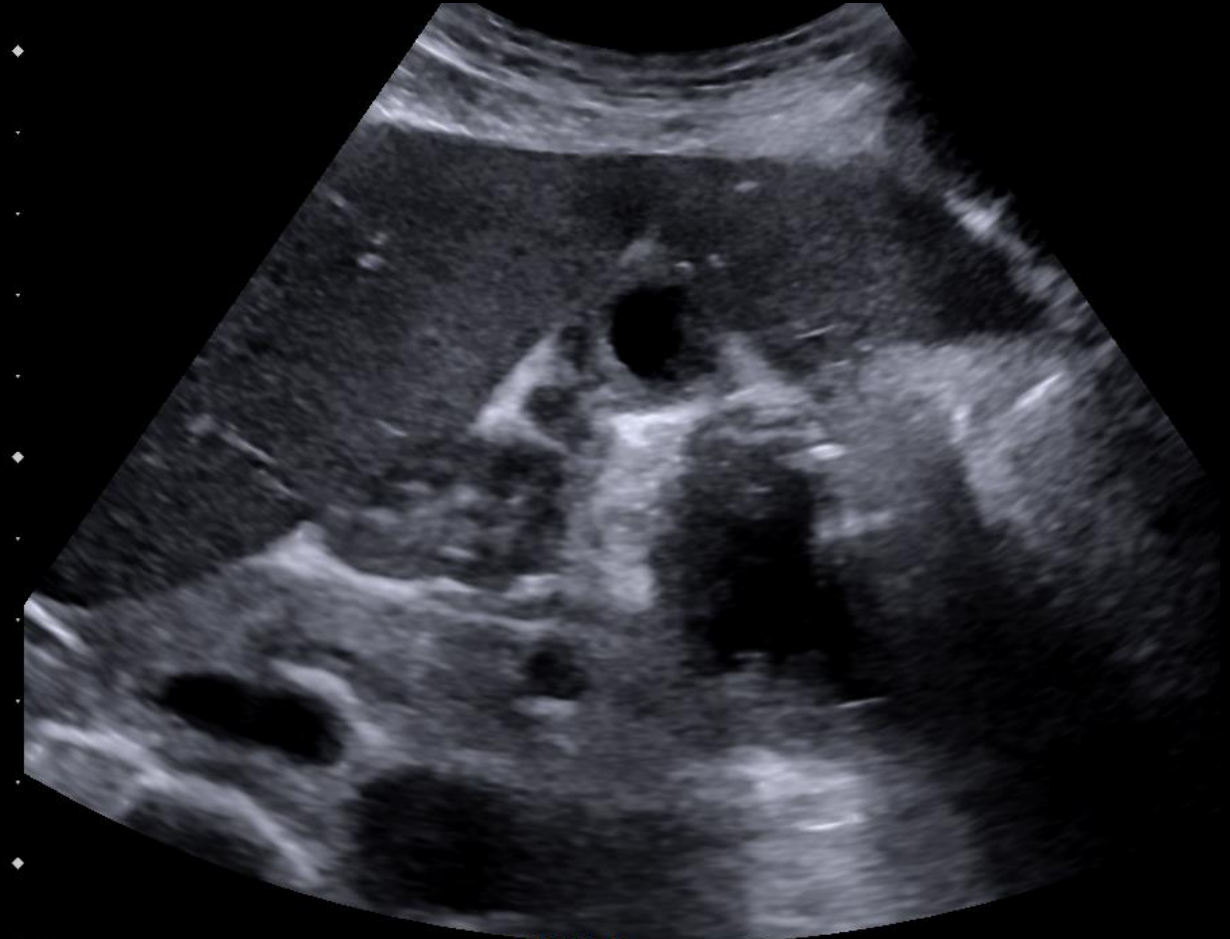US Findings

1 GB Wall=0.78 cm



GB LONG SUPINE

9cm

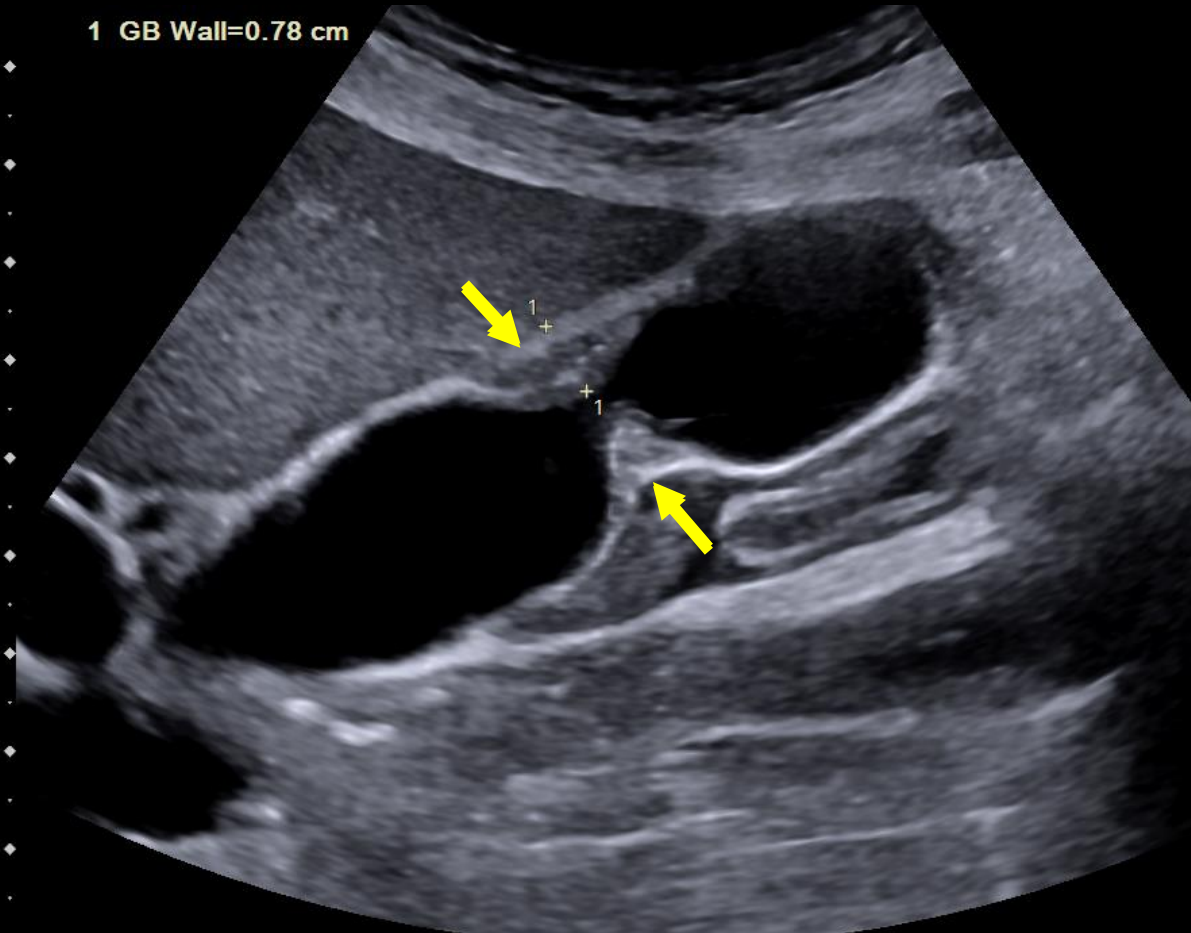


GB LLD

11cm

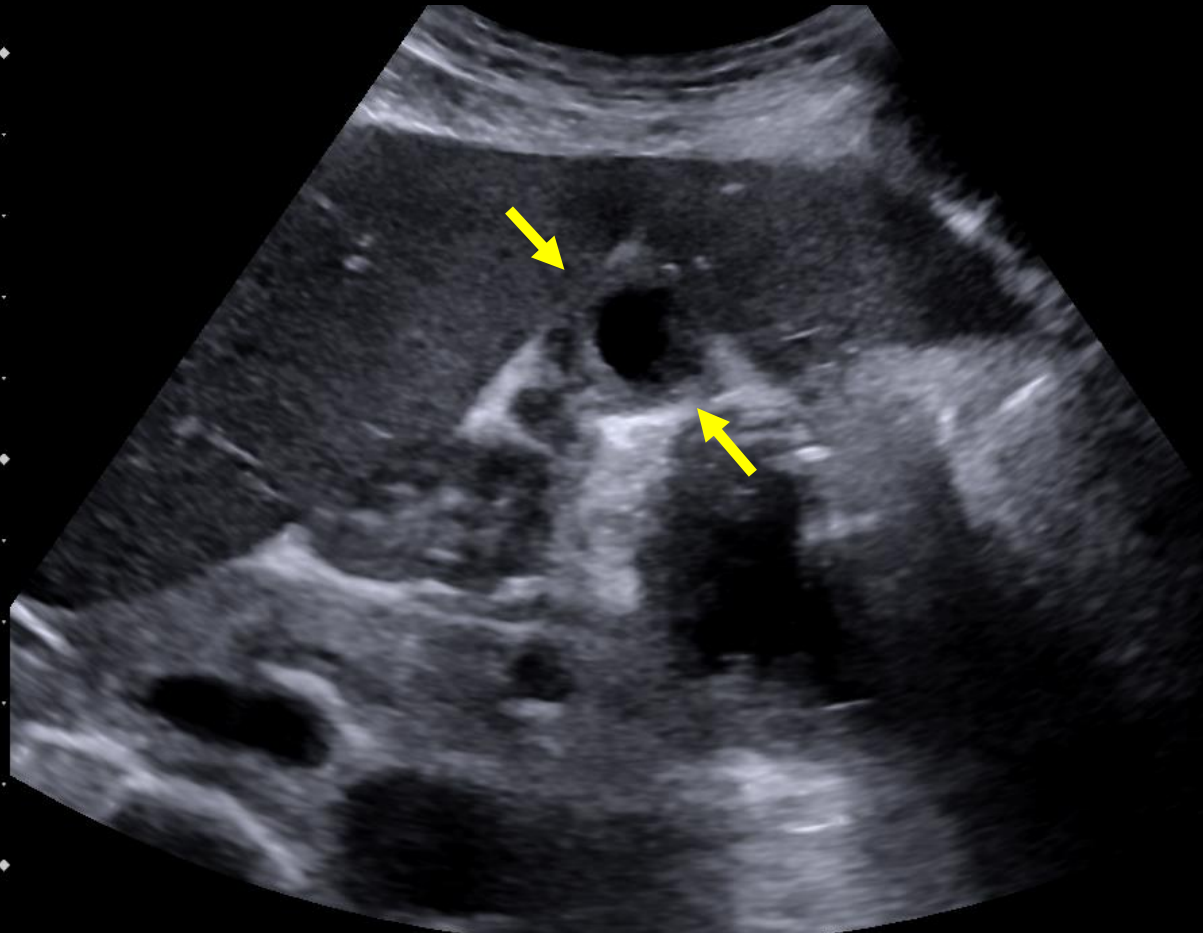
US Findings (labeled)

1 GB Wall=0.78 cm



9cm

GB LONG SUPINE

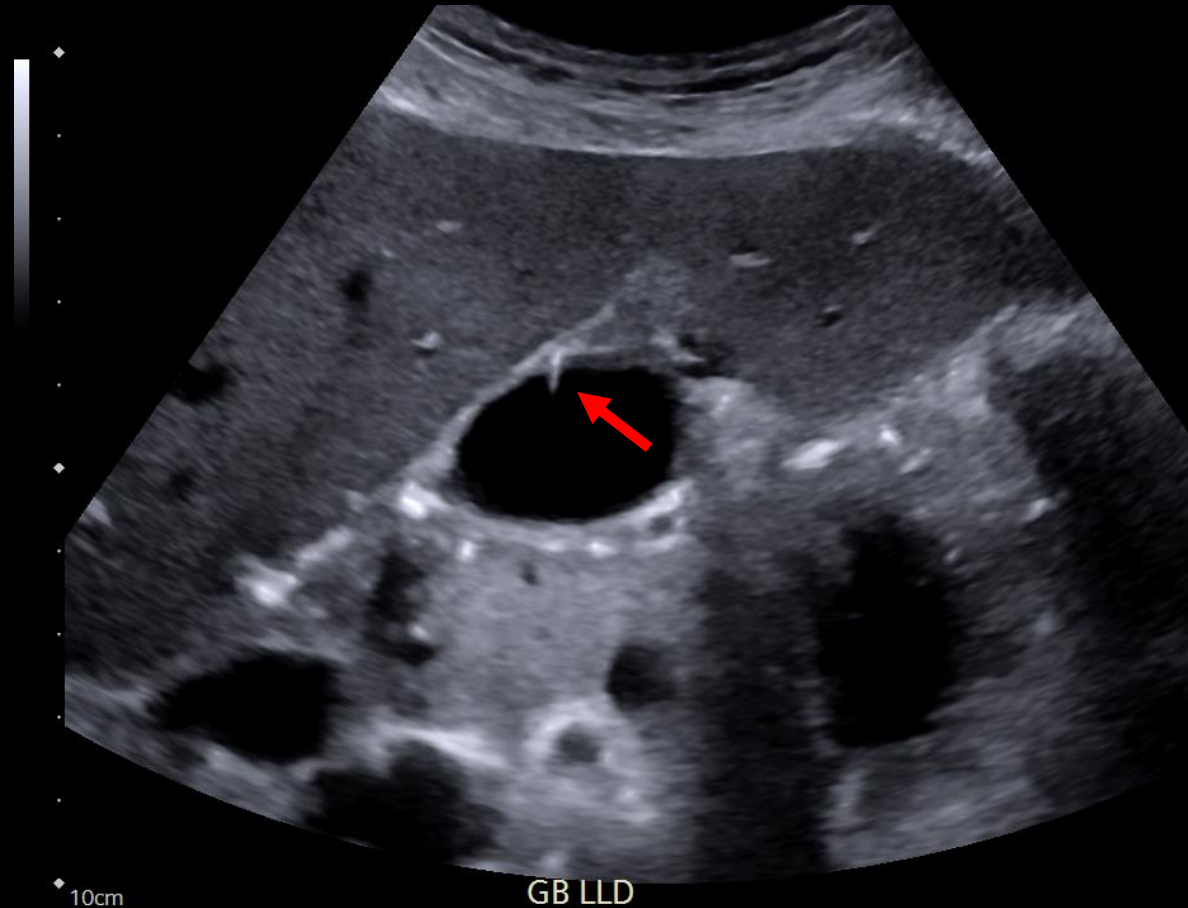


11cm

GB LLD

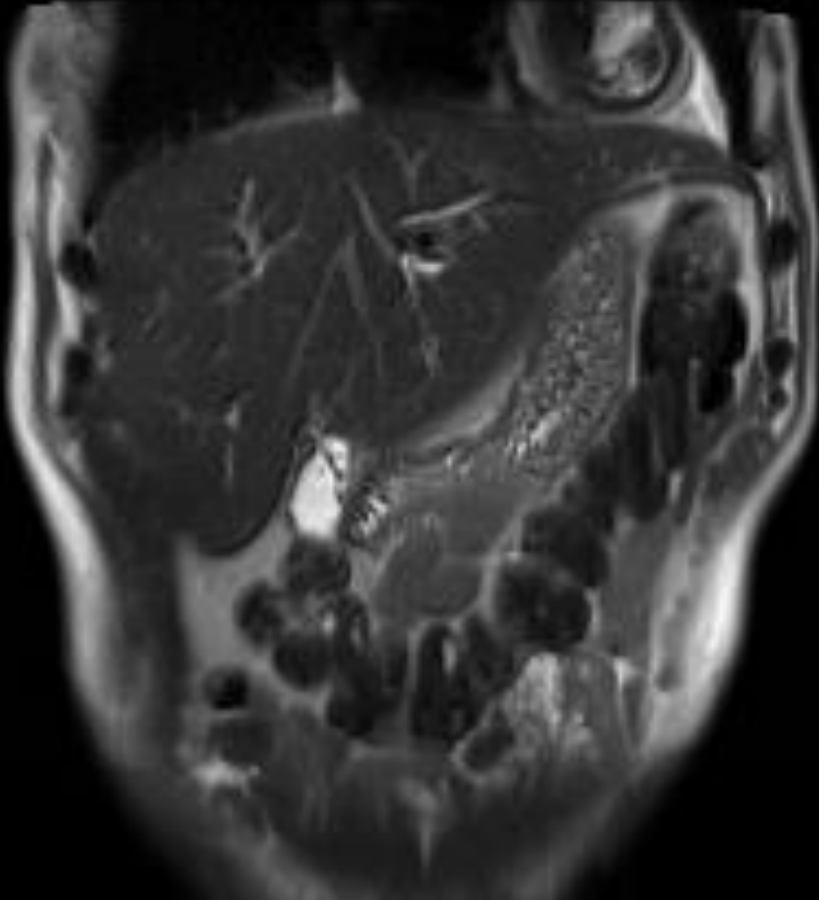
- Thickened gallbladder wall (0.78cm)
- Mid-gallbladder stricture (→)

US Findings (labeled)

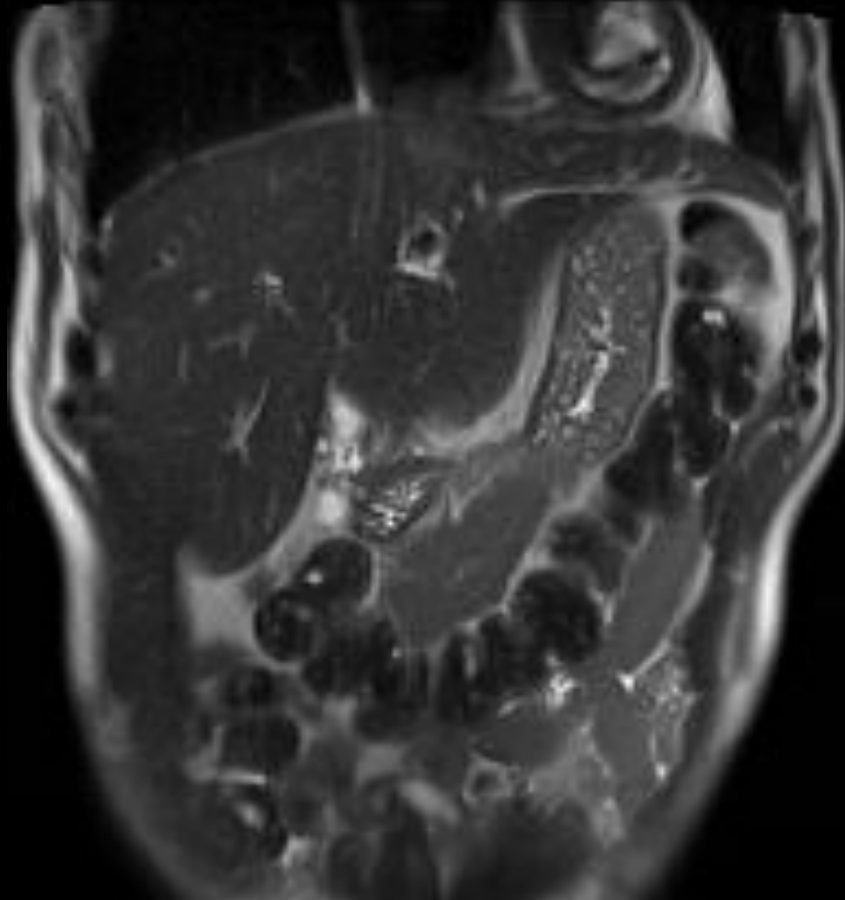


- Additional image with possible adjacent comet tail artifact (→)

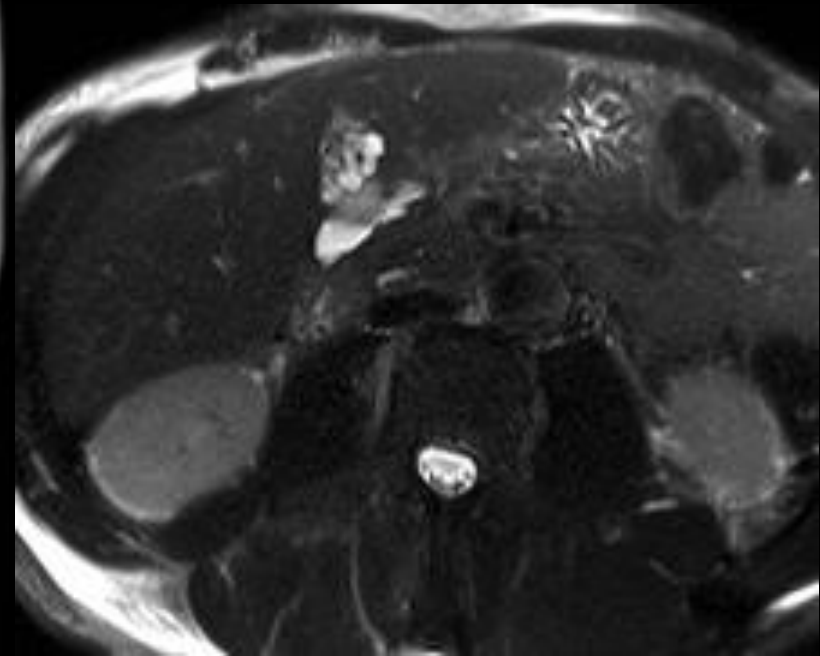
MRCP Findings



Coronal T2

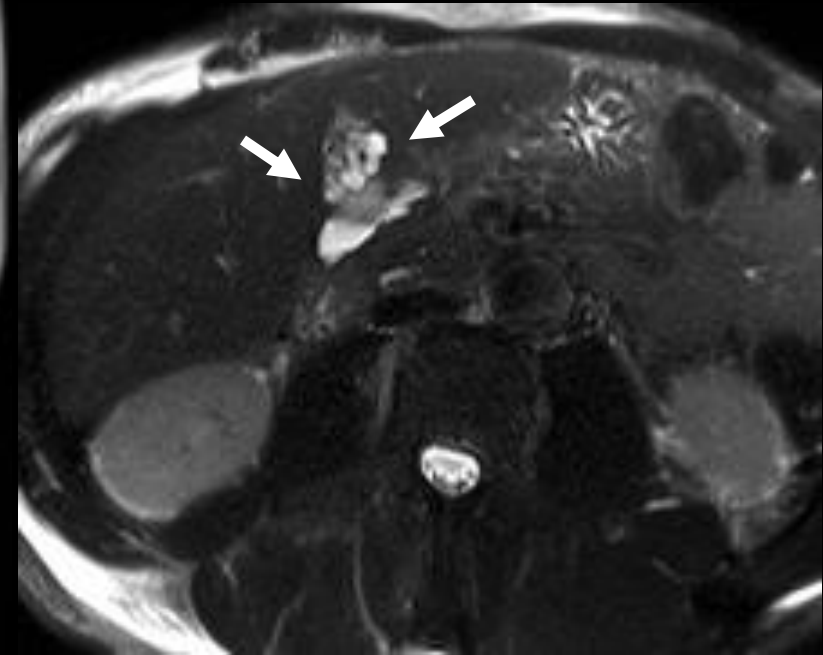
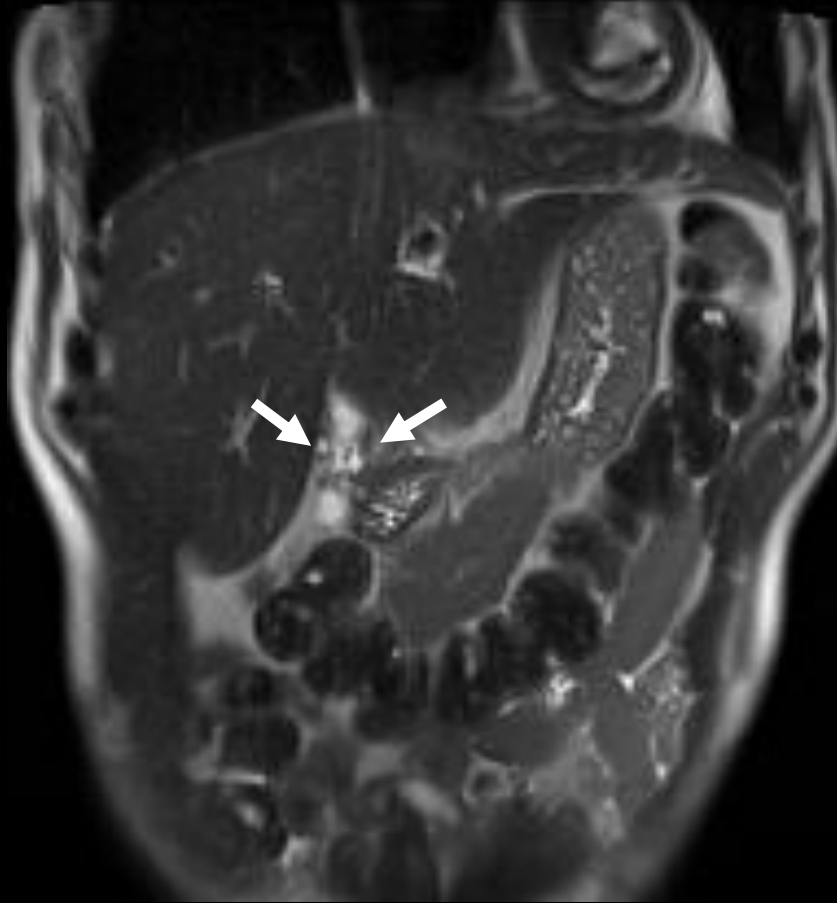
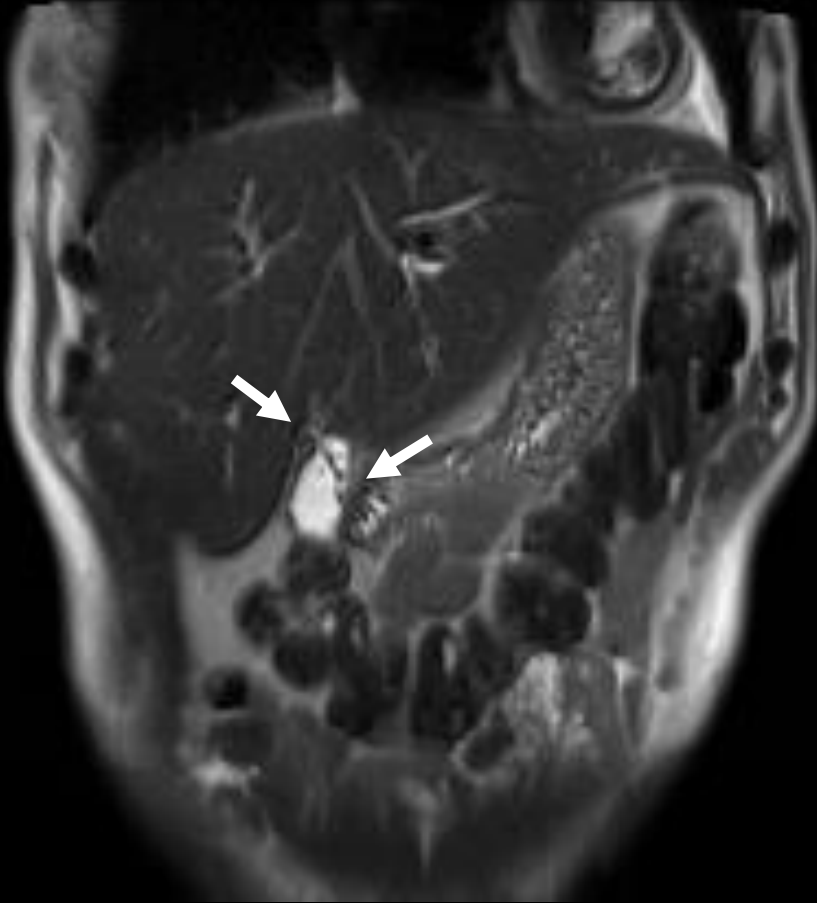


Coronal T2



Axial T2

MRCP Findings



- Up to 6mm Annular wall thickening of the gallbladder body
- Multiple hyperintense cystic spaces within thickened gallbladder wall, the “pearl necklace sign” (→)

F/u US imaging 12mo. later
confirmed stable findings

Diagnosis?

Annular Adenomyomatosis

Case Discussion

- In patients receiving imaging for unrelated medical issues, care must always be taken to accurately identify incidental findings that could have profound effects on the trajectory of a patient's life
- In our case, the notable unreliability of clinical features in diagnosis of gallbladder adenocarcinoma and its propensity to mimic the non-specific imaging findings of other gallbladder pathologies (i.e. adenomyomatosis) on CT and US made the differential a serious concern that necessitated follow up^{1,2}
- Adenomyomatosis of the gallbladder is a benign process, incidentally present in up to 9% of patients by some estimates³, characterized by hyperplasia of the epithelium and muscularis propria leading to gallbladder wall thickening. Subsequent diverticular-turned-cystic spaces called Rokitansky-Aschoff sinuses (RAS) form filled with bile within this wall. Over time, precipitated cholesterol crystals within the RAS accumulate and undergo calcification^{2,4}
 - The “Pearl Necklace Sign” of T2w MR images is due to these hyperintense RAS
 - Also, the “Comet Tail” artefact on US is due to the calcification within the RAS
- The major patterns of adenomyomatosis include: ^{2,4}
 - Localized/Focal/Fundal – typically involves the distal fundus alone
 - Segmental/Annular – circumferential, ring-like thickening of mid-gallbladder wall with involvement of fundus and/or distal third
 - Diffuse – wall thickening involving the entire corpus of the gallbladder wall

Case Discussion

- Non-specific imaging findings that present across both adenomyomatosis and adenocarcinoma can include:
 - **US:** Mural thickening
 - **CT:** Mural thickening, non-specific calcification
 - **PET-CT:** Cases of abnormal uptake present in both
 - **MR:** Mural thickening, possible sessile mass
- Distinguishing features on US (comet tail artefact), on CT (particularly large RAS with calcification), and on MRI (pearl necklace sign) are often absent features, introducing diagnostic uncertainty.
- Recent data provides support in the differential of adenomyomatosis vs adenocarcinoma that contrast enhanced US (CEUS) has enhanced accuracy in diagnosis compared to traditional US methods (95.2% vs 88.6%), and in-particular a much greater positive predictive value (80.0% vs 60.9%)⁵. Adenomyomatosis has enhancement similar to normal gallbladder wall with cystic spaces, whereas adenocarcinoma has heterogeneous early enhancement and washout.
- However, with an accuracy of 93% MRI has traditionally been the modality with the greatest degree of accuracy in differentiating between gallbladder adenocarcinoma and adenomyomatosis. It's use generally reserved for cases that are unclear on ultrasonographic imaging. ⁴

References:

1. Goetze TO. Gallbladder carcinoma: Prognostic factors and therapeutic options. *World J Gastroenterol*. 2015;21(43):12211-12217. <https://doi.org/10.3748/wjg.v21.i43.12211>
2. Ryu Y, Nicoletti D, Silverstone L, et al. Adenomyomatosis of the gallbladder. Reference article, Radiopaedia.org (Accessed on 26 Nov 2025) <https://doi.org/10.53347/rID-7056>
3. Mellnick V, Menias C, Sandrasegaran K et al. Polypoid Lesions of the Gallbladder: Disease Spectrum with Pathologic Correlation. *Radiographics*. 2015;35(2):387-99. <https://doi.org/10.1148/rg352140095>
4. Bonatti, M., Vezzali, N., Lombardo, F. et al. Gallbladder adenomyomatosis: imaging findings, tricks and pitfalls. *Insights Imaging* 8, 243–253 (2017). <https://doi.org/10.1007/s13244-017-0544-7>
5. Zhang HP, Bai M, Gu JY, He YQ, Qiao XH, Du LF. Value of contrast-enhanced ultrasound in the differential diagnosis of gallbladder lesion. *World J Gastroenterol*. 2018;24(6):744-751. <https://doi.org/10.3748/wjg.v24.i6.744>