

AMSER Case of the Month

December 2022

74-year-old female with epigastric pain and nausea

Nicholas John Mynarski (MS4)
Geisinger Commonwealth School of Medicine

Lindsey Negrete, MD
Stanford University



Patient Presentation

- **HPI:** A 74 y/o woman presented to the emergency room with left chest and epigastric pain with associated nausea.
- **PMH:** Celiac disease, GERD, microscopic colitis, and esophageal spasm
- **Social History:** 4 pack year smoking history. Patient drinks approximately 4-5 glasses of wine per week
- No pertinent surgical or family history. No known allergies.

Patient Presentation

- **ROS:** Minor constipation, no abdominal pain, no vomiting, no diarrhea, no blood in stool, no fevers, no chills, no night sweats, no palpitations, no significant changes in weight.
- **Physical Exam:** Vitals Stable. Normal S1/S2. Lungs clear to auscultation bilaterally. Normal bowel sounds noted. No abdominal tenderness. No palpable masses.
- **Lab Values:** No significant lab findings.

What Imaging Should We Order?

Epigastric Pain ACR Appropriateness Criteria

New 2021

American College of Radiology ACR Appropriateness Criteria® Epigastric Pain

Variant 1: Epigastric pain with clinical suspicion for acid reflux or esophagitis or gastritis or peptic ulcer or duodenal ulcer. Initial imaging.

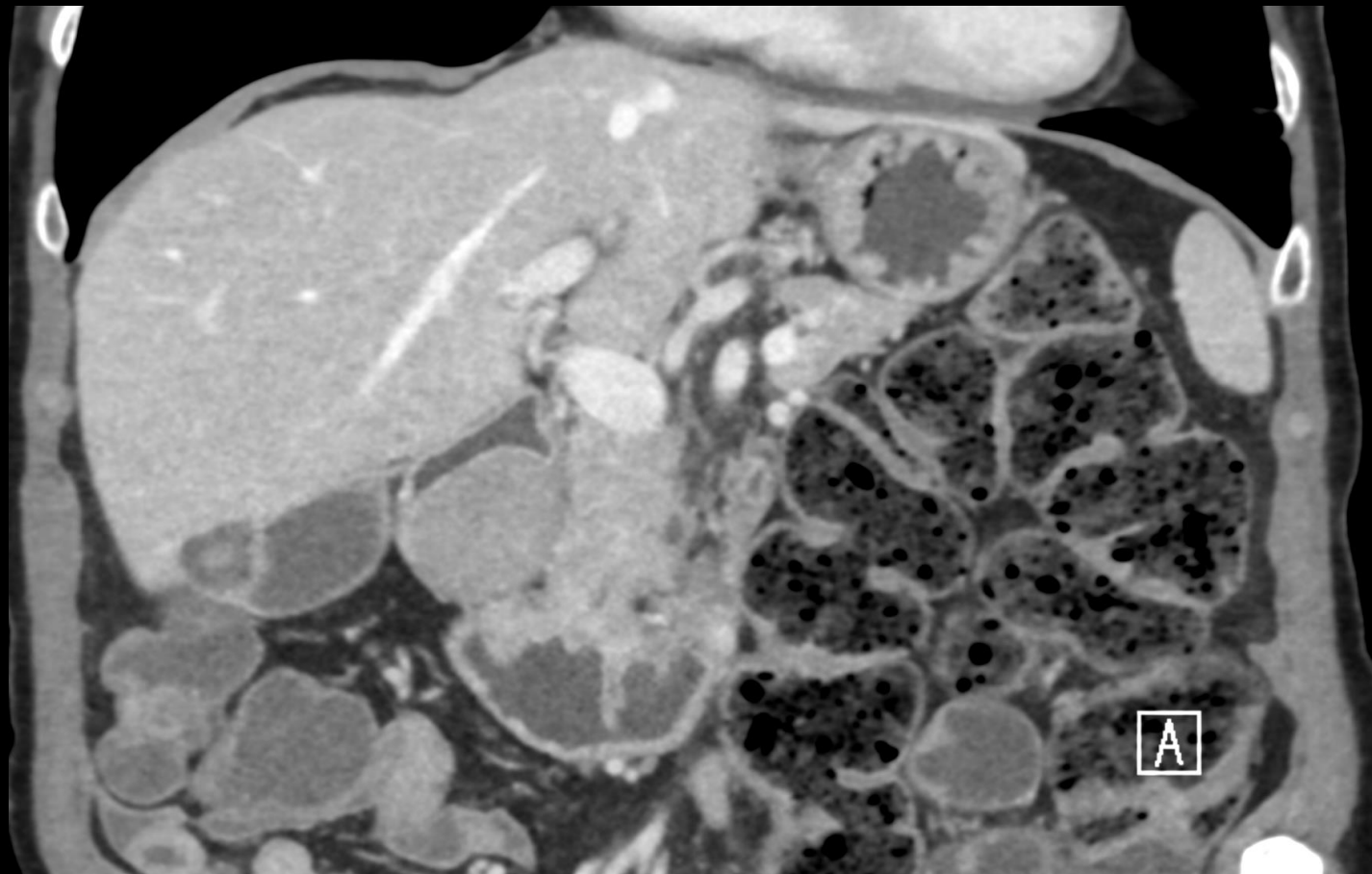
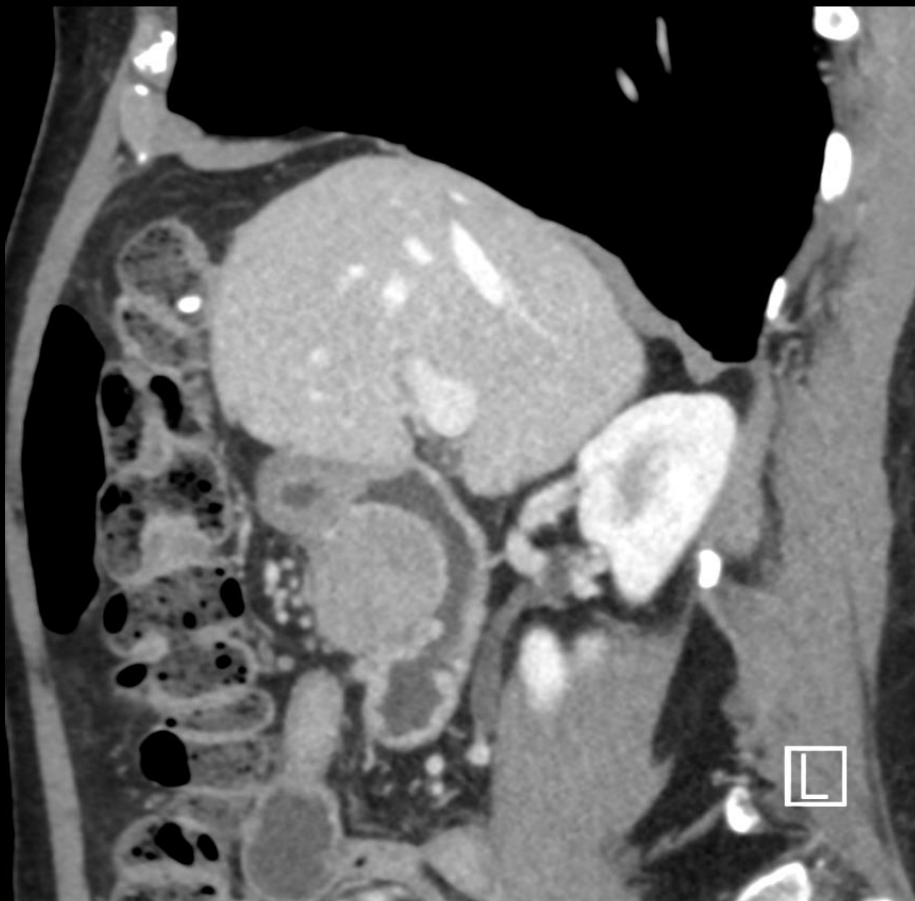Procedure	Appropriateness Category	Relative Radiation Level
Fluoroscopy biphasic esophagram	Usually Appropriate	☺☺☺
Fluoroscopy upper GI series	Usually Appropriate	☺☺☺
Fluoroscopy single contrast esophagram	May Be Appropriate	☺☺☺
CT abdomen and pelvis with IV contrast	May Be Appropriate	☺☺☺
CT abdomen and pelvis without IV contrast	May Be Appropriate	☺☺☺
CT abdomen with IV contrast	May Be Appropriate (Disagreement)	☺☺☺
MRI abdomen without and with IV contrast	Usually Not Appropriate	○
MRI abdomen without and with IV contrast with MRCP	Usually Not Appropriate	○
MRI abdomen without IV contrast	Usually Not Appropriate	○
MRI abdomen without IV contrast with MRCP	Usually Not Appropriate	○
CT abdomen without IV contrast	Usually Not Appropriate	☺☺☺
CT abdomen and pelvis without and with IV contrast	Usually Not Appropriate	☺☺☺☺
CT abdomen with IV contrast multiphase	Usually Not Appropriate	☺☺☺☺
CT abdomen without and with IV contrast	Usually Not Appropriate	☺☺☺☺
FDG-PET/CT skull base to mid-thigh	Usually Not Appropriate	☺☺☺☺



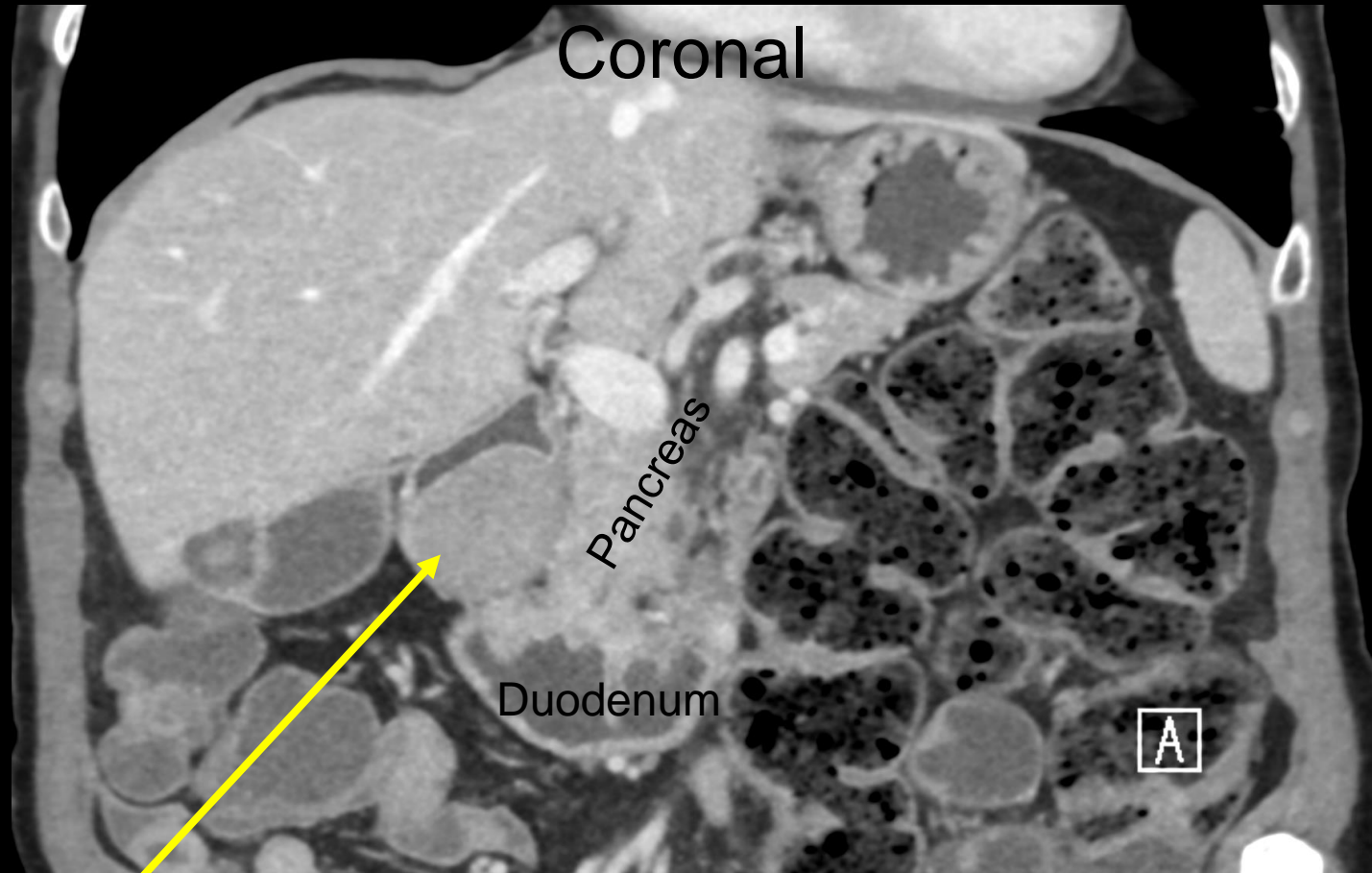
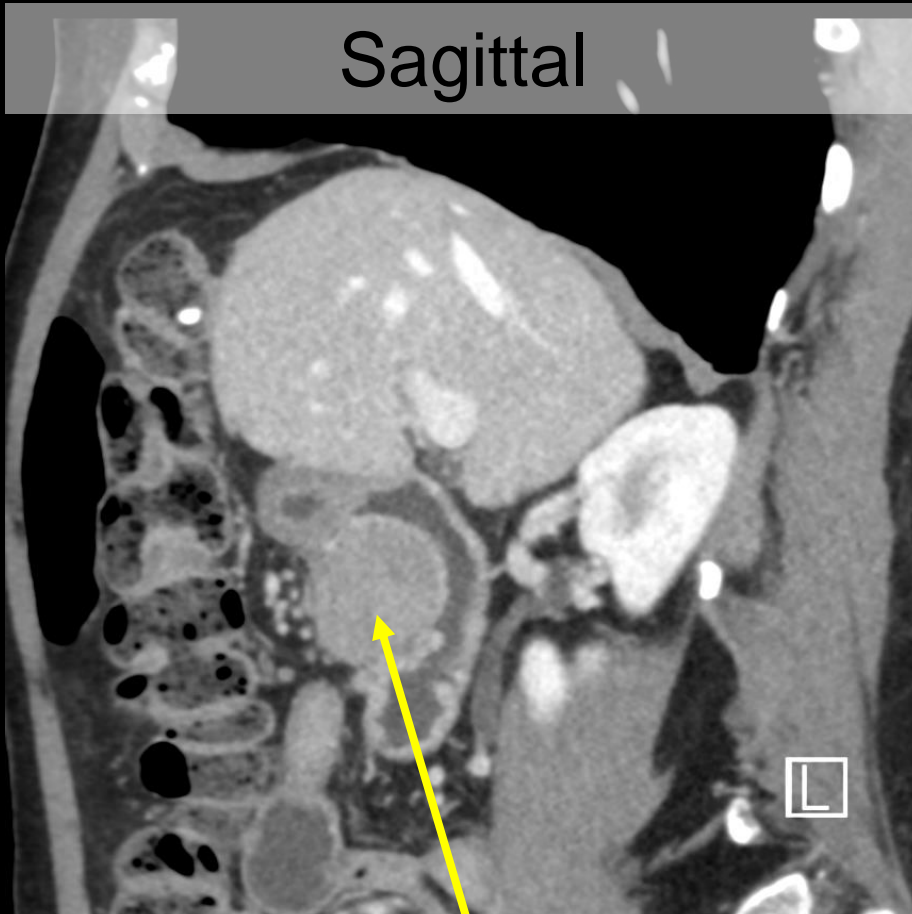
This imaging modality was ordered by the ER physician



Findings: Unlabeled Contrast Enhanced CT



Findings: Labeled Contrast Enhanced CT



Homogeneously enhancing submucosal mass measuring 3.5 x 3.3 cm in the first / second portion of the duodenum. The lumen of the bowel is narrowed but there is no associated gastric outlet obstruction.

Follow up + Pathology Findings

- The patient's original symptomatology of epigastric pain and nausea was attributed to her PMH of esophageal spasm.
- After discovering the incidental mass, the patient underwent endoscopic ultrasound (EUS) with biopsy. Pathology results demonstrated:
 - Well-circumscribed spindle cell neoplasm with eosinophilic cytoplasm and elongated cigar shaped nuclei
 - No mitotic activity or necrosis; some nuclear atypia
 - Desmin and ActM positive. CD117 and HMB45 negative
 - Supports smooth muscle cell differentiation

Final Diagnosis:
Duodenal Leiomyoma

Discussion: Background

- The small intestine is the 2nd most common site for smooth muscle tumors.
 - These tumors are most commonly found in the jejunum, followed by the ileum, and the duodenum.
- Accounting for over 80 percent of cases, the most common type of intestinal mesenchymal tumors are gastrointestinal stromal tumors (GIST).
 - The remaining, far less common, group of stromal tumors include lipomas, liposarcomas, leiomyosarcomas, and leiomyomas.

Discussion: Clinical Presentation and Treatment

- Intestinal mesenchymal tumors are generally large at diagnosis and their presentation is generally late.
 - Associated symptoms include bleeding into the GI tract, abdominal pain, weight loss, perforation, obstruction, or a palpable mass.
- Treatment for most GISTs, leiomyomas, and leiomyosarcomas of the small bowel consists of en block segmental resection with tumor-free margins.
 - Pancreaticoduodenectomy is reserved for lesions that are not amenable to local resection.

Discussion: Patient's Course

- The patient underwent robotic distal gastrectomy with Billroth II configuration of gastrojejunostomy.
- After some minor post-op complications, including ileus, the patient was discharged from the hospital.
- On follow-up, the patient noted no pain, erythema or drainage from the incisional sites. The patient tolerated her usual diet and reported no other concerns or symptoms at that time.

References:

1. Blanchard DK, Budde JM, Hatch GF 3rd, et al. Tumors of the small intestine. *World J Surg*. 2000;24(4):421-429.
doi:10.1007/s002689910067
2. Miettinen M, Kopczynski J, Makhlouf HR, et al. Gastrointestinal stromal tumors, intramural leiomyomas, and leiomyosarcomas in the duodenum: a clinicopathologic, immunohistochemical, and molecular genetic study of 167 cases. *Am J Surg Pathol*. 2003;27(5):625-641.
doi:10.1097/00000478-200305000-00006
3. Rijcken E, Kersting CM, Senninger N, Bruewer M. Esophageal resection for giant leiomyoma: report of two cases and a review of the literature. *Langenbecks Arch Surg*. 2009;394(4):623-629.
doi:10.1007/s00423-008-0365-8