

# AMSER Case of the Month

## October 2022

HPI: 50 y.o. F presents for annual gynecology exam

Sreya Doddakashi, MS-4

Cooper Medical School of Rowan University

Julia Kahn, DO

Cooper University Hospital

Pauline Germaine, DO

Cooper University Hospital



# Patient Presentation

- HPI: 50 y.o. F presents for annual gynecology exam
- PMHx: Non-contributor
- Medications: Non-contributor
- PSHx: Non-contributor
- FHx: Colon cancer in paternal uncle
- Screenings: Mammography 2016, 2019
- PE: Normal
- Pertinent labs: None

Given prior annual screening mammogram was in 2019, what imaging should we order for health maintenance purposes at this time?

# Applicable ACR Appropriateness Criteria

## Variant 1:

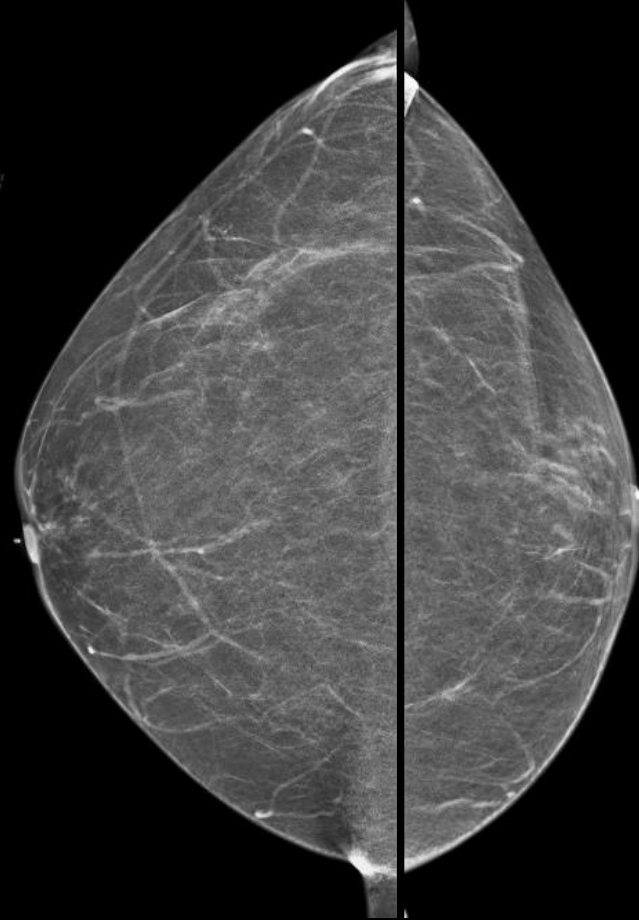
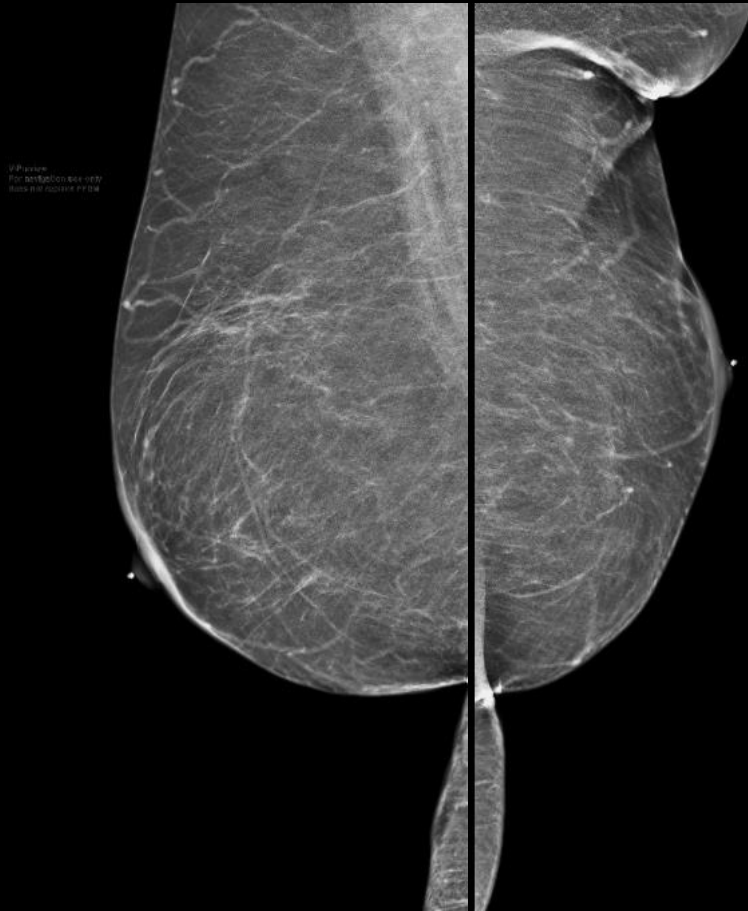
**Breast cancer screening. Average-risk women: women with <15% lifetime risk of breast cancer.**

Procedure	Appropriateness Category	Relative Radiation Level
Mammography screening	Usually Appropriate	☼☼
Digital breast tomosynthesis screening	Usually Appropriate	☼☼
US breast	May Be Appropriate	○
MRI breast without and with IV contrast	Usually Not Appropriate	○
MRI breast without IV contrast	Usually Not Appropriate	○
FDG-PET breast dedicated	Usually Not Appropriate	☼☼☼☼
Sestamibi MBI	Usually Not Appropriate	☼☼☼

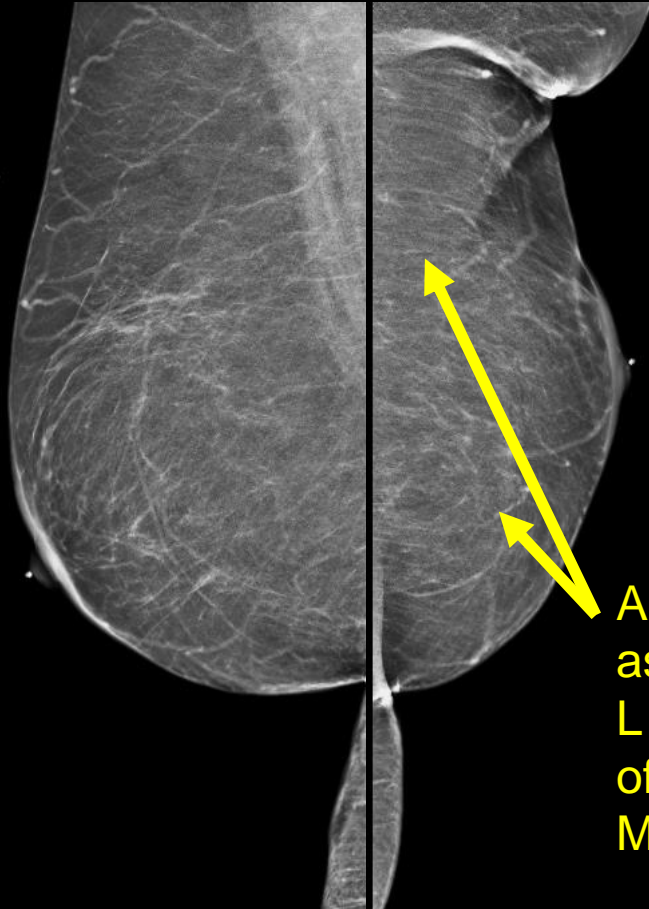
This imaging modality was ordered by OB/GYN



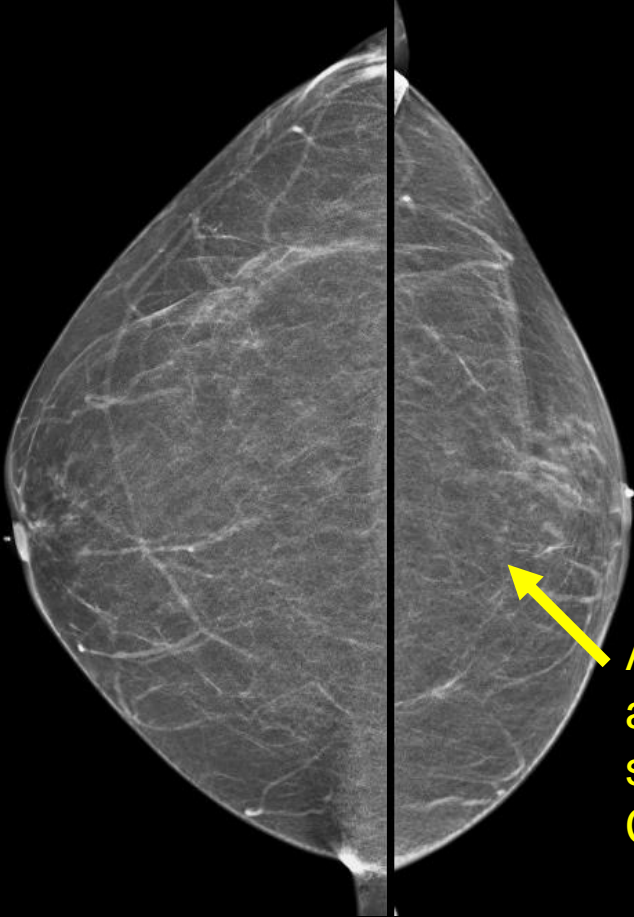
# Findings: (unlabeled)



# Findings: (labeled)



Arrows demonstrates asymmetrically smaller L breast and absence of pectoralis major on MLO view



Arrow demonstrates asymmetrically smaller L breast on CC view

Final Dx:

Poland Syndrome

# Poland Syndrome

- Definition

- Poland Syndrome is a rare congenital condition that is characterized by unilateral absence or underdevelopment of chest-wall muscles (pectoralis minor and/or sternal/breastbone portion of the pectoralis major) and by limb abnormalities
- Affected individuals may also have malformations of underlying rib cage, long bones, breasts or kidneys

- Etiology

- Unclear etiology but it's hypothesized that there is a disruption in blood supply to embryonic tissues that give rise to chest wall

- Epidemiology

- 1 in 36,000 to 50,000 newborns, with males more likely to be affected with a right-sided predominance



# Evaluation and Management

- Imaging

- Prenatal sonographic evaluation can demonstrate unilateral limb defects and unilateral wall asymmetry
- Adult patients
  - CT is sufficient for diagnosis and helpful for surgical planning and further evaluation for associated cardiopulmonary abnormalities
  - Mammography: hypoplasia of unilateral breast and hypoplasia or absence of pectoralis major
  - CXR: unilateral hyperlucent thorax
  - Ultrasound: chest wall to evaluate for defects of pectoralis major and minor musculature

- Treatment/Management

- Treatment is directed towards symptom relief, requiring coordination amongst various specialists, including plastic surgeons for rebuilding of chest wall and construction of breast mound, physical therapy to improve limitations of motion and genetic counseling

# References:

Kennedy, K. R. (n.d.). *Poland syndrome: Nejm*. New England Journal of Medicine. Retrieved August 12, 2022, from [https://www.nejm.org/doi/10.1056/nejmicm1709713?url\\_ver=Z39.88-2003&rfr\\_id=ori%3Arid%3Acrossref.org&rfr\\_dat=cr\\_pub%2B%2B0www.ncbi.nlm.nih.gov](https://www.nejm.org/doi/10.1056/nejmicm1709713?url_ver=Z39.88-2003&rfr_id=ori%3Arid%3Acrossref.org&rfr_dat=cr_pub%2B%2B0www.ncbi.nlm.nih.gov)

*Medical history - statpearls - NCBI bookshelf*. (n.d.). Retrieved August 12, 2022, from <https://www.ncbi.nlm.nih.gov/books/NBK534249/>

Sencen, L. (2015, June 30). *Poland syndrome*. NORD (National Organization for Rare Disorders). Retrieved August 12, 2022, from <https://rarediseases.org/rare-diseases/poland-syndrome/>