

AMSER Case of the Month

October 2022

A 9-year-old female initially presented with 1 day of intermittent LLQ pain, nausea, and fever

Lauren Hoff, MS, Daniel Schneider, MD, & Maria Ladino-Torres, MD

The University of Michigan, Ann Arbor



Patient Presentation

History

- 9-year-old female with history of tricuspid atresia/VSD/ASD s/p Fontan, and thrombotic basilar artery stroke s/p thrombectomy presented to outside ED with 1 day of intermittent LLQ pain, nausea, and fever.
- Patient was initially diagnosed with constipation and discharged home, but symptoms persisted after several doses of Miralax and enemas.
- On day 2 of symptoms, patient presented to Mott ED for further evaluation.

Physical Exam Findings

- Mild LLQ tenderness without rebound or guarding. No palpable mass

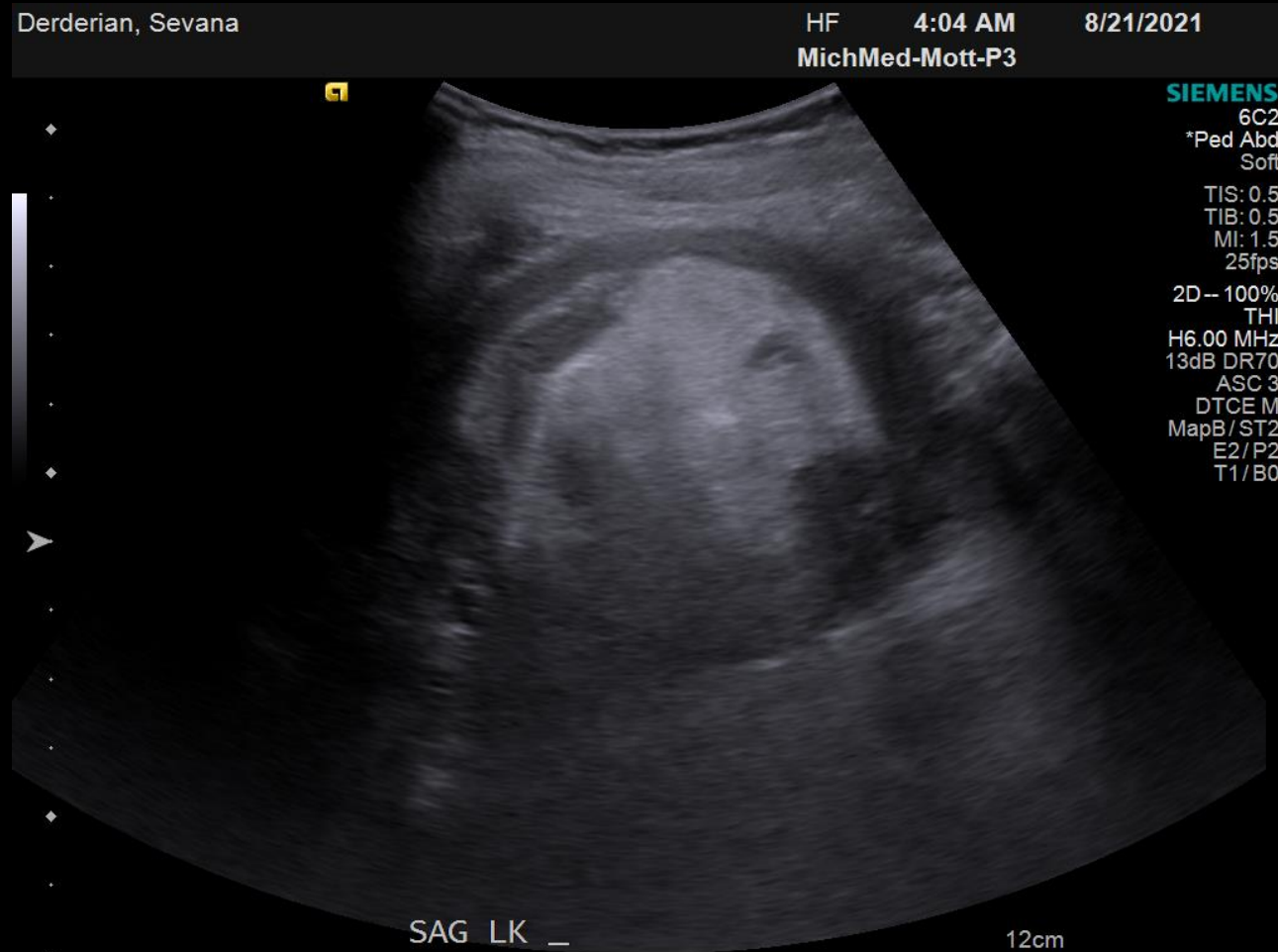Initial Labs

- CBC - WBC 16
- CMP - Normal AST/ALT, Alk Phos 228, Total Bilirubin 7.6
- UA - Negative

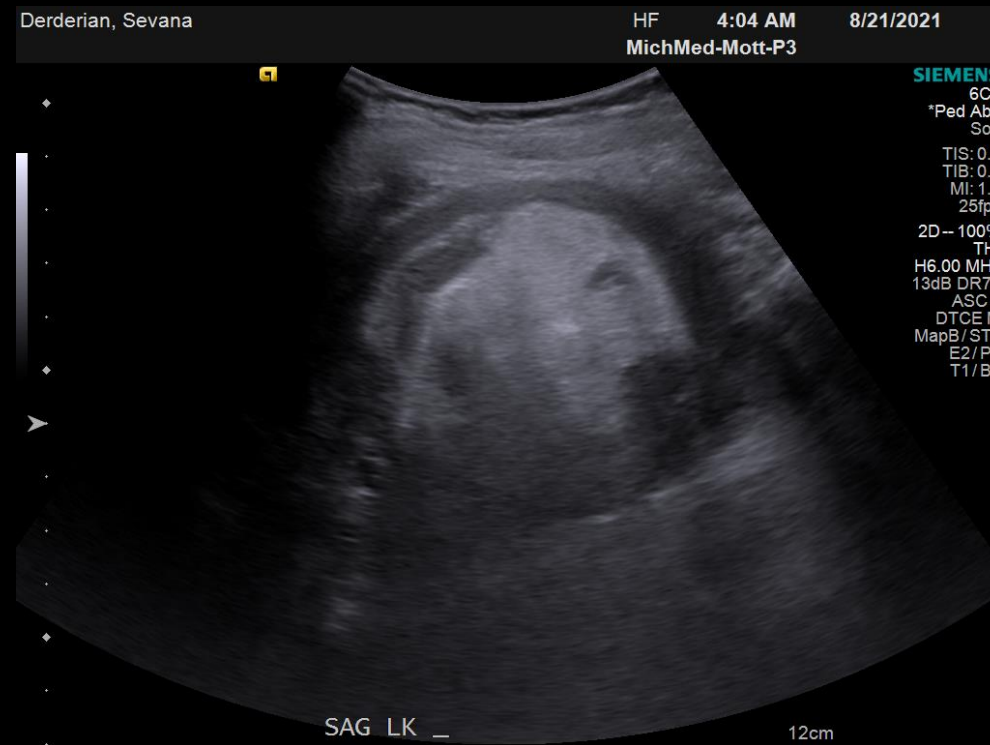
What Imaging Should We Order?

- **ED differential diagnosis:** constipation vs ovarian torsion
- **ACR Appropriateness Criteria**
 - No guidelines for suspected ovarian torsion in a prepubescent 9-year-old
 - In reproductive-age females with negative B-hCG, guidelines recommend transvaginal and transabdominal ultrasound with duplex doppler.
- ED provider obtained abdominal ultrasound

Abdominal Ultrasound (unlabeled)

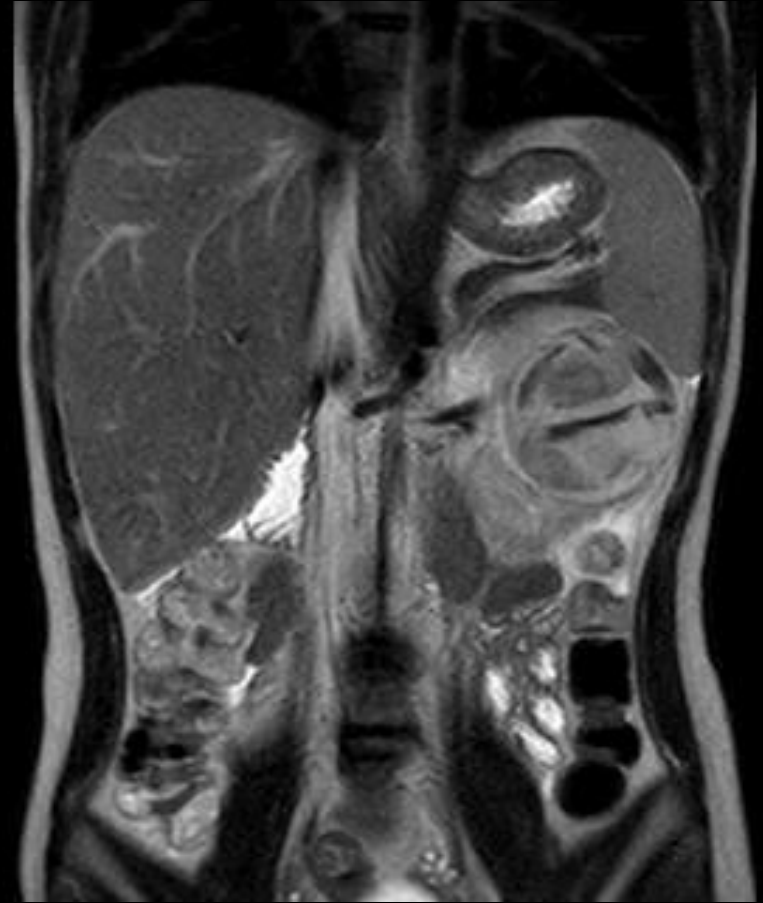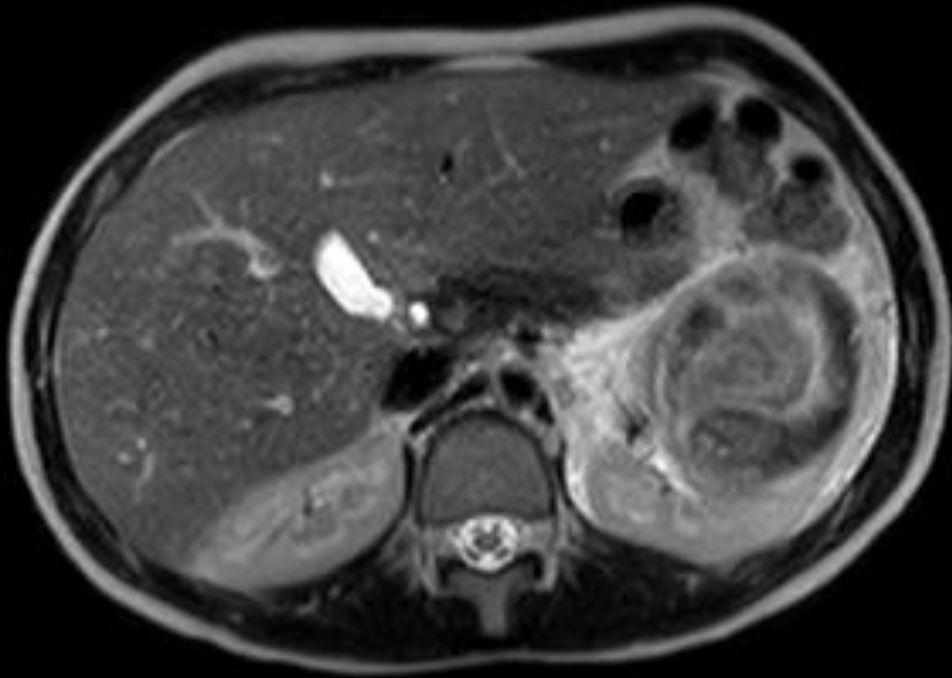


Abdominal Ultrasound (labeled)

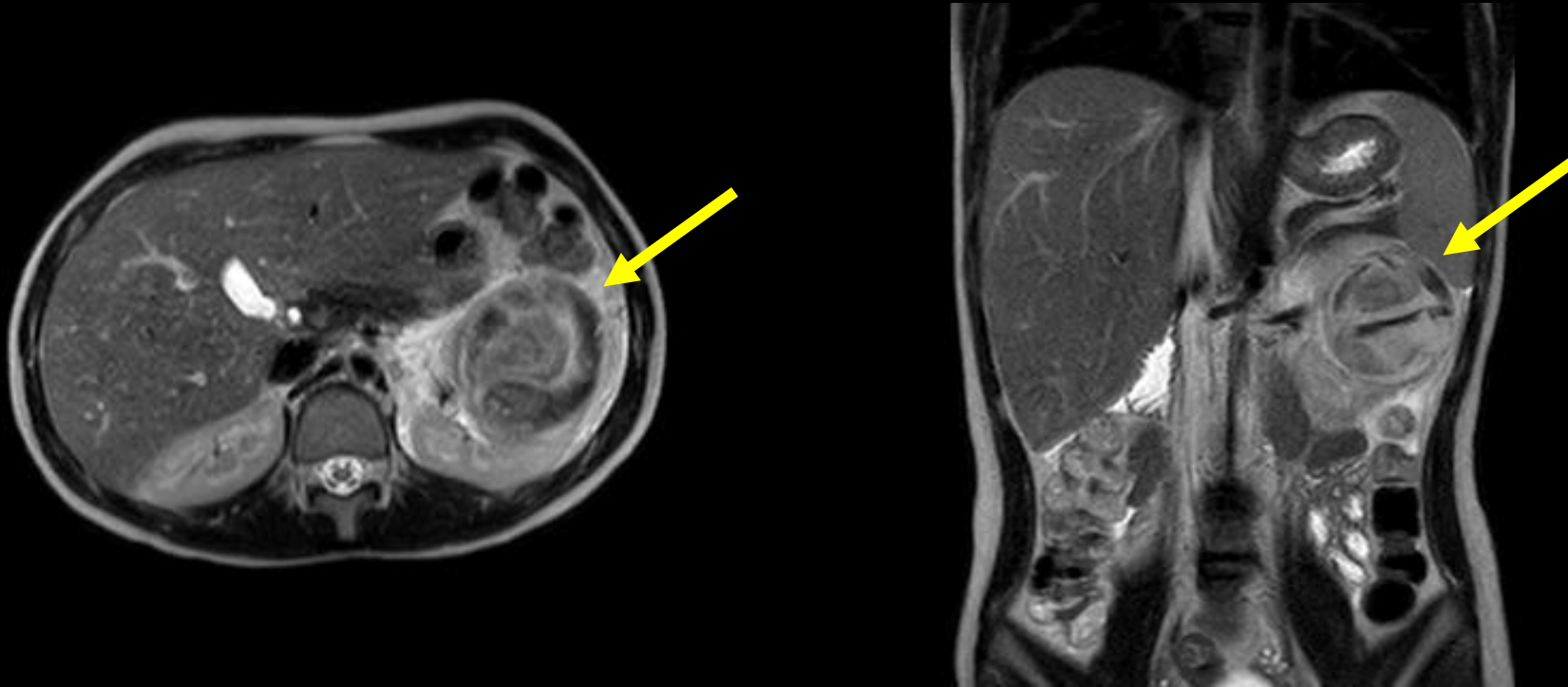


Ultrasound through the left renal fossa revealed an indeterminate heterogeneous though predominantly hyperechoic mass, thought to be arising from the left renal hilum.

MR Abdomen (unlabeled)

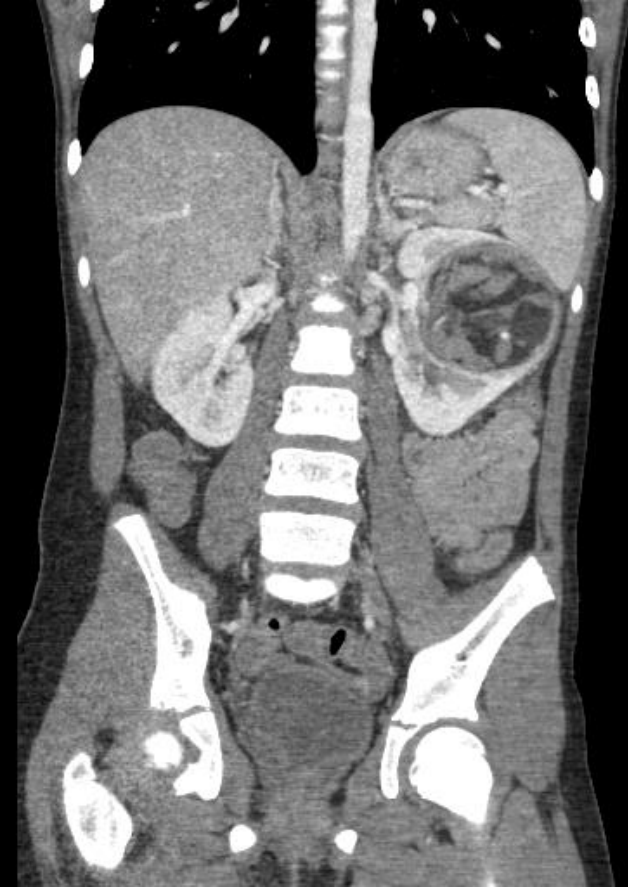
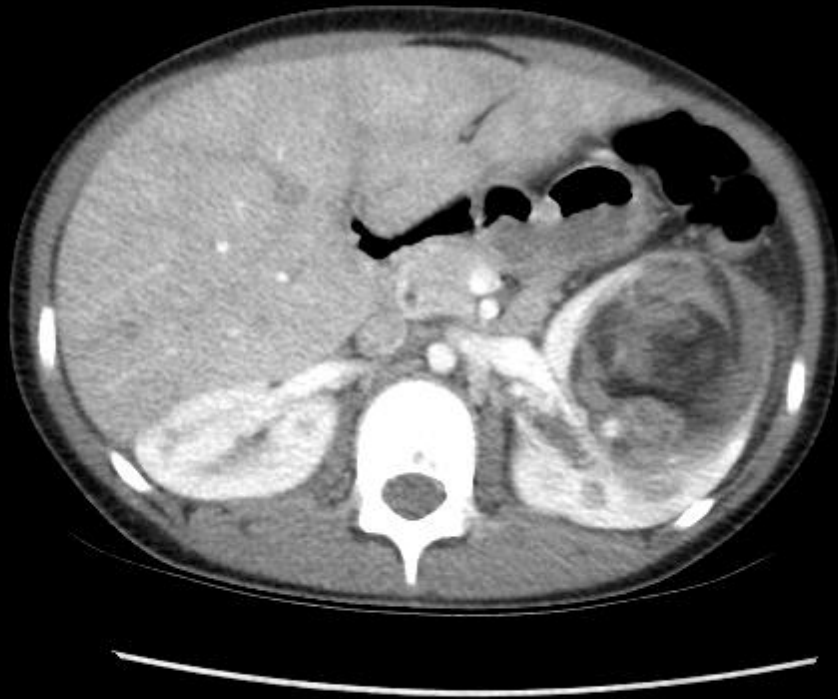

MR Abdomen (labeled)

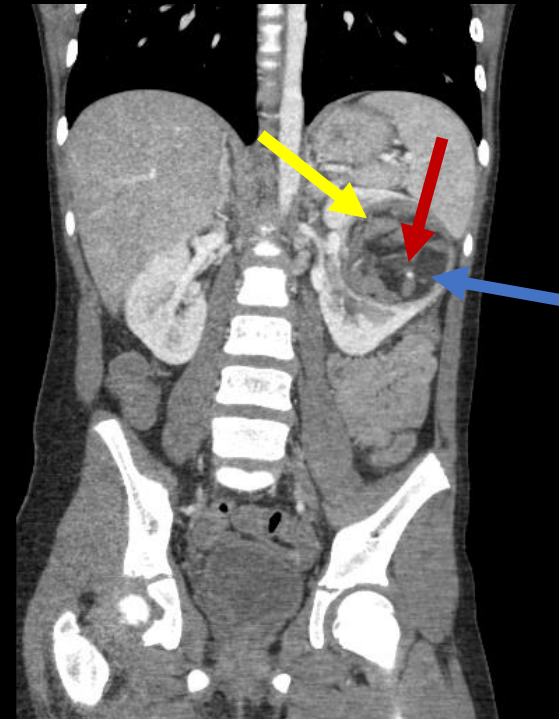
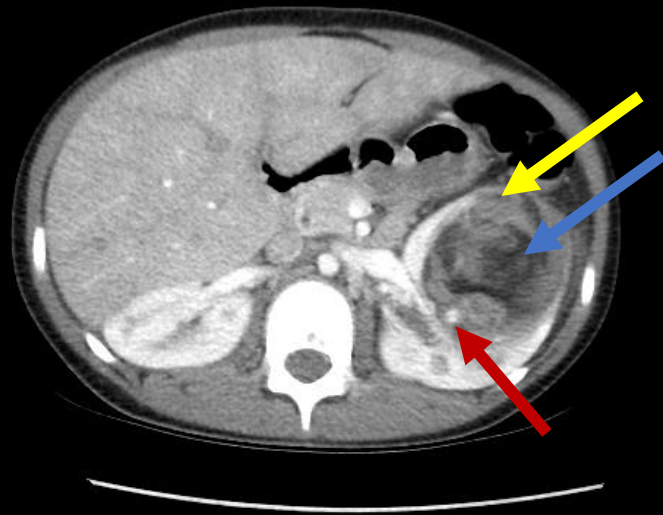


MR abdomen revealed a **heterogeneous mass**, measuring up to 6 cm, extending medially into the renal pelvis with mild enhancement and suggestion of some subtle areas of fat or hemorrhage. The left renal vein and IVC were patent. This was thought to represent a neoplastic process, such as Wilms tumor, angiomyolipoma, or teratoma.

CT Abdomen/Pelvis (unlabeled)



CT Abdomen/Pelvis (labeled)



We again see a large bilobed intraparenchymal left renal mass which extends toward the renal hilus. The mass appears to contain mature fat (**hypodense regions**), **soft tissue (intermediate density)** and perhaps **enhancing vascular structures**. Considerations include angiomyolipoma, renal teratoma, renal cell carcinoma, or Wilms tumor. If this is arising from the renal hilus, that can be a site of origin for lipomatous tumors including liposarcoma. However, the renal vessels are patent and no bulky adenopathy is seen.

Diagnosis

Differential:

- Angiomyolipoma
- Renal Teratoma
- Liposarcoma
- Renal Cell Carcinoma
- Wilms Tumor

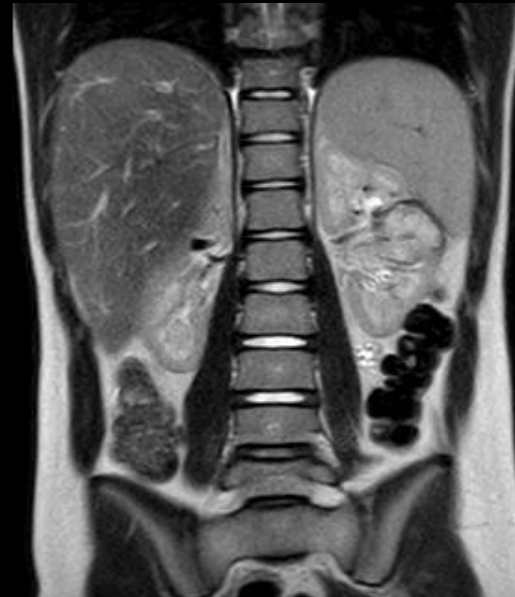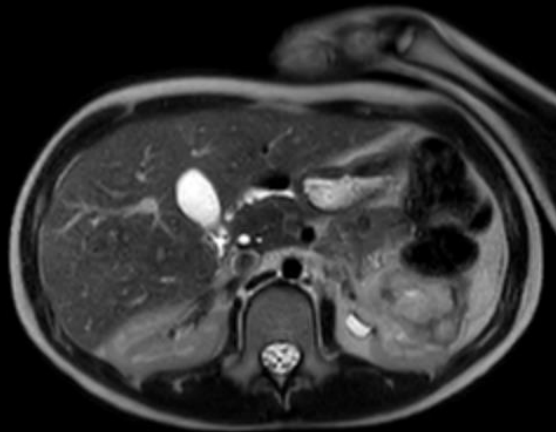
Left renal mass biopsy → Angiomyolipoma with hemorrhage and necrosis

Discussion

- Renal angiomyolipoma (AML) is a triphasic tumor composed of mature adipose tissue, smooth muscle, and vessels.
- The most reliable finding for diagnosing renal AML is the identification of intratumoral fat on unenhanced CT.
- AMLs sometimes present with atypical findings and may mimic renal cell carcinoma (RCC).
- While the majority of angiomyolipomas are sporadic and inconsequential, approximately 20% are associated with tuberous sclerosis complex.
- Although angiomyolipoma is usually benign, there is a rare, potentially malignant epithelioid angiomyolipoma

Patient Outcomes

- Patient underwent IR-guided embolization of left renal angiomyolipoma in November 2021
- After 1 week, pain and nausea had completely resolved.
- Follow-up MRI in December 2021: the lesion is largely resolved



References

- Eble J. N. (1998). Angiomyolipoma of kidney. *Seminars in diagnostic pathology*, 15(1), 21–40.
- Halpenny, D., Snow, A., McNeill, G., & Torreggiani, W. C. (2010). The radiological diagnosis and treatment of renal angiomyolipoma—current status. *Clinical radiology*, 65(2), 99-108.
- Hélénon, O., Merran, S., Paraf, F., Melki, P., Correas, J. M., Chrétien, Y., & Moreau, J. F. (1997). Unusual fat-containing tumors of the kidney: a diagnostic dilemma. *Radiographics : a review publication of the Radiological Society of North America, Inc*, 17(1), 129–144.
<https://doi.org/10.1148/radiographics.17.1.9017804>
- Umeoka, S., Koyama, T., Miki, Y., Akai, M., Tsutsui, K., & Togashi, K. (2008). Pictorial review of tuberous sclerosis in various organs. *Radiographics : a review publication of the Radiological Society of North America, Inc*, 28(7), e32.
<https://doi.org/10.1148/rg.e32>